

Primary Thalamic and Caudate Hemorrhage in Term Neonates Presenting with Seizures

Coleen Adams, MB*, Leo Hochhauser, MD[†], and William J. Logan, MD*

Two previously well term neonates who presented with seizures are described: one with thalamic hemorrhage and the other with thalamic and caudate hemorrhage. These 2 patients were the only neonates found with thalamic hemorrhage in a review of 54 term infants with intracranial hemorrhage at The Hospital for Sick Children over a 10 year period (1976 – 1986). Partial seizures occurred at 5 and 7 days after birth and were easily controlled. Prognosis was generally good in these 2 patients, as well as in 4 previously reported patients.

Adams C, Hochhauser L, Logan WJ. Primary thalamic and caudate hemorrhage in term neonates presenting with seizures. *Pediatr Neurol* 1988;4:175-7.

Introduction

Intracranial hemorrhage in term infants occurs less frequently and with a different predilection of sites in the brain than in premature infants. In the term neonate, thalamic hemorrhage without associated intraventricular hemorrhage has been described but is unusual (Table 1). All patients had neonatal seizures. We recently examined a term neonate with this problem and identified another term neonate on review of our previous patients with intracranial hemorrhage.

Case Reports

Patient 1. This term female infant, weighing 3.1 kg, was born to a gravida 3 para 2 mother after an uneventful pregnancy. During epidural anesthesia there was fetal bradycardia to 50/min for 20 min. The infant was born by vaginal vertex delivery. Apgar scores were 8 at 1 min and 9 at 5 min. She was discharged after 4 days, an apparently normal neonate. At 5 days of age she had clonic movements of the right hand which spread to the arm and right side of the face; the seizure lasted 5 min. On

that day she had been drowsy and not feeding well. On examination rectal temperature was 37.8°C. Occipitofrontal circumference was 35 cm with a flat fontanel. There was no evidence of nuchal rigidity or trauma. General examination, including blood pressure, was normal. On neurologic examination she was lethargic but responded appropriately to painful stimuli. Primitive reflexes were normal and symmetric. Pupils were equal and reactive; fundi were normal. Random conjugate eye movements were normal with full range of movement. She had no eye deviation and no nystagmus. Facial movements and gag response were intact. Tone was minimally reduced on the left side with normal truncal tone. Power and myotactic reflexes were normal and symmetric. Plantar responses were flexor. There was no clonus.

Investigations included hemoglobin 181 g/L, leukocytes $22.2 \times 10^9/L$, and platelets $216 \times 10^9/L$. The following tests were normal: prothrombin, partial prothrombin time, electrolytes, glucose, calcium, magnesium, and amino acids. Cerebrospinal fluid (CSF) contained leukocytes $30 \times 10^6/L$, erythrocytes $2,160 \times 10^6/L$, normal CSF/blood glucose ratio, and no bacterial or viral growth. Urine amino acids and organic acids were normal. Reaction for urinary reducing substances was negative. At 6 days of age cranial ultrasound demonstrated increased echoes in the left thalamus. At 9 days of age cranial computed tomography (CT) confirmed a small left thalamic hemorrhage (Fig 1). Electroencephalography (EEG) was normal. She was treated with antibiotics until the cultures were reported as negative. The seizures were treated with phenobarbital and did not recur.

Her development has been normal. At 4 months of age she was rolling over, reaching for objects, and babbling. At 6 months of age she was sitting unsupported, had a pincer grasp, and a normal neurologic examination. Antiepileptic drugs were discontinued and seizures did not recur. She walked at 14½ months of age. One month later she was helping to dress and wash herself. She also used a spoon and a cup for eating and

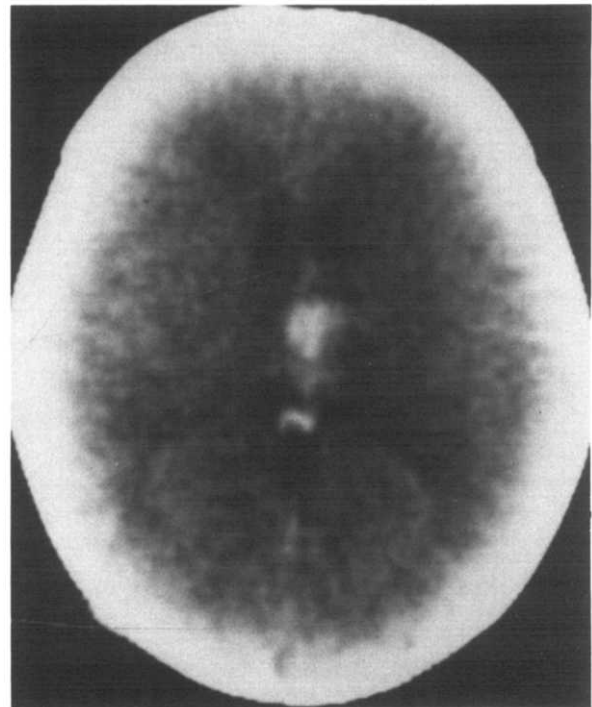


Figure 1 Cranial CT of Patient 1 demonstrating small left thalamic hemorrhage

From the Departments of *Pediatrics (Neurology) and [†]Radiology: The Hospital for Sick Children and The University of Toronto; Toronto, Canada.

Communications should be addressed to: Dr. Adams; The Hospital for Sick Children; 555 University Avenue; Toronto, Ontario M5G 1X8, Canada. Received March 18, 1988; accepted April 13, 1988.

Table 1. Spontaneous hemorrhage in term neonates in the thalamus, caudate, and putamen with no associated intraventricular hemorrhage

Authors	Birth Weight	Gestation	Apgar Scores at 1 and 5 min	Delivery	Age at Seizure Signs	Cranial CT	EEG	Outcome
Fenichel et al. [1]	3.5 kg	Term	9, 10	Vaginal vertex	2 days	Hemorrhage R putamen internal capsule	Decreased amplitude on R	L hemiparesis at 1 year
Trounce et al. [2]	—	Term	Uncomplicated	Vaginal vertex	14 days	R thalamic hemorrhage	Normal	Normal at 18 months

Levene and Trounce reported 2 term infants with thalamic hemorrhages and seizures [3].

Present Patients

Patient 1	3.1 kg	Term	8, 9	Decreased fetal HR to 50/min during epidural vaginal vertex	5 days	L thalamic hemorrhage	Normal	Very mild L hemiparesis at 15½ months
Patient 2	3.4 kg	Term	9, 9	Vaginal vertex	7 days	Bilateral caudate and R thalamic hemorrhage	Bilateral epileptic activity	Normal at 10½ months

Abbreviations:

HR = Heart rate

L = Left

R = Right

drinking. She developed right-handed dominance prematurely. She was able to understand simple commands in 2 languages and put 2 words together. On neurologic examination at 15½ months of age she had slightly increased reflexes on the left but no functional defect. Occipitofrontal circumference remained at the 50th percentile.

Patient 2. This term female infant was born by vaginal vertex delivery, weighing 3.4 kg, to a primigravida mother after an uneventful pregnancy. Apgar scores were 9 at 1 min and 9 at 5 min. She was breast fed and was discharged at 5 days of age, an apparently normal neonate. Two days later, intermittent clonic movements of the left arm and face progressed to multifocal seizures involving the arms, face, and legs. Over 24 hours the seizure activity became almost continuous. Between seizures she was lethargic and irritable. She was afebrile and had an occipitofrontal circumference of 34 cm with a flat fontanel, 3 cm in diameter. There was no evidence of trauma. General examination, including blood pressure, was normal. On neurologic examination she was lethargic but withdrew appropriately to painful stimuli. Primitive reflexes were normal. Pupils were equal and reactive; fundi were normal. Eyes deviated upward and were divergent with no visual attention. Facial movements and gag response were intact. There was no response to sound. Truncal and shoulder girdle tone was reduced. Tone was normal in the legs. Power and myotactic reflexes were normal and symmetric; the plantar responses were flexor.

Investigations included hemoglobin 163 g/L, leukocytes $11.8 \times 10^9/L$, and platelets $244 \times 10^9/L$. The following results were normal: prothrombin time, partial prothrombin time, electrolytes, glucose, calcium, magnesium, ammonia, blood gases, and amino acids. CSF examination revealed leukocytes $10 \times 10^6/L$, erythrocytes $2,025 \times 10^6/L$, no organisms on Gram stain, normal CSF/blood glucose ratio, and no bacterial or viral growth. Urine amino acids and organic acids were normal. Reaction for urinary reducing substances was negative. Serum antibodies to cytomegalovirus, herpes, rubella, and toxoplasmosis were normal. Cranial ultrasound at 9 days of age demonstrated increased echoes in the right thalamus. Cranial CT also performed that day revealed increased attenuation bilaterally over the region of the head of the caudate, more marked on the right, and also increased attenuation along the right

thalamus which represented hemorrhage (Fig 2). EEG recorded discharges involving right and left hemispheres independently. The background disclosed a burst-suppression pattern which was attenuated by diazepam administered intravenously. Seizures responded to phenobarbital and phenytoin.

Over the next few days she improved, becoming more alert with normal conjugate eye movements, better tone, and improved feeding. She continued to receive phenobarbital with only one recurrence of seizures at 6 weeks of age which responded to increased dosage of phenobarbital. Repeat cranial CT was normal at 5 weeks of age. At 4½ months of age EEG was normal. At that age, development was normal with rolling over, reaching for objects, babbling, and responsive smiling. At 7 months of age phenobarbital was discontinued and she had no further seizures. At 10½ months of age she was developing normally, speaking several words, and walking independently. Occipitofrontal circumference remained at the 50th percentile. She had no abnormalities on neurologic examination except for mild left esotropia.

Discussion

The etiology is unknown in the 2 present and 4 previously reported neonates with thalamic hemorrhage and no associated intraventricular hemorrhage (Table 1). Hypoxia or ischemia was suspected, but there is little supportive evidence. Intrapartum bradycardia occurred in Patient 1, but there was no other indication of asphyxia. Brainstem and thalamic involvement has been described in clinical human neonatal asphyxia and experimental animal asphyxia [4-7]. Hemorrhage then may occur into the area of necrosis. The absence of documented asphyxia in most of these patients, the lack of similar hemorrhage in virtually all patients with documented asphyxia, the timing of the seizures, and the lack of typical long-term sequelae of as-

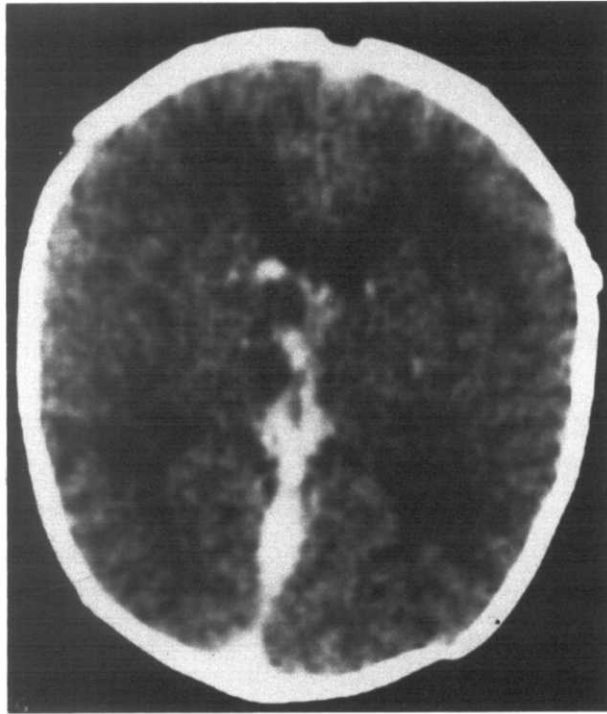


Figure 2. Cranial CT of Patient 2 revealing hemorrhage bilaterally over the region of the head of the caudate (more marked on the right) and hemorrhage along the right thalamus.

phyxia are difficult to reconcile with this suggested pathogenesis of hemorrhage.

Other possible causes may include trauma, a vascular abnormality, a coagulopathy, tumor, hypertension, an embolic

phenomenon, or a metabolic disturbance such as organic acidemia.

All patients presented with seizures within the first 2 weeks of life. In the previous patients subsequently examined until 18 months and 1 year of age (Table 1) and in our patients the prognosis appears good. The only long-term sequela has been mild hemiparesis in 2 of the 4 patients.

We recommend consideration of intracranial hemorrhage in the differential diagnosis of the previously healthy term neonate who presents with seizures.

References

- [1] Fenichel GM, Webster DL, Wong WKT. Intracranial hemorrhage in the term newborn. *Arch Neurol* 1984;41:30-4.
- [2] Trounce JQ, Fawer CL, Punt J, Dodd KL, Fielder AR, Levene MI. Primary thalamic hemorrhage in the newborn: A new clinical entity. *Lancet* 1985;1:190-2.
- [3] Levene MI, Trounce JQ. Cause of neonatal convulsions. *Arch Dis Child* 1986;61:78-9.
- [4] Leech RW, Alvord EC. Anoxic-ischemic encephalopathy in the human neonatal period. *Arch Neurol* 1977;34:109-13.
- [5] Kreusser KL, Schmidt RE, Shackelford GD, Volpe JJ. Value of ultrasound for identification of acute hemorrhagic necrosis of thalamus and basal ganglia in an asphyxiated term infant. *Ann Neurol* 1984; 16:361-3.
- [6] Kotagal S, Toce SS, Kotagal P, Archer CR. Symmetric bithalamic and striatal hemorrhage following perinatal hypoxia in a term infant. *J Comput Assist Tomogr* 1983;7:353-5.
- [7] Myers RE. Two patterns of perinatal brain damage and their conditions of occurrence. *Am J Obstet Gynecol* 1972;112:246-76.