



HAL
open science

Is the analgesic effect of motor cortex stimulation somatotopically driven or not?

Benjamin Pommier, Charles Quesada, Christophe Nuti, Roland Peyron,
François Vassal

► To cite this version:

Benjamin Pommier, Charles Quesada, Christophe Nuti, Roland Peyron, François Vassal. Is the analgesic effect of motor cortex stimulation somatotopically driven or not?. *Neurophysiologie Clinique = Clinical Neurophysiology*, 2020, 50, pp.195 - 203. 10.1016/j.neucli.2020.04.002 . hal-03492354

HAL Id: hal-03492354

<https://hal.science/hal-03492354>

Submitted on 22 Aug 2022

HAL is a multi-disciplinary open access archive for the deposit and dissemination of scientific research documents, whether they are published or not. The documents may come from teaching and research institutions in France or abroad, or from public or private research centers.

L'archive ouverte pluridisciplinaire **HAL**, est destinée au dépôt et à la diffusion de documents scientifiques de niveau recherche, publiés ou non, émanant des établissements d'enseignement et de recherche français ou étrangers, des laboratoires publics ou privés.



Distributed under a Creative Commons Attribution - NonCommercial 4.0 International License

ORIGINAL ARTICLE

Is the analgesic effect of motor cortex stimulation somatotopically driven or not?

Benjamin Pommier^{1,2,*}, Charles Quesada^{2,3}, Christophe Nuti^{1,2}, Roland Peyron^{2,4}, François Vassal^{1,2}

(1) Service de Neurochirurgie, Hôpital Nord, Centre Hospitalier Universitaire de Saint-Etienne, France

(2) Inserm U1028, UMR 5292, Central Integration of Pain Lab, Universités Jean Monnet et Claude Bernard Lyon 1, Saint-Etienne, France

(3) Service de Neurologie, Hôpital Nord, Centre Hospitalier Universitaire de Saint-Etienne, France

(4) Centre d'Evaluation et de Traitement de la Douleur, Hôpital Nord, Centre Hospitalier Universitaire de Saint-Etienne, France

Corresponding author: Benjamin Pommier, Service de Neurochirurgie, Hôpital Nord, avenue Albert Raimond, F-42270 Saint-Priest en Jarez, France. Phone (office): +33 477 127 723; Fax: +33 477 120 540. E-mail: Benjamin.Pommier@Neurochirurgie.fr

Key Words: central pain; motor cortex stimulation; neuropathic pain; repetitive transcranial magnetic stimulation; somatotopy

Running title: *Somatotopy and motor cortex stimulation*

Abstract

Objectives: Mechanisms of analgesic efficacy related to motor cortex stimulation (MCS) remain poorly understood. Specifically, it is unclear whether pain relief is somatotopically driven or not. We present three illustrative case-reports of MCS in which unintentional stimulation setting errors occurred, leading to differential (and reversible) pain relief outcomes across the hemi-body.

Methods: After successful preoperative rTMS trials, three patients suffering from post-stroke pain were selected for MCS. Stimulation was set with the aim of activating two epidural electrodes over the somatotopic representation of the lower and upper limbs. Data regarding pain relief were prospectively collected.

Results: At the first follow-up, all three patients complained of a lack of pain relief in the lower limb, contrasting with good outcome in the upper limb. In fact, for each of them we diagnosed the same stimulation setting error, to which they were “blinded”, i.e. the parasagittal electrode over the somatotopic representation of the lower limb was inadvertently turned off. Subsequently, six months after having the electrode turned on (still in a “blinded” fashion), all three patients described substantial pain relief in the lower limb, with a median improvement of 50% (range: 40–70%).

Discussion: These incidental case reports argue in favor of a genuine and at least partly somatotopically-driven analgesic efficacy of MCS. Therefore, the parasagittal electrode seems crucial when treating lower limb pain with MCS.

Introduction

Motor cortex stimulation (MCS) was developed in the early 1990's to treat refractory neuropathic pain [15, 19, 27]. Since then, more than 400 patients treated with MCS for this indication have been reported in the literature [15, 19, 27]. However, despite a handful of double-blinded controlled studies with small sample sizes [12, 20, 28], the analgesic efficacy of MCS remains debated. Another unresolved question is the mechanism of action by which MCS produces its analgesic effects [5, 9], and, more specifically, whether pain relief is somatotopically driven or not. One early study emphasized the importance of matching electrode positioning over Penfield's motor homunculus with pain territory to achieve satisfactory outcomes, but the methodology used precluded definite conclusion [19]. MCS mechanisms are not well known, but the hypotheses are not exclusively based on somatotopic neural circuitries [17, 18]. Furthermore, pain relief after repetitive transcranial magnetic stimulation (rTMS) of the motor cortex, which may share some common mechanisms of action with MCS [9, 17, 18], seems less dependent on stimulation of the cortical area corresponding to the painful territory [7, 8, 14].

Here, we report three illustrative case-reports of MCS with unintentional stimulation setting errors, leading to differential (and reversible) pain relief outcomes across the hemi-body. In each case, while the electrode aimed at stimulating the motor cortical area corresponding to the upper limb was turned on, the electrode placed over the somatotopic representation of the lower limb was inadvertently turned off in the immediate postoperative period. All of the 3 patients experienced pain relief in the upper limb, but in contrast had poor outcome in the lower limb. Turning on the non-active electrode (in a "blinded" fashion) allowed subsequent and substantial pain relief in the lower limb. These incidental observations bring arguments in favor of a genuine analgesic efficacy of MCS that may be independent from a placebo effect, and that would involve a somatotopic circuitry.

Experimental plan

In accordance with our previously published papers [24, 25], patients presenting with drug-resistant central neuropathic pain were treated with a standardized open-label therapeutic protocol in which data were prospectively collected as detailed below.

rTMS: Patients were first included in the rTMS protocol. All of them were proposed to undergo a test period of at least 4 sessions of neuronavigated robotized rTMS over the primary motor cortex. These sessions were separated by 3-4 weeks. Pain relief (main outcome) was assessed using the percentage of pain relief (%R) compared to their baseline pain level (0% no pain relief, 100% full pain relief). Other collected data are detailed below.

Classification: At the end of the test period that included 4 sessions separated by 3 weeks, patients were classified as responders ($\geq 10\%R$) or non-responders ($< 10\%R$). Only responders could continue maintenance rTMS sessions with intervals between sessions that could be adapted according to patient convenience and/or to pain relief duration. Both responders and non-responders could choose to be engaged in a surgical MCS program, even though responders were more encouraged to do so.

MCS: On their demand, as an alternative solution to maintenance rTMS sessions, patients could undergo a standardized MCS surgery, with two electrodes placed in the epidural space over the cortical representation of the painful area. Follow-up assessment was carried out at 6, and 12 months, and the MCS clinically adjusted if required. Pain relief was assessed using the same criteria as above.

Baseline patients clinical data

All three patients suffered from drug-resistant, central neuropathic pain, lasting for at least 1 year with severe intensity (Numerical Rating Scale > 6/10). A lesion was identified for each of them: patient #1 had a perisylvian ischemic stroke; patient #2 had a thalamic ischemic stroke; and patient #3 had a lateral medullary ischemic stroke (i.e. Wallenberg syndrome). Patient 1 and 2 presented unilateral pain in the whole hemibody including the face. Because of the lesion located in the lateral medulla (Wallenberg syndrome), patient 3 presented mainly hemibody pain contralateral to the lesion, and, incidentally, paroxysmal periorbital pain, ipsilateral to the lesion. He was informed that any pain relief resulting from the stimulation procedure would be expected to be restricted to the hemibody pain contralateral to stimulation (this also being the clinically more important pain). No patient presented aphasia or cognitive dysfunction that could have made assessment difficult. Clinical characteristics are detailed in table 1.

rTMS

Stimulation target (primary motor cortex contralateral to pain, hand region) was identified and marked on each patient's individual MRI (1x1x1 mm 3D-T1-weighted MRI). To this aim, trained operators located the center of the omega-shape region defined by the central (Rolando) sulcus. Then, using the neuronavigation system, the rTMS coil was centered on this target according to a postero-anterior axis. Magnetic stimulation was delivered at this target with a MagPro X100 stimulator (Magventure Tonika Elektronik, Farum, Denmark) through a figure-of-eight coil (Cool-B65-A/P, Magventure). It delivered gradually increased intensities until evoking a reproducible motor response on the contralateral hand. Then, the exact position of the target was adjusted in all four directions, in order to maximize the amplitude of the motor response and to find the motor hotspot. The

motor threshold was considered as the minimum stimulation intensity required to provoke a motor response at this point. Then, during the session, the coil was maintained in front of the target by a robotized arm (Smartmove, ANT, Enschede, Netherlands), the movements of which were coupled with the neuronavigation system and an infra-red camera (Visor2, ANT, Enschede, Netherlands). Finally, the target stereotaxic coordinates were fixed and saved to be used in the initial and subsequent sessions. Stimulation parameters were based on prior recommendations [10] and previous works [1, 3, 11, 13, 16, 22]. They consisted of 20 consecutive trains of 80 stimulations delivered at 20Hz, at 80% of motor threshold, separated by inter-train intervals of 84 seconds (i.e. a total of 1.600 stimulations during a 26-minutes session).

For each subsequent session, rTMS was delivered by a nurse blinded to stimulation parameters. She evaluated pain outcome through two main criteria. The first main criterion was %R, defined on a continuous 0-100% scale: patients were asked to evaluate the level of pain relief between 0% (no pain relief) and 100% (complete pain relief) relative to their baseline pain level before starting rTMS (before first session). The secondary main criterion was the duration of pain relief (DPR): patients were asked the number of days during which they had experienced this significant pain relief.

As explained in section 1, all patients underwent a test period and were assessed 3 weeks after the fourth session to define their status (responder or non-responder) according to their pain relief (i.e. $\geq 10\%R$ vs $< 10\%R$). These three patients were all considered as responders. Patient 3 considered after only 3 sessions that he had marked improvement and, given the fact he lived far from the hospital, he preferred to take the risk of surgery more quickly than expected. As previously proposed in rTMS [24, 26] and MCS studies [21, 25], responder patients were categorized as follows: moderate improvement ($\%R \geq 10\%$ to 39%), good improvement ($\%R \geq 40\%$ - 69%), and excellent improvement ($\%R \geq 70\%$).

Patients underwent 12.7 rTMS sessions on average (median=16, min=3, max=19). The median %R at the assessment rTMS session was 50% (min= 30%, max= 50%). The median interval between two sessions was 25 days (min=21; max=35) during the test period, and 28 days (min = 15; max = 42) for all the sessions. No patient declared major differential pain relief between upper and lower limbs, but at this stage of the treatment no specific topographic pain relief was assessed. Detailed data are presented in Figure 2 and in the Supplementary material.

MCS implantation surgery and programming

The MCS surgical procedure has been previously reported in detail elsewhere [21]. Two electrodes with 4 stimulating contacts (Resume, Medtronic, Minneapolis, MN, USA) were placed over the dura through a frontoparietal craniotomy under generalized anesthesia. The central sulcus was localized, based on an anatomical (3D-MRI neuronavigation; Kolibri, BrainLab, Feldkirchen, Germany) and physiological mapping (somatosensory evoked potentials). Somatosensory evoked potentials were used with the phase reversal technique. The aim was to locate the N20P20 reversion, in order to accurately locate the central sulcus. No motor evoked potentials were used perioperatively. The electrodes were implanted to cover the whole hemibody motor representation. A first electrode (parasagittal medial electrode, PMel) was oriented anterior-posteriorly, parallel to the parasagittal line, and covering the lower limb motor representation. The three anterior contacts were situated anterior to the central sulcus, and the posterior contact behind the central sulcus. A second electrode (precentral lateral electrode, PLel) was oriented superior-inferiorly along the main axis of the primary motor cortex. The inferior contact was located over the face motor area and the medial over the motor area of the hand (Figure 1). The electrodes were connected to a

dual-channel stimulator (PrimeAdvanced, Medtronic, Minneapolis, MN, USA) subcutaneously implanted in the subclavicular region during the same operative stage.

Stimulation was started on the postoperative day. Two contacts per electrode were systematically activated, one cathode and one anode (Figure 1). The cathodes were the anterior contact on the PMel, and the lateral contact on the precentral lateral electrode whereas the anodes were respectively the posterior and the medial. Initial settings are detailed in table 2. A junior resident, relatively inexperienced in functional neurosurgery, applied these initial settings. All three patients were operated during a relatively short (three month) period of time. In these 3 consecutive patients, he accidentally omitted to turn on the PMel. Initial settings are detailed in table 2. According to our standard protocol, an appointment was scheduled with the referring neurologist (RP) 3 to 6 months later, to optimize the analgesic effects. Because of the exceptionally short timescale in which these patients had been implanted, the setting errors were not noticed before the 6 months' postoperative visit of the first patient. During this visit, the referring neurologist (RP) observed the mistake. Thereby, he activated the PMel, and just told the patients that he had changed the settings of the stimulation. After that, all the recently implanted patients were checked to ensure that there were no other mistakes. No other patient suffered from programming errors.

Assessment of MCS effects

Postoperative %R after MCS was assessed separately for the face, upper limb, and lower limb. Assessment was systematically made at least at 6 months after surgery, and then every 6 months.

Initial assessment (one activated electrode)

At the first postoperative follow-up (6 months, M6) all the patients reported a differential pain relief across the hemibody, characterized by an improvement in the face and

upper limb but a lack of pain relief in the lower limb: Patient #1 presented an excellent improvement in the face and a good improvement in the upper limb. Patient #2 presented a moderate improvement for the face and the upper limb. Patient #3 presented a good improvement in the ipsilateral face and a moderate improvement in the upper limb. The median %R in the face was 60% (min=10, max= 70), the median %R in the upper limb was 40% (min= 25%, max= 60%), and the median %R on the lower limb was 0% (min= 0%, max= 0%). As previously explained, Patient #3 also had facial pain ipsilateral to the lesion. The patient considered it as much less painful than pain on the contralateral body. The patient was informed that MCS was being performed with the expectation of pain relief on the contralateral hemibody, but that it should logically not influence this facial pain ipsilateral to the lesion. Consequently, this ipsilateral facial pain was treated independently from MCS. Since it was a paroxysmal pain (unlike the contralateral hemibody pain), a trial was performed with diazepam (initiated during rTMS sessions). Thus, this treatment did not interfere with the results of pain relief that exclusively concerned the contralateral hemibody pain.

Late assessment (both electrodes activated)

At the next follow-up visit (12 months) all 3 patients benefited from the modified settings. The median %R in the face was 50% (min= 25%, max= 70%), the median %R in the upper limb was 60% (min= 10%, max= 70%), and the median %R in the lower limb was 50% (min= 40%, max= 70%). No significant change was observed in face and upper limb.

According to our pre-established protocol, we systematically asked the patients at 18 months if, assuming a similar level of MCS efficacy, they would agree to undergo surgery again (Yes/No); and which treatment modality they preferred between multiple rTMS sessions and MCS (three conditions: equality, rTMS, MCS).

All three patients would undergo the surgery again, and found the analgesic effect provided by MCS superior to the one provided by rTMS.

Discussion

The real analgesic efficacy and mechanism of action of MCS remain under discussion, contributing to the limited diffusion of this neuromodulation treatment for refractory neuropathic pain. Although randomized, double-blind, controlled trials are still mandatory to confirm the real analgesic efficacy of MCS, the incidental observations reported here bring some arguments in favor of a genuine, and at least partly somatotopically driven, neurophysiologic action of MCS.

All three patients suffered from hemibody pain, treated with epidural electrodes implanted over the motor cortex to apply electrical stimulation. They were instructed that they would receive two electrodes, each one aiming at relieving pain in the upper or lower part of the body, respectively. Thus, they expected to have pain relief over the whole hemibody. This expectation was reinforced by their prior experience with multiple preoperative rTMS sessions after which they obtained a significant analgesic effect on the whole hemibody. In any case, they considered this analgesic effect strong enough to decide them for MCS. Given the unintentional stimulation setting error, the therapy was only delivered through one electrode in a “double-blind” fashion. The first postoperative assessment by the neurologist was blinded to the condition, since he was not aware of the accidental electrode shutdown. All three patients spontaneously complained about an incomplete pain relief restricted to the upper part of the body, unlike the rTMS effect they were used to. They described (in a blinded fashion) an analgesic effect that was conflicting with both their expectations and a placebo response, which should have concerned the whole hemibody. Subsequently, the second electrode (PMel) implanted over the lower limb motor representation was switched on. It

allowed satisfactory pain relief to be restored as the three patients reported a significant improvement of the lower limb pain relief, without significant changes to face and upper limb.

The relationship between stimulation site and pain site regarding the analgesic efficacy of MCS has been extensively discussed, with some early findings suggesting that pain relief depends on accurate somatotopic positioning of the electrodes [19]. The underlying mechanisms remain only partially known. The results of positron emission tomography (TEP) studies have shown large-scale network effects within the pain matrix, based on different neuromodulators including opioids [5, 23]. They also seem to be based on distant areas activation and long-term potentiation (LTP) mechanisms [17, 18]. Yet, widespread network effects and secretion of endogenous opioid are not necessarily antagonistic with a somatotopically-driven analgesic effect. One recent study in rats showed that MCS induces a selective anti-nociception effect restricted to the limb related to the stimulated motor cortical area, which is mediated, at least in part, by the activation of descendent inhibitory pain pathway, including the periaqueductal gray and the opioid system [4]. Such data seem consistent with our findings and could reconcile different hypotheses about the mechanisms of action of MCS.

Despite the fact that rTMS and MCS share some common mechanisms [9, 17, 18], there seem to be some differences in their somatotopic effect. The magnetic field produced by rTMS remains not very well-known [29]. Nevertheless, targeting the hand motor hot spot probably provided a widespread relief in our three patients. In the case of MCS, it appeared mandatory to cover a large area with both of the electrodes to replicate similar outcomes. These differences between rTMS and MCS in terms of somatotopic organization of the analgesic effects are difficult to understand, as the extent of current density spreading over the cortex are impossible to compare. Explanations are not clear, and we can consider rTMS as a

less spatially selective neuromodulation therapy than MCS, likely to encompass motor cortical areas adjacent to the targeted ones. Once again, mechanisms of pain relief of motor cortex stimulation are probably multiple. There is some evidence that in some cases, the analgesic effect of rTMS can be focal and somatotopic but heterotopic to the targeted area [14]. In other cases, it can be diffuse (even sometimes bilateral)[16]. There remain also some confounding factors such as the difficulty to reach other cortical target than the hand motor hot spot, which could partially explain some data in favor of the superiority of the hand motor hot spot as a unique target [2]. Concerning MCS in our 3 patients, mainly somatotopic and homotopic effects seem to have occurred. This does not rule out that there may also be diffuse effects in other patients, or at least widespread effects extending largely beneath the cortical region covered by the electrode.

On the other hand, the difference of relief between one and two activated electrodes is possibly due to the interactions between both of these electrodes, linked to the same generator. The activation of the second electrode could have created other electric fields between negative and positive poles of the electrodes, contributing to the increase of surface of the stimulated cortex. As suggested by Holsheimer & al. [6], a preferable situation corresponds to a cathodal (-) stimulation anterior to the central sulcus and anodal (+) stimulation posterior to the central sulcus. In our case, the PLel was positioned along the central sulcus with both of the activated contacts in front of it. The secondly activated electrode (PMel) was set with the cathodal (-) contact in front of it and the anodal (+) behind.

Finally, from a surgical technical point of view, and to maximize the results, our three observations argue in favor of the use of a parasagittal electrode for patients suffering from hemibody pain, to be sure to include the lower limb.

Conflict of interest statement

The authors declare that there is no conflict of interest regarding the publication of this article.

References

1. André-Obadia N, Magnin M, Garcia-Larrea L. On the importance of placebo timing in rTMS studies for pain relief. *Pain* 2011; 152:1233–7.
2. Andre-Obadia N, Magnin M, Simon E, Garcia-Larrea L. Somatotopic effects of rTMS in neuropathic pain? A comparison between stimulation over hand and face motor areas. *Eur J Pain* 2018;22:707-15.
3. Andre-Obadia N, Mertens P, Gueguen A, Peyron R, Garcia-Larrea L Pain relief by rTMS Differential effect of current flow but no specific action on pain subtypes. *Neurology* 2008;71:833–40.
4. França NRM, Toniolo EF, Franciosi AC, Alves AS, de Andrade DC, Fonoff ET, et al. Antinociception induced by motor cortex stimulation: Somatotopy of behavioral response and profile of neuronal activation. *Behav Brain Res* 2013;250:211–21.
5. Garcia-Larrea L, Peyron R. Motor cortex stimulation for neuropathic pain: From phenomenology to mechanisms. *NeuroImage* 2007;37:S71–9.
6. Holsheimer J, Nguyen J-P, Lefaucheur J-P, Manola L. Cathodal, anodal or bifocal stimulation of the motor cortex in the management of chronic pain? *Acta Neurochir Suppl* 2007;97:57–66.
7. Jetté F, Côté I, Meziane HB, Mercier C. Effect of Single-Session Repetitive Transcranial Magnetic Stimulation Applied Over the Hand Versus Leg Motor Area on Pain After Spinal Cord Injury. *Neurorehabil Neural Repair* 2013;27:636–43.
8. Kang BS, Shin HI, Bang MS. Effect of Repetitive Transcranial Magnetic Stimulation Over the Hand Motor Cortical Area on Central Pain After Spinal Cord Injury. *Arch Phys Med Rehabil* 2009;90:1766–71.
9. Lefaucheur J-P. Cortical neurostimulation for neuropathic pain: state of the art and perspectives. *Pain* 2016;157:S81–9.

10. Lefaucheur J-P, André-Obadia N, Antal A, Ayache SS, Baeken C, Benninger DH, et al. Evidence-based guidelines on the therapeutic use of repetitive transcranial magnetic stimulation (rTMS). *Clin Neurophysiol* 2014;125:2150–206.
11. Lefaucheur J-P, André-Obadia N, Poulet E, Devanne H, Haffen E, Londero A, et al. Recommandations françaises sur l'utilisation de la stimulation magnétique transcrânienne répétitive (rTMS): règles de sécurité et indications thérapeutiques. *Neurophysiol Clin* 2011;41:221–95.
12. Lefaucheur J-P, Drouot X, Cunin P, Bruckert R, Lepetit H, Creange A, et al. Motor cortex stimulation for the treatment of refractory peripheral neuropathic pain. *Brain* 2009;132:1463–71.
13. Lefaucheur J-P, Drouot X, Keravel Y, Nguyen J-P. Pain relief induced by repetitive transcranial magnetic stimulation of precentral cortex. *Neuroreport* 2001;12:2963–5.
14. Lefaucheur JP, Hatem S, Nineb A, Ménard-Lefaucheur I, Wendling S, Keravel Y, et al. Somatotopic organization of the analgesic effects of motor cortex rTMS in neuropathic pain. *Neurology* 2006;67:1998–2004.
15. Mertens P, Nuti C, Sindou M, Guenot M, Peyron R, Garcia-Larrea L, et al. Precentral cortex stimulation for the treatment of central neuropathic pain: results of a prospective study in a 20-patient series. *Stereotact Funct Neurosurg* 1999;73:122–5.
16. Mhalla A, Baudic S, de Andrade DC, Gautron M, Perrot S, Teixeira MJ, et al. Long-term maintenance of the analgesic effects of transcranial magnetic stimulation in fibromyalgia. *Pain* 2011;152:1478–85.
17. Moisset X, de Andrade DC, Bouhassira D. From pulses to pain relief: an update on the mechanisms of rTMS-induced analgesic effects. *Eur J Pain* 2016;20:689-700.
18. Moisset X, Lefaucheur J-P. Non pharmacological treatment for neuropathic pain: Invasive and non-invasive cortical stimulation. *Rev Neurol (Paris)* 2019;175:51–8.
19. Nguyen J-P, Lefaucheur J-P, Decq P, Uchiyama T, Carpentier A, Fontaine D, et al. Chronic motor cortex stimulation in the treatment of central and neuropathic pain. Correlations between clinical, electrophysiological and anatomical data. *Pain* 1999;82:245–51.
20. Nguyen J-P, Velasco F, Brugières P, Velasco M, Keravel Y, Boleaga B, et al. Treatment of chronic neuropathic pain by motor cortex stimulation: Results of a bicentric controlled crossover trial.

Brain Stimul 2008;1:89–96.

21. Nuti C, Peyron R, Garcia-Larrea L, Brunon J, Laurent B, Sindou M, et al. Motor cortex stimulation for refractory neuropathic pain: Four year outcome and predictors of efficacy. *Pain* 2005;118:43–52.
22. Passard A, Attal N, Benadhira R, Brasseur L, Saba G, Sichere P, et al. Effects of unilateral repetitive transcranial magnetic stimulation of the motor cortex on chronic widespread pain in fibromyalgia. *Brain* 2007;130:2661–70.
23. Peyron R, Faillenot I, Mertens P, Laurent B, Garcia-Larrea L. Motor cortex stimulation in neuropathic pain. Correlations between analgesic effect and hemodynamic changes in the brain. A PET study. *NeuroImage* 2007;34:310–21.
24. Pommier B, Créac'h C, Beauvieux V, Nuti C, Vassal F, Peyron R. Robot-guided neuronavigated rTMS as an alternative therapy for central (neuropathic) pain: Clinical experience and long-term follow-up. *Eur J Pain* 2016;20:907–16.
25. Pommier B, Quesada C, Fauchon C, Nuti C, Vassal F, Peyron R. Added value of multiple versus single sessions of repetitive transcranial magnetic stimulation in predicting motor cortex stimulation efficacy for refractory neuropathic pain. *J Neurosurg* 2018; in press.
26. Quesada C, Pommier B, Fauchon C, Bradley C, Créac'h C, Vassal F, et al. Robot-guided neuronavigated repetitive transcranial magnetic stimulation (rTMS) in central neuropathic pain. *Arch Phys Med Rehabil* 2018;99:2203-15.
27. Tsubokawa T, Katayama Y, Yamamoto T, Hirayama T, Koyama S. Chronic motor cortex stimulation for the treatment of central pain. *Acta Neurochir Suppl (Wien)* 1991;52:137–9.
28. Velasco F, Carrillo-Ruiz JD, Castro G, Argüelles C, Velasco AL, Kassian A, et al. Motor cortex electrical stimulation applied to patients with complex regional pain syndrome: *Pain* 2009;147:91–8.
29. Wagner T, Rushmore J, Eden U, Valero-Cabre A. Biophysical foundations underlying TMS: Setting the stage for an effective use of neurostimulation in the cognitive neurosciences. *Cortex* 2009;45:1025–34.

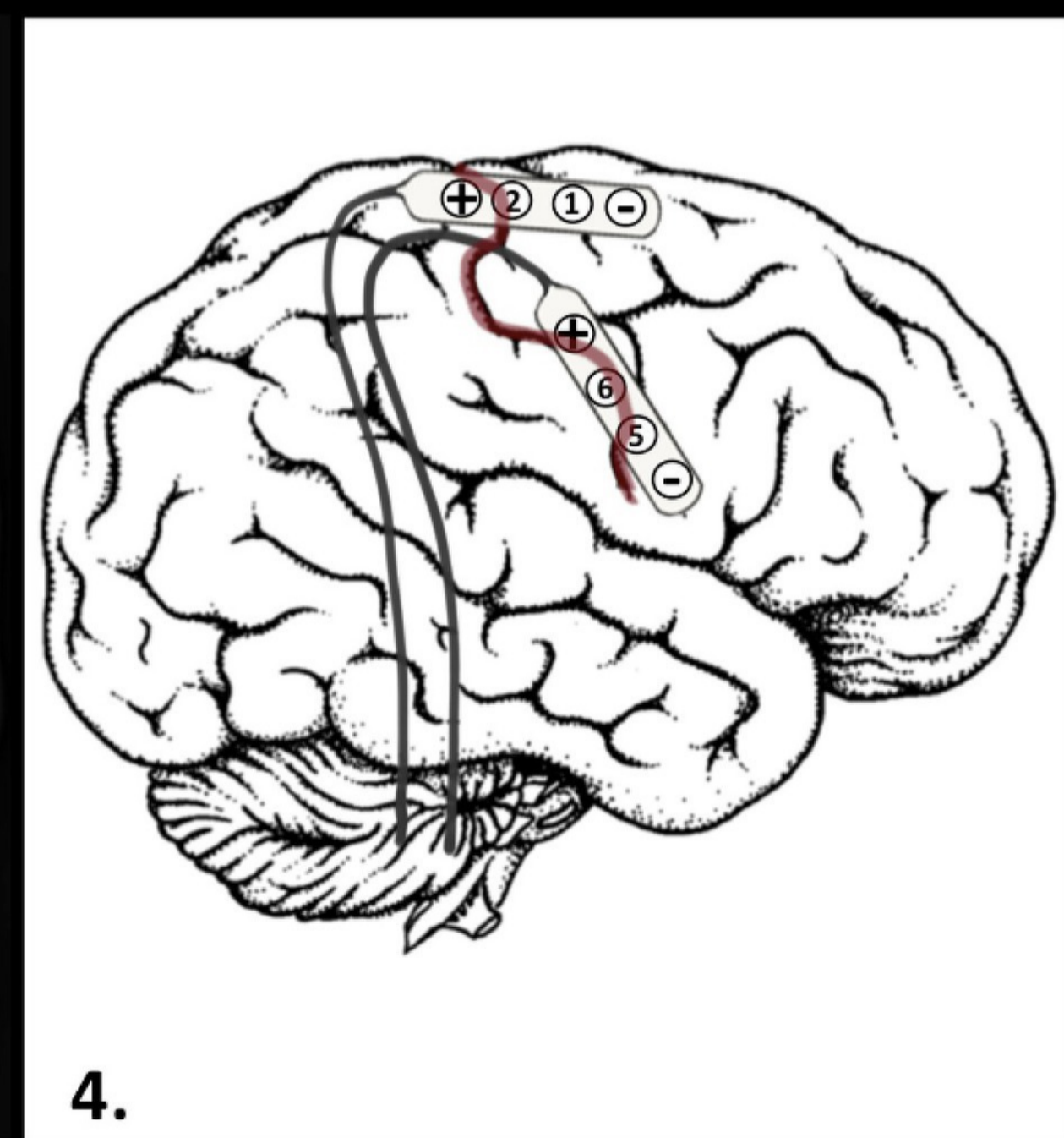
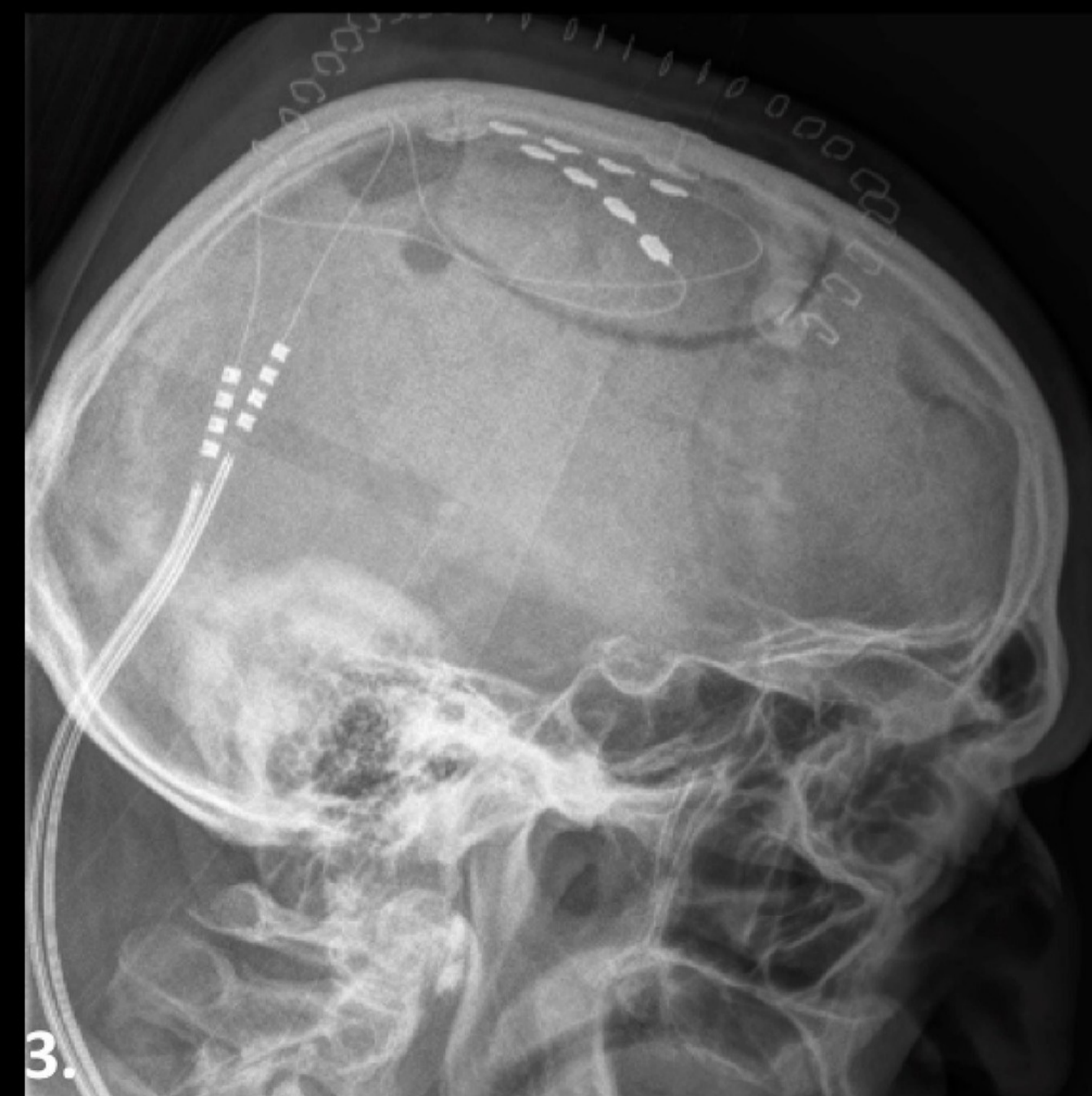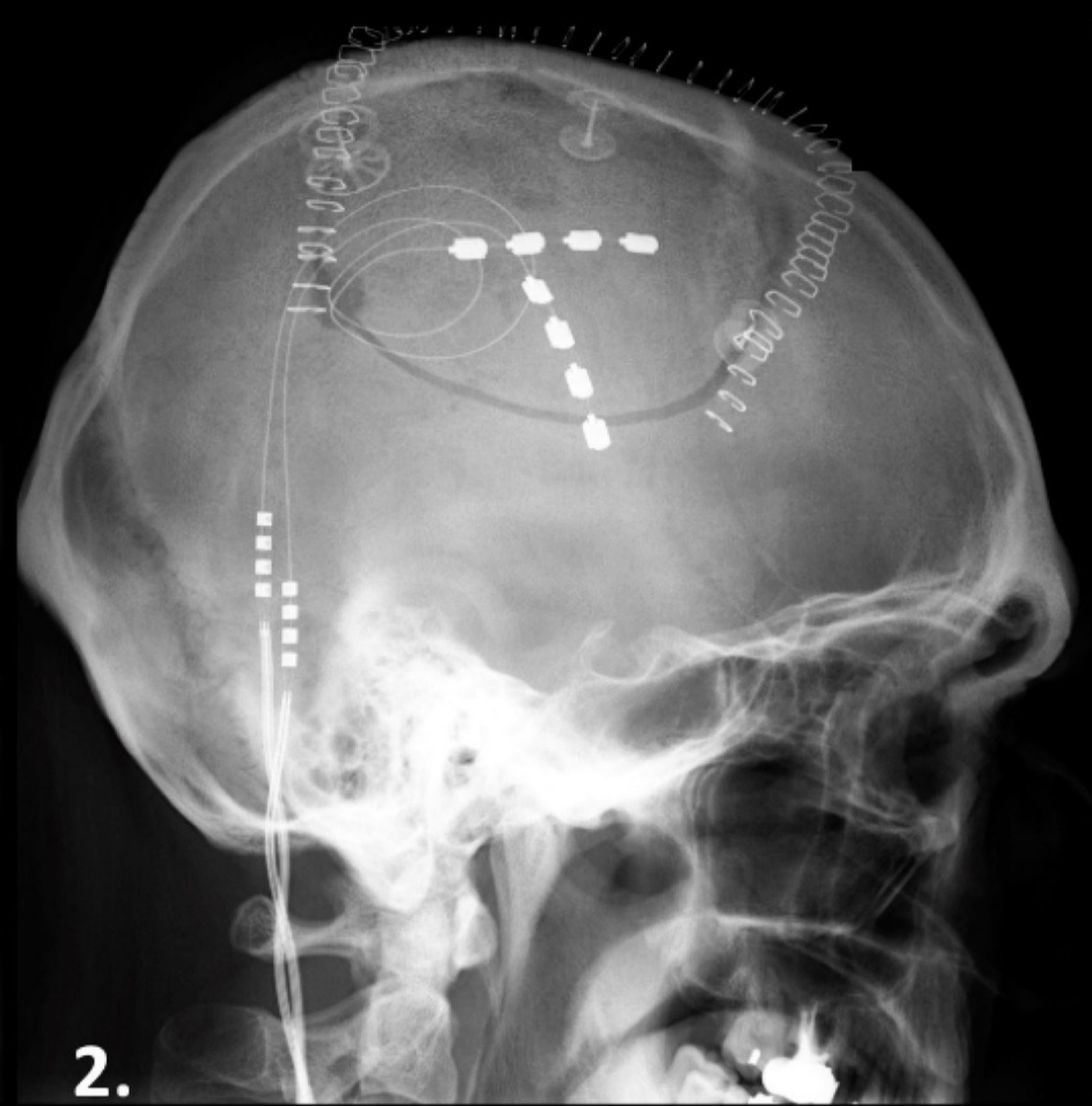
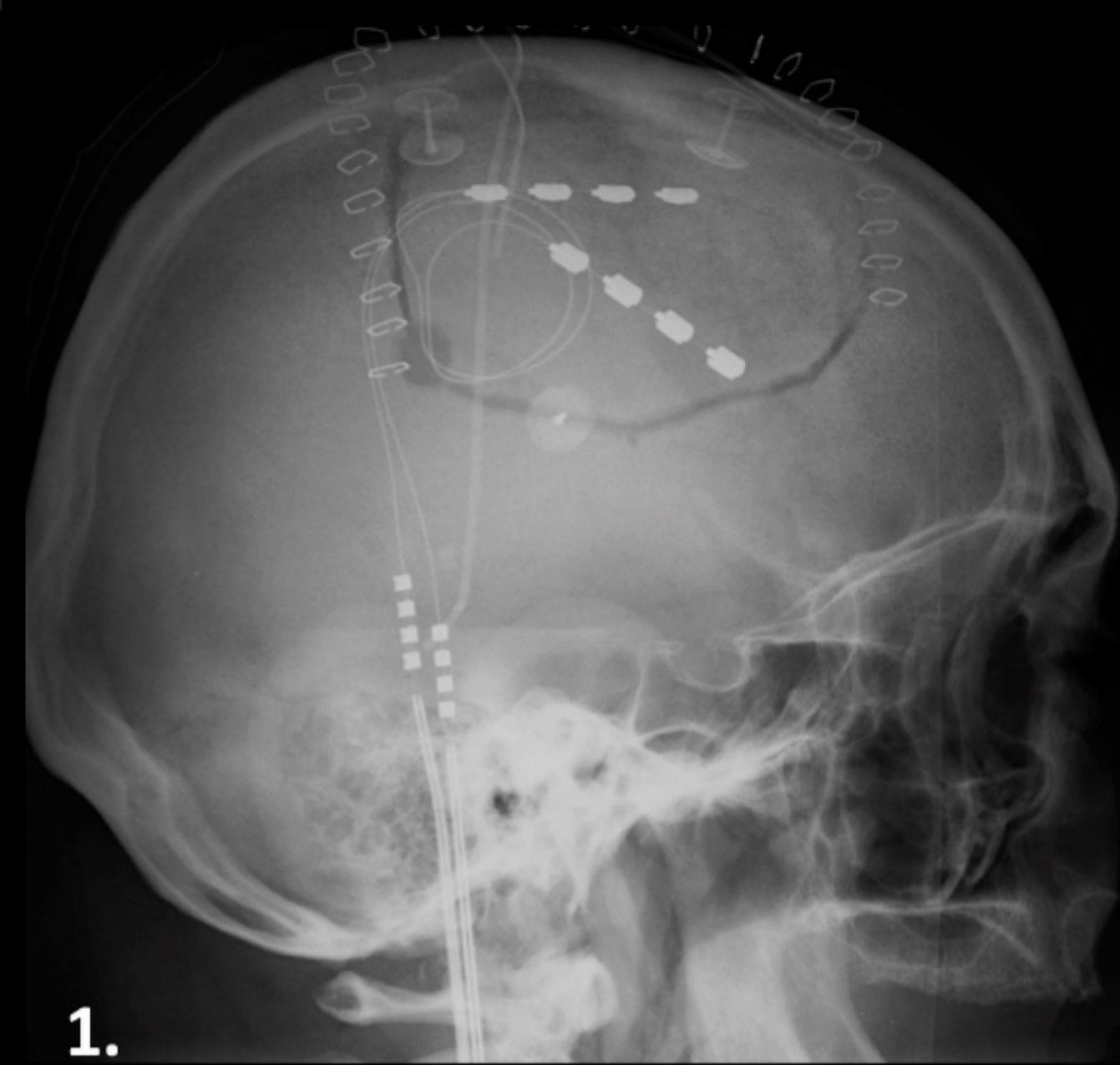
Figure Legends

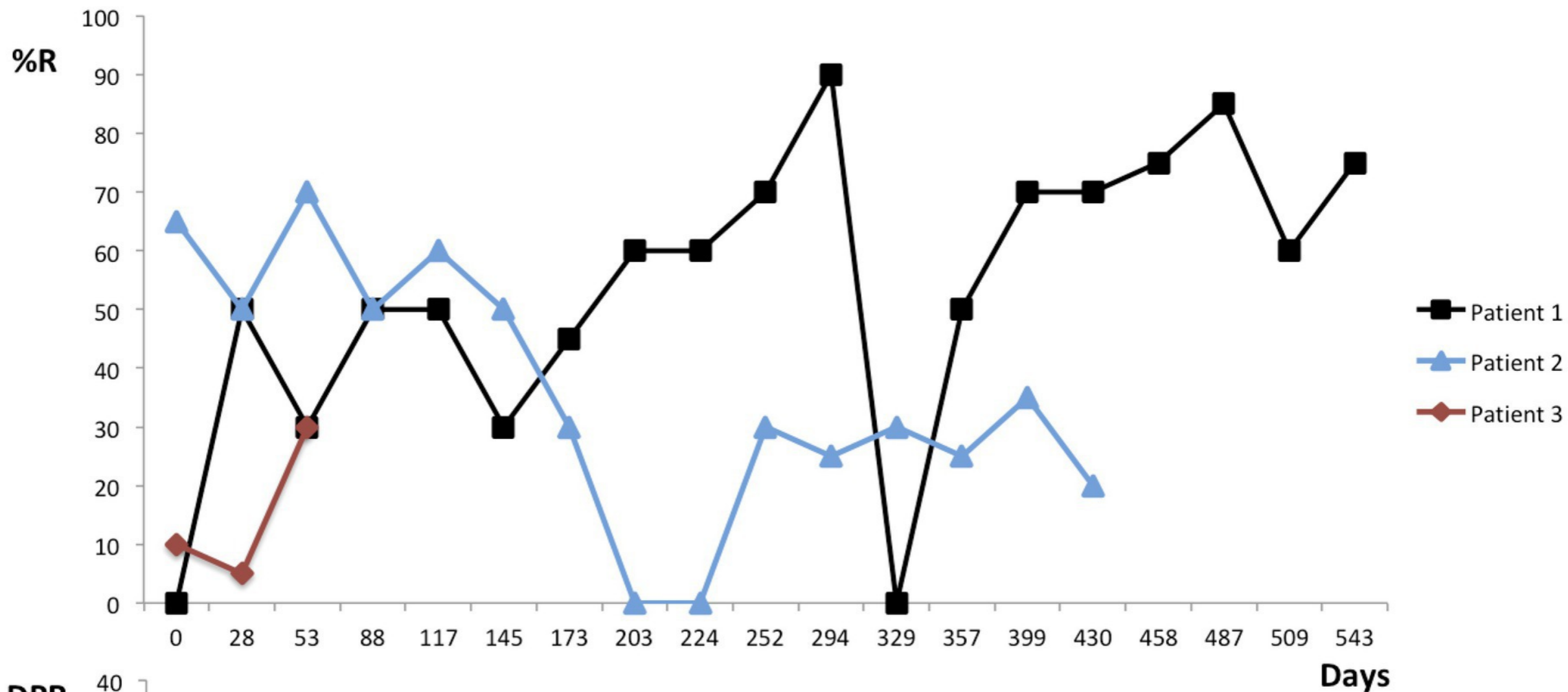
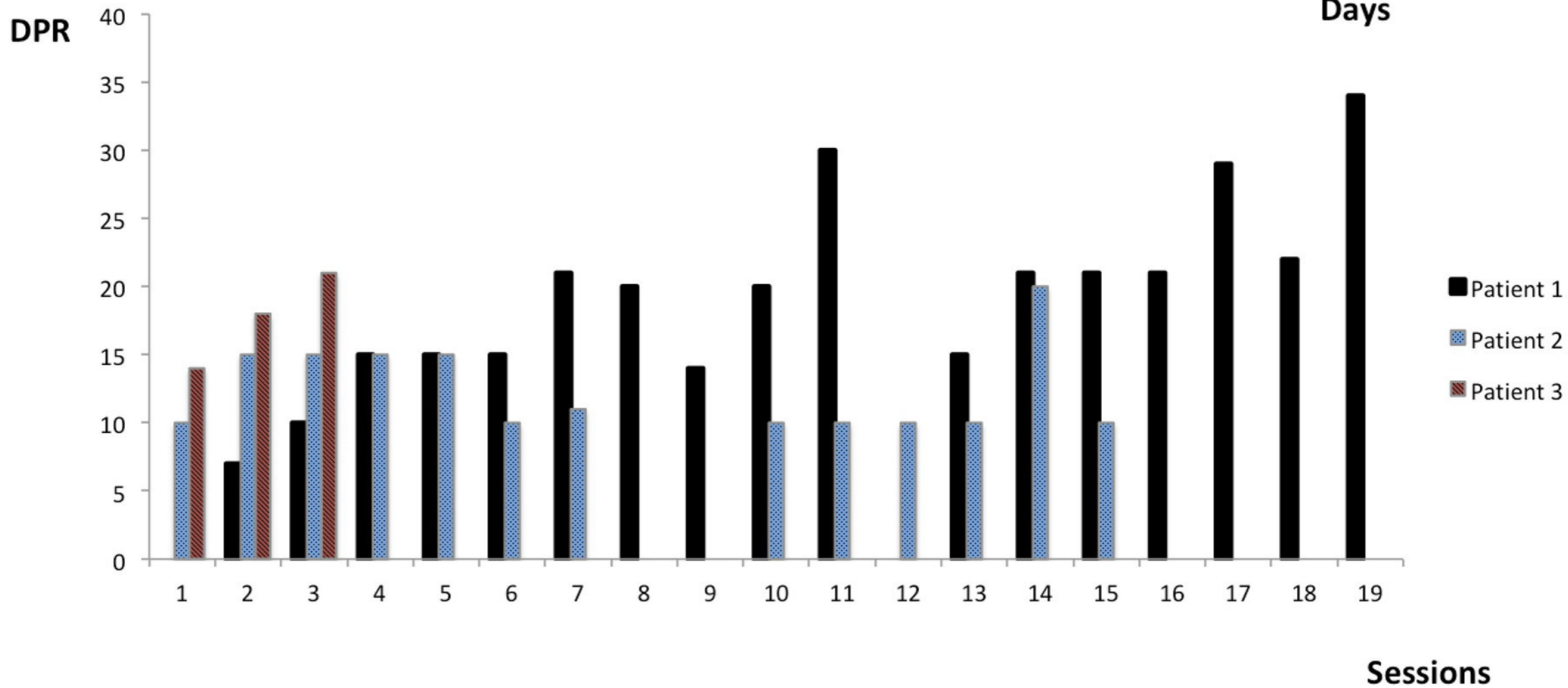
Figure 1: MCS electrodes positioning.

1-3. Postoperative X-rays of each patient (1 to 3) 4. Diagram showing the positioning of electrodes and the polarity we used according to the central sulcus (Red). The parasagittal medial electrode (PMel) is oriented anterior-posteriorly, parallel to the parasagittal line, and covering the lower limb motor representation with the three anterior contacts situated in front of the central sulcus, and the posterior contact behind. The cathode is the anterior contact and the anode the posterior one. The precentral lateral electrode (PLel) is oriented superior-inferiorly along the main axis of the primary motor cortex. The inferior contact (cathode) is located over the face motor area and the medial (anode) over the hand motor area. Both of these contacts are situated anteriorly to the central sulcus.

Figure 2: Pain relief evolution among rTMS sessions.

A. Percentage of pain relief (%R) according to time (days) after the beginning of rTMS sessions. B. Duration of pain relief (DPR) in days, according to the number of rTMS sessions. The follow-up during rTMS phase was 543 days for patient 1, 312 days for patient 2 and 58 days for patient 3.



A.**B.**

N	Age	Sex	Stroke lesion	Pain duration - rTMS	Pain duration - MCS	Pain location	Pain intensity (NRS)		Pain descriptors				Sensory status	Motor status	Cognitive status	SEPs	LEPs	Baseline analgesic medication	
							rTMS	MCS	Spont.	Parox.	Th. Allod.	Mech Allod.						rTMS	MCS
1	54	M	Sylvian ischemic stroke	3	5	Contralateral Hemiface and Hemibody	5	9	Y	N	N	Y	Lower Limb Thermoalgic Hypoesthesia	Slight motor deficit in the lower limb (MRC 4/5)	Normal	Cortical amplitude reduction	Hemibody deafferentation	Duloxetine, Gabapentine	Duloxetine, Paracetamol, Tramadol
2	44	M	Thalamic ischemic stroke	2	3	Contralateral Hemiface and Hemibody	7	10	Y	N	Y	Y	Hemibody complete hypoesthesia	Normal	Normal	Normal	Slight desynchronization	Pregabaline, Amitriptyline, Paracetamol, Tramadol	Pregabaline, Amitriptyline, Paracetamol, Tramadol
3	68	M	Lateral medulla ischemic stroke (Wallenberg)	5	7	Ipsilateral Hemiface and Contralateral Hemibody	6	8	Y	Y	Y	Y	Hemibody thermoalgic hypoesthesia	Normal	Normal	Normal	Cortical amplitude reduction	Gabapentine, Paracetamol, Tramadol	Gabapentine, Tramadol, Transdermal idocaïne, Diazepam

Table 1: Main clinical characteristics: **Stroke lesion** : Stroke lesion at the origin of pain ; **Pain duration –rTMS, -MCS**: Pain duration in years to rTMS therapy initiation and to MCS implantation; **Pain intensity (NRS)**: Pain intensity (Numerical Rating Scale (0-10)) at baseline before rTMS initiation and MCS implantation; **Pain descriptors** : **Spont.** = Spontaneous pain; **Parox.** = Paroxysmal pain; **Th. Allod.** = Thermal allodynia; **Mech. Allod.** = Mechanical Allodynia; **SEPs**: Somatosensory evoked potentials; **LEPs**: Laser evoked potentials; **Baseline analgesic medication** before **rTMS** initiation and **MCS** implantation.

Patient	M3	M6	M12	M18
1 Face		70	70	70
Upper Limb		60	60	60
Lower Limb		0	40	40
<i>Settings</i>		1V 30HZ 120us	1,5V 30 Hz 180us	2V 30Hz 210us
<i>Electrode configuration</i>		PLel : 0+ / 3- ; PMel: NA	PLel: 0+ / 3- ; PMel: 4+ / 7-	PLel: 0+ / 3- ; PMel: 4+ / 7-
<i>Cyclic mode</i>		60 min. ON 120 min. OFF	60 min. ON 120 min. OFF	60 min. ON 120 min. OFF
2 Face		10	25	20
Upper Limb		25	10	40
Lower Limb		0	50	70
<i>Settings change</i>		0,5V 30Hz 180us	1V 35Hz 180us	1,5V 35Hz 210us
<i>Electrode configuration</i>		PLel: 0+ / 3- ; PMel: NA	PLel: 0+ / 3- ; PMel: 4+ / 7-	PLel: 0+ / 3- ; PMel: 4+ / 7-
<i>Cyclic mode</i>		60 min. ON 120 min. OFF	60 min. ON 120 min. OFF	60 min. ON 120 min. OFF
3 Face	60	60	50	50
Upper Limb	20	50	70	50
Lower Limb	0	40	70	50
<i>Settings change</i>	1,5V 30Hz 180us	1,5V 30Hz 180us	2V 30Hz 180us	2,5V 35Hz 180us
<i>Electrode configuration</i>	PLel: 0+ / 3- ; PMel: NA	PLel: 0+ / 3- ; PMel: 4+ / 7-	PLel: 0+ / 3- ; PMel: 4+ / 7-	PLel: 0+ / 3- ; PMel : 4+ / 7-
<i>Cyclic mode</i>	30 min. ON 30 min. OFF	30 min. ON 30 min. OFF	30 min. ON 30 min. OFF	60 min. ON 120 min. OFF

Table 2: %R of each body region, at each follow-up after MCS implantation. *Settings* correspond to the stimulation settings before assessment. Electrode configuration corresponds to the electrode polarity before assessment of *PLel*= Precentral Lateral electrode and *PMel*: Parasagittal Medial electrode.