


# Journal Pre-proof

Genetically confirmed CARASIL: A case report with a novel HTRA1 mutation and literature review

Zhaoping Yu, MD, Shugang Cao, MD, Aimei Wu, MD, Hong Yue, MD, Chi Zhang, MD, Juan Wang, MD, Mingwu Xia, MD, Juncang Wu, MD



PII: S1878-8750(20)31099-8

DOI: <https://doi.org/10.1016/j.wneu.2020.05.128>

Reference: WNEU 15064

To appear in: *World Neurosurgery*

Received Date: 17 March 2020

Revised Date: 12 May 2020

Accepted Date: 13 May 2020

Please cite this article as: Yu Z, Cao S, Wu A, Yue H, Zhang C, Wang J, Xia M, Wu J, Genetically confirmed CARASIL: A case report with a novel HTRA1 mutation and literature review, *World Neurosurgery* (2020), doi: <https://doi.org/10.1016/j.wneu.2020.05.128>.

This is a PDF file of an article that has undergone enhancements after acceptance, such as the addition of a cover page and metadata, and formatting for readability, but it is not yet the definitive version of record. This version will undergo additional copyediting, typesetting and review before it is published in its final form, but we are providing this version to give early visibility of the article. Please note that, during the production process, errors may be discovered which could affect the content, and all legal disclaimers that apply to the journal pertain.

© 2020 Published by Elsevier Inc.

**Genetically confirmed CARASIL: A case report with a novel HTRA1 mutation and literature review**

<sup>+</sup>Zhaoping Yu, MD; <sup>+</sup>Shugang Cao, MD; Aimei Wu, MD; Hong Yue, MD; Chi Zhang, MD; Juan Wang, MD; Mingwu Xia, MD; \*Juncang Wu, MD.

Department of Neurology

The Affiliated Hefei Hospital of Anhui Medical University

Hefei, Anhui 230011 P.R. China

<sup>+</sup>: Zhaoping Yu and Shugang Cao contributed equally to this work

**Corresponding Author:**

Juncang Wu, MD

Intersection of Guangde Road and Leshui Road

Hefei, Anhui 230011, P.R.

Email: wujuncang126@126.com

Phone: +86 551 13956076148

Fax: +86 551 13956076148

# Genetically confirmed CARASIL: A case report with a novel HTRA1 mutation and literature review

## ABSTRACT

**Background.** Cerebral autosomal recessive arteriopathy with subcortical infarcts and leukoencephalopathy (CARASIL) is an extremely rare monogenic autosomal disease associated with the HtrA serine protease 1 (HTRA 1) gene mutation. Recently, a few genetically confirmed CARASIL cases with novel HTRA 1 mutations have been reported in countries other than Japan.

**Case description.** Here, we report a case of a patient presenting with worsening right hemiplegia and hemiparesthesia. Physical examination revealed that the patient had typical clinical features of CARASIL, including thinning hair, cognitive impairment, emotional changes, lumbago, and gait disorder, among others. Brain magnetic resonance imaging (MRI) showed abnormal diffuse symmetrical changes in white matter and hypertensive diffusion-weighted imaging (DWI) signals in the left centrum ovale and right splenium of the corpus callosum, and susceptibility-weighted imaging (SWI) showed multiple cerebral microbleeds. Lumbar MRI showed herniated discs with degenerative changes. A genetic test showed a novel homozygous nucleotide variation of c.847G>T in the HTRA1 gene, thereby resulting in p.Gly283Ter. Thus, the patient met the diagnostic criteria for CARASIL. We provide a literature review of genetically confirmed CARASIL cases reported to date.

**Conclusion.** CARASIL is a rare autosomal recessive disease with an HTRA1 mutation. Familiarity with the early clinical and imaging features of CARASIL combined with a genetic test is key for its early diagnosis.

**[Key words]** CARASIL; HTRA1; Cognitive impairment; Alopecia; Lumbago; Magnetic resonance imaging.

## BACKGROUND

Cerebral autosomal recessive arteriopathy with subcortical infarcts and

leukoencephalopathy (CARASIL) is an extremely rare monogenic autosomal disease characterized by nonhypertensive cerebral small vessel disease (SVD), adult early-onset subcortical infarcts, progressive motor and cognitive impairments, hair loss, and spondylopathy.<sup>1-22</sup> In 1965, the first potential CARASIL case was reported in Japan. During the subsequent 45 years, most CARASIL cases were also reported in Japan. In 2009, Hara et al<sup>2</sup> first identified the HtrA serine protease 1 (HTRA 1) gene as a causative gene of CARASIL. In recent years, a few genetically confirmed CARASIL cases have been reported in China, Europe, America, and India.<sup>6-22</sup> In this paper, we report a case of CARASIL with a novel HTRA1 mutation with detailed data on the disease evolution, diagnosis, and treatment and perform a literature review of genetically confirmed CARASIL cases.

## CASE

A 28-year-old man was admitted to our hospital on August 08, 2018, due to numbness and weakness of the right upper and lower limbs for 3 years, which had intensified during the previous 5 months. The patient's medical history before admission is as follows. On September 11, 2014, the patient was first admitted to our hospital for dizziness, nausea, and vomiting. Brain magnetic resonance imaging (MRI) showed multiple demyelinating lesions involving bilateral centrum ovale, periventricular corona radiata, basal ganglia region, temporal lobe, and brainstem, and cranio-cervical computed tomography angiography (CTA) showed a slender right vertebral artery. Electroencephalography was normal. The patient improved rapidly after symptomatic treatment. On November 18, 2015, the patient was readmitted to our hospital for sudden weakness of the right upper and lower limbs with hemianesthesia. Brain MRI suggested progression of the multiple inflammatory lesions in the brain, and diffusion-weighted imaging (DWI) showed hypertensive signals adjacent to the posterior and inferior horns of the left lateral ventricle. Routine and biochemical examinations of cerebrospinal fluid (CSF) were normal. Serum and CSF oligoclonal bands and anti-aquaporin-4 antibody (AQP4-Ab) were both negative. Cerebral angiography also showed a slender right vertebral artery. The patient was diagnosed

with acute cerebral infarction and improved after antiplatelet therapy, statin treatment, and symptomatic therapy. However, the muscle strength of the right upper and lower limbs did not return to normal. The patient was given aspirin and statins for secondary prevention at discharge. In 2016, the patient visited several hospitals across China. He was then diagnosed with multiple sclerosis (MS) and began to take prednisone 10 mg qd and azathioprine 50 mg bid. Over the next 2 years, the patient began to have memory loss with personality changes and spoke very little. In January 2018, the numbness and weakness of the right upper and lower limbs worsened, and the patient exhibited irritability, generalized hyperhidrosis, and sleep disorders. He did not respond to symptomatic treatment, and his condition progressed to stiffness of the right upper and lower limbs and difficulty walking. In April 2018, he began to have recurrent low back pain, significant cognitive impairment, loss of independence, depression, anxiety, and sleeplessness. The patient started losing hair when he turned 20 years old and was nearly bald within 2 years. His parents were close relatives (maternal cousins), and he had 1 child. His parents and his younger sister were healthy, but his father and uncle were also bald.

Physical examination showed that the patient was conscious with a slow response, thinning hair (especially at the top of the head) (Figure 1), uncontrollable outbursts of crying and laughing, normal orientation, significant impairments in mental calculation, memory, and attention, a hemiplegic gait, high muscle tension (muscle strength: Medical Research Council (MRC) scale, grade IV) in the right upper and lower limbs, right hemiparesthesia, tendon hyperreflexia in the right upper and lower limbs, a positive bilateral palmomental reflex, and a bilateral positive Babinski sign. His Mini-Mental State Examination (MMSE) score was 17, and his Montreal Cognitive Assessment (MoCA) score was 10. Brain MRI showed abnormal diffuse symmetrical changes in white matter and hypertensive DWI signals in the left centrum ovale and right splenium of the corpus callosum, and susceptibility-weighted imaging (SWI) showed multiple cerebral microbleeds (Figure 2). The CSF test was still normal. Serum and CSF oligoclonal bands and APQ4-Ab remained negative. Cervical MRI showed bulging discs at C3/4, C4/5, and C5/6, and lumbar MRI showed herniated discs with

degenerative changes at T12/L1, L1/2, L2/3, L3/4, and L4/5 (Figure 3). A genetic test showed a homozygous nucleotide variation, c.847G>T (nucleotide G to T at position 847 of the coding region), in the HTRA1 gene, which causes p.Gly283Ter (codon 283 for amino acid Gly was changed to a stop codon), thereby resulting in a nonsense mutation that prematurely terminates peptide synthesis and affects protein function. His parents and son have a heterozygous HTRA1 mutation (c.847G>T). The genetic profile of the family is provided in Figure 1. The Notch receptor 3 (NOTCH3) gene was normal. The patient met the diagnostic criteria for CARASIL proposed by Fukutake.<sup>3</sup> The Ylikoski scale<sup>23</sup> was used to rate white matter lesions on brain MRI in 2014, 2015, and 2018, resulting in scores of 27, 32, and 46, respectively.

After admission, prednisone and azathioprine were discontinued. The patient received aspirin as antiplatelet therapy and symptomatic therapy to improve the brain circulation. No significant improvement was observed in muscle strength during hospitalization. Since discharge, the patient has been taking aspirin and has been followed up for more than 1 year. At present, he is bedridden, has limb rigidity and severe dementia, and suffers from pneumonia.

## DISCUSSION

CARASIL is a rare autosomal recessive disease. In 2009, Hara [2] first explored the possible molecular mechanism of CARASIL. The HTRA1 gene is located at the 2.4-Mb region on chromosome 10q. HTRA1 mutations reduce the protease activity of HTRA1 and thereby can not inhibit the signal transduction of the transforming growth factor- $\beta$  (TGF- $\beta$ ) family, which is closely associated with angiogenesis and remodeling. TGF- $\beta$  overexpression promotes extracellular matrix formation and accumulation and vascular fibrosis. The pathological changes observed in CARASIL are similar to those observed in arteriolar sclerosis, including apparent thinning of the outer membranes of cerebral arterioles, reductions in the extracellular matrix of parietal cells, severe hyalinization of the medial membranes of cerebral arterioles, substantial loss of smooth muscle cells, intimal fibrosis and thickening, and thickening and fracture of the internal elastic lamina with concentric stenosis of the lumen. Moreover, significant pale myelin

sheaths appear in the white matter area, and U-shaped subcortical fibers are preserved.<sup>24</sup> The novel homozygous nucleotide variation of c.847G>T in the HTRA1 gene of this patient is not documented in any available literature.

The Japanese researcher Fukutake<sup>3</sup> summarized previous cases of CARASIL and noted that CARASIL should be considered if the following signs are present: (1) early-onset leukoencephalopathy with pyramidal and extrapyramidal symptoms and widespread cerebral white matter lesions on radiologic images; (2) alopecia in adolescence; (3) early-onset recurrent lumbago or degenerative changes and disc lesions in the spine; and (4) a family history showing autosomal recessive features. Highly suspected CARASIL cases should be confirmed with HTRA1 genetic testing. This patient met the diagnostic criteria for CARASIL. The Ylikoski score showed that the patient's white matter lesions gradually expanded and worsened, with signs of cerebral atrophy, such as expansion of the ventricular system and widening of cerebral sulci and fissures. The patient also had CARASIL-specific early white matter lesions in the temporal pole (also known as the O'Sullivan sign), which is consistent with the MRI features of 3 cases reported by Li et al.<sup>21</sup> Moreover, the patient presented CARASIL-specific MRI findings in the advanced stage, including bilateral linear lesions in the external capsule and the arc sign of the cerebellopontine peduncle.<sup>25</sup> Although not observed on MRI in 2014, these characteristic findings for CARASIL were evident in 2018. We surmise that these specific MRI findings gradually appear as white matter lesions progress and cerebral atrophy worsens (Figure 3).

A literature review shows that to date, a total of 37 genetically confirmed CARASIL cases from 27 families (20 of which involve marriage between close relatives) have been reported.<sup>2,4-22</sup> A total of 22 HTRA1 mutations (note: c.496C>T may be homozygous or heterozygous and is counted only once) have been detected, including 20 homozygous mutations, 2 compound heterozygous mutations, and 1 heterozygous mutation. The patient described in this report harbored a novel mutation in the HTRA1 gene. A summary analysis revealed that the cases involved 17 male patients and 20 female patients, the age at diagnosis was 24 to 50 years (mean age,  $33.4 \pm 7.3$  years), 86% of the patients had hair loss, with an onset age of 0 to 34 years

(mean age,  $19.4 \pm 9.8$  years), 81% had recurrent lumbago, with an onset age of 14 to 39 years (mean age,  $26.6 \pm 6.3$  years), 89% had an abnormal gait, with an onset age of 22 to 45 years (mean age,  $30.0 \pm 5.9$  years), 38% began having mood changes at approximately 30 years of age, 73% had cognitive impairment, with an onset age of 24 to 50 years (mean age,  $32.7 \pm 7.1$  years), and the age at diagnosis of white matter lesions was 24 to 45 years (mean age,  $31.3 \pm 5.3$  years). These data suggest that most CARASIL patients began to experience neurological symptoms at approximately 30 years of age, hair loss at 19 years of age (mean), and lumbago at approximately 26 years of age (7 years later than hair loss). Other clinical manifestations included epilepsy, migraine, dizziness, degenerative knee arthritis, cerebral hemorrhage, hearing loss, and skull asymmetry, among others (**Table 1**). A recent study reported that the pathogenic effect of a single HTRA1 heterozygous mutation is limited to the central nervous system, which is distinct from typical CARASIL because strokes and cognitive decline usually occur in the late stage without extraneurological symptoms such as spondylopathy and hair loss.<sup>26</sup>

On radiologic images, CARASIL must be distinguished from other vascular and nonvascular encephalopathies with diffuse lesions in white matter, such as cerebral autosomal dominant arteriopathy with subcortical infarcts and leukoencephalopathy (CADASIL). CADASIL shares highly similar clinical manifestations with CARASIL, but in CADASIL, stroke usually occurs later (mean age: 45 years old) than in CARASIL, and migraine with aura occurs 10 years before stroke. Among the 37 CARASIL patients, only 5 had headache, and 3 had typical migraines, generally without early baldness or recurrent low back pain.<sup>8,12,15,17,18</sup> CADASIL is an autosomal dominant disease associated with Notch3 mutations. Moreover, CARASIL must be distinguished from other genetic diseases such as hereditary endotheliopathy with retinopathy, nephropathy, and stroke (HERNS), hereditary angiopathy with nephropathy, aneurysms, and muscle cramps (HANAC), Fabry disease, and familial cerebral amyloid angiopathy.<sup>27-28</sup> Furthermore, CARASIL must be distinguished from other central nervous system demyelinating diseases such as MS. The patient described here was once misdiagnosed with MS due to an insufficient understanding of



CARASIL and was not diagnosed with CARASIL until 4 years later. CARASIL and MS have many similarities with respect to disease course and MRI findings, and sometimes, it is difficult to distinguish between these 2 conditions. However, CARASIL-associated SVD may be associated with cerebral microbleed,<sup>14,18,21</sup> which is rare in MS.<sup>29</sup> In addition, laboratory tests did not support the diagnosis of demyelinating diseases such as MS.

No targeted treatment is currently available for CARASIL. Similar to common SVD, antiplatelet therapy is the main treatment for CARASIL. Recently, Ziaei et al<sup>20</sup> reported a family of 3 sisters with an HTRA1 homozygous mutation (c.805insG). All these patients presented typical symptoms of CARASIL, with myelitis and recurrent chronic nonseasonal rhinitis, weakness in the lower limbs, and hypertensive signals on T2-weighted imaging (T2WI) of the spinal cord, and they all responded to corticosteroid (methylprednisolone) therapy. This finding raises the question of whether immune or inflammatory factors are involved in white matter lesions. Studies have shown that TGF- $\beta$  has a good immunomodulatory effect,<sup>30</sup> and existing evidence indicates that an inflammatory response is involved in the occurrence of cerebral SVD.<sup>31</sup> The patient described in this report received prednisone and azathioprine from 2016 to 2018, but his clinical symptoms continued to worsen. Because available data on the correlation between the HTRA1 genotype and phenotype are very limited, further research is needed in this area. Most CARASIL patients die within 10 years after the onset of neurological symptoms, but some patients survive for more than 20 years.<sup>32</sup> Although the patient described here was treated with aspirin, his condition continued to deteriorate, and the overall prognosis may be very poor.

## CONCLUSION

CARASIL is an exceedingly rare hereditary cerebrovascular disease, and the HTRA1 gene is the causative gene. However, differences exist in the mutation sites of the HTRA1 gene, and a novel mutation of c.847G>T (p.Gly283Ter) in the HTRA1 gene has been reported here. Familiarity with the early clinical and imaging features of CARASIL combined with gene detection is helpful for its early diagnosis. Although no

specific treatment is currently available, functional analyses and research on pathogenic gene mutation sites may engender hope for therapy.

## References

1. Yanagawa S, Ito N, Arima K, Ikeda S. Cerebral autosomal recessive arteriopathy with subcortical infarcts and leukoencephalopathy. *Neurology*. 2002;58:817–820.
2. Hara K, Shiga A, Fukutake T, et al. Association of HTRA1 mutations and familial ischemic cerebral small-vessel disease. *N Engl J Med*. 2009;360:1729–1739.
3. Fukutake T. Cerebral Autosomal Recessive Arteriopathy with Subcortical Infarcts and Leukoencephalopathy (CARASIL): From Discovery to Gene Identification. *J Stroke Cerebrovasc Dis*. 2011; 20(2):85-93.
4. Ito S, Takao M, Fukutake T, et al. Histopathologic analysis of cerebral autosomal recessive arteriopathy with subcortical infarcts and leukoencephalopathy (CARASIL): A report of a new genetically confirmed case and comparison to 2 previous Cases. *J Neuropathol Exp Neurol*. 2016;75:1020–1030.
5. Nishimoto Y, Shibata M, Nihonmatsu M, et al. A novel mutation in the HTRA1 gene causes CARASIL without alopecia. *Neurology*. 2011;76:1353–1355.
6. Mendioroz M, Fernández-Cadenas I, Del Río-Espinola A, et al. A missense HTRA1 mutation expands CARASIL syndrome to the Caucasian population. *Neurology*. 2010;75:2033–2035.
7. Wang XL, Li CF, Guo HW, Cao BZ. A novel mutation in the HTRA1 gene identified in Chinese CARASIL pedigree. *CNS Neurosci Ther*. 2012;18:867–869.
8. Li WR, Zhao DH, Wang CX, Hong DJ, Zhang W, Yuan Y. Novel mutation of HTRA1 gene causes cerebral autosomal recessive arteriopathy with subcortical infarcts and leukoencephalopathy: A case. *Chin J Neurol*. 2012;45:566-569.
9. Chen Y, He Z, Meng S, Li L, Yang H, Zhang XT. A novel mutation of the high-temperature requirement A serine peptidase 1 (HTRA1) gene in a Chinese family with cerebral autosomal recessive arteriopathy with subcortical infarcts and leukoencephalopathy (CARASIL). *J Int Med Res*. 2013;41:1445–1455.
10. Bianchi S, Di Palma C, Gallus GN, et al. Two novel HTRA1 mutations in a

- European CARASIL patient. *Neurology*. 2014;82:898–900.
11. Bayrakli F, Balaban H, Gurelik M, et al. Mutation in the HTRA1 gene in a patient with degenerated spine as a component of CARASIL syndrome. *Turk Neurosurg*. 2014;24:67–69.
  12. Khaleeli Z, Jaunmuktane Z, Beaufort N, et al. A novel HTRA1 exon 2 mutation causes loss of protease activity in a Pakistani CARASIL patient. *J Neurol*. 2015;262:1369–1372.
  13. Menezes Cordeiro I, Nzwalo H, Sá F, et al. Shifting the CARASIL paradigm: report of a non-Asian family and literature review. *Stroke*. 2015;46:1110–1112.
  14. Cai B, Zeng J, Lin Y, et al. A frameshift mutation in HTRA1 expands CARASIL syndrome and peripheral small arterial disease to the Chinese population. *Neurol Sci*. 2015;36:1387–1391.
  15. Preethish-Kumar V, Nozaki H, Tiwari S, et al. CARASIL families from India with 3 novel null mutations in the HTRA1 gene. *Neurology*. 2017;89:2392-2394.
  16. Ibrahim M, Nozaki H, Lee A, et al. A CARASIL patient from Americas with novel mutation and atypical features: Case presentation and literature review. *Cerebrovasc Dis*. 2017;44:135-140.
  17. Bougea A, Velonakis G, Spantideas N, et al. The first Greek case of heterozygous cerebral autosomal recessive arteriopathy with subcortical infarcts and leukoencephalopathy: An atypical clinico-radiological presentation. *Neuroradiol J*. 2017;30:583-585.
  18. Xie F, Zhang LS. A Chinese CARASIL patient caused by novel compound heterozygous mutations in HTRA1. *J Stroke Cerebrovasc Dis*. 2018;27:2840-2842.
  19. Liu N, li J, Chen JJ. Cerebral autosomal recessive arteriopathy with subcortical infarcts and leukoencephalopathy: a case report and literature review. *J Apoplexy Nerv Dis*. 2018, 35:80-82.
  20. Ziaei A, Xu XH, Dehghani L, et al. Novel mutation in HTRA1 in a family with diffuse white matter lesions and inflammatory features. *Neurol Genet*. 2019;5:e345.

21. Li WX, Liu Y, Guo XY, et al. A family of cerebral autosomal recessive arteriopathy with subcortical infarcts and leukoencephalopathy. *Chin J Neurol.* 2019;52:823-830.
22. Gündüz T, Demirkol Y, Doğan Ö, Demir S, Akçakaya NH. A case of leukoencephalopathy and small vessels disease caused by a novel HTRA1 homozygous mutation. *J Stroke Cerebrovasc Dis.* 2019;28:104354.
23. Ylikoski R, Ylikoski A, Erkinjuntti T, Sulkava R, Raininko R, Tilvis R. White matter changes in healthy elderly persons correlate with attention and speed of mental processing. *Arch Neurol.* 1993;50:818–824.
24. Oide T, Nakayama H, Yanagawa S, Ito N, Ikeda S, Arima K. Extensive loss of arterial medial smooth muscle cells and mural extracellular matrix in cerebral autosomal recessive arteriopathy with subcortical infarcts and leukoencephalopathy (CARASIL). *Neuropathology.* 2008;28:132–142.
25. Nozaki H, Sekine Y, Fukutake T, et al. Characteristic features and progression of abnormalities on MRI for CARASIL. *Neurology.* 2015;85:459-463.
26. Favaretto S, Margoni M, Salviati L, Pianese L, Manara R, Baracchini C. A new Italian family with HTRA1 mutation associated with autosomal-dominant variant of CARASIL: Are we pointing towards a disease spectrum?. *J Neurol Sci.* 2019;396:108–111.
27. Tikka S, Baumann M, Siitonen M, et al. CADASIL and CARASIL. *Brain Pathol.* 2014;24:525–544.
28. Chabriat H, Joutel A, Dichgans M, Tournier-Lasserre E, Bousser MG. Cadasil. *Lancet Neurol.* 2009;8:643–653.
29. Aliaga ES, Barkhof F. MRI mimics of multiple sclerosis. *Handb Clin Neurol.* 2014;122:291–316.
30. Li MO, Wan YY, Sanjabi S, Robertson AK, Flavell RA. Transforming growth factor-beta regulation of immune responses. *Annu Rev Immunol.* 2006;24:99–146.
31. Ao DH, Zhu YC. Research progress in inflammatory response and pathogenesis of cerebral small vessels disease. *Chin J Neuroimmunol Neurol.* 2019;26:318-320.
32. Yang RM, Li B. Cerebral autosomal recessive arteriopathy with subcortical

infarcts and leukoencephalopathy. *Chin Clin Neurosci.* 2011;19:192-195.

Journal Pre-proof

**Figure legends**

**Figure 1** A genetic test showed a homozygous nucleotide variation of c.847G>T in the HTRA1 gene. From left to right are the genetic test results of the patient's father (A) and mother (B), the patient (C), and his son (D), respectively. The pedigree chart of this family with CARASIL is displayed, with the black arrow indicating the patient (E). The picture shows thinning hair in the proband of the patient (F).

**Figure 2.** The first line shows the evolution of paraventricular white matter lesions on axial T<sub>2</sub>/fluid-attenuated inversion recovery (FLAIR) images in 2014, 2015, and 2018. The second line shows the evolution of white matter lesions in the temporal poles (also known as the O'Sullivan sign, white arrow) in 2014, 2015, and 2018. The third line shows hypertensive DWI signals in the left centrum ovale and right splenium of the corpus callosum (A-B) and multiple cerebral microbleeds on SWI (C).

**Figure 3.** The second column shows that on T2WI, CARASIL-specific MRI findings were evident in 2018, including bilateral linear lesions in the external capsule and the arc sign of cerebellopontine peduncle, but not in 2014 (in the first column). Cervical MRI shows bulging discs at C3/4, C4/5, and C5/6, and lumbar MRI shows herniated discs with degenerative changes at T12/L1, L1/2, L2/3, L3/4, and L4/5 (in the third column).

**Table 1** Clinical characteristics of 37 cases of CARASIL confirmed by gene detection from 2009 to 2019

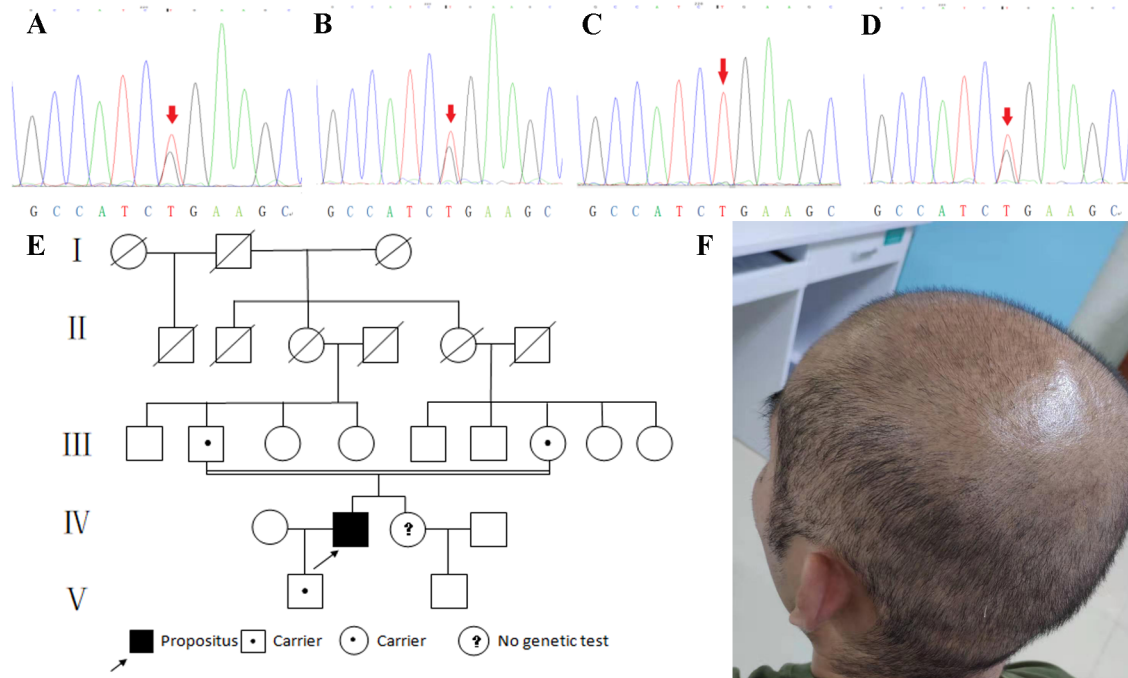
Author, Year	Sex	Age	Country	Consanguineous parents	Other patient	HARA1 (Protein)	Age of clinical symptom onset					Cognitive impairment	Special symptoms
							Alopecia	Lumbago	Leukoencephalopathy	Gait disorder	Emotional change		
Hara et al, 2009 <sup>2</sup>	M	28	Japan	Yes	2 brothers	c.904C>T (p.R302X)	16	21	28	26	NR	37	vertigo
Ito et al, 2016 <sup>4</sup>	F	46	Japan	Yes	1 sister	c.904C>T (p.R302X)	14	29	31	32	29	29	epilepsy
	F	50	Japan	Yes	2 sisters	c.889G>A (p.V297M)	16	39	+	31	NR	50	/
	M	33	Japan	Yes	1 brother	c.889G>A (p.V297M)	14	33	+	29	NR	33	/
	F	48	Japan	Yes	1 sister	c.754G>A (p.A252T)	No	Teens	40	38	+	NR	no alopecia, speech difficulties
	F	44	Japan	Yes	No	c.1108C>T (p.R370X)	18	21	+	35	NR	35	/
Mendioroz et al, 2010 <sup>6</sup>	M	43	Spain	No	No	c.883G>A (p.G295R)	18	NR	34	34	34	35	cervical canal stenosis
Nishimoto et al, 2011 <sup>5</sup>	F	44	Japan	Yes	1 brother	c.821G>A (p.R274Q)	No	20s	39	44	NR	44	no alopecia
	M	39					No	38	38	38	NR	44	no alopecia
Wang et al, 2012 <sup>7</sup>	F	27	China	Yes	1 brother	c.1091T>C (p.L364P)	27	25	27	26	NR	26	/
	M	25					+	20	25	25	NR	25	/
Li et al, 2012 <sup>8</sup>	F	34	China	Yes	No	c.524T>A (p.V175E)	31	29	34	34	34	No	severe headache, spasmodic pain

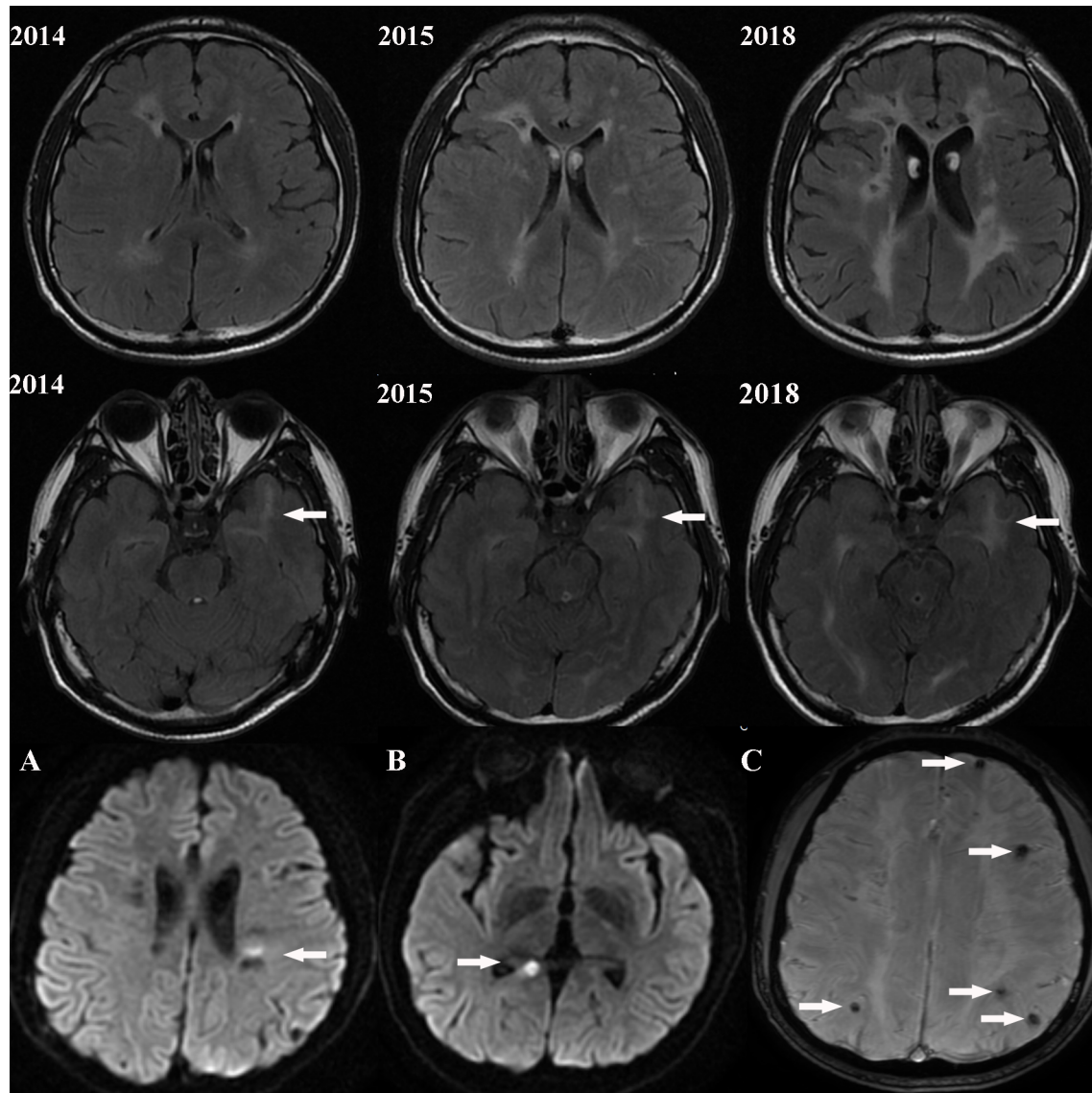
Chen et al, 2013 <sup>9</sup>	F	26	China	Yes	1 brother	c.854C>T (p.P285L)	0	23	26	23	24	24	lethargic, absence of hunger
	M	29					0	24	29	24	NR	29	/
Bianchi et al, 2014 <sup>10</sup>	F	29	Romani a	No	No	c.961G>A/c.126delG (p.A321T/p.E42fs)	No	14	29	24	NR	No	no alopecia
Bayrakli et al, 2014 <sup>11</sup>	F	29	Turkey	Yes	No	c.1108C>T (p.R370X)	+	27	29	27	NR	NR	/
Khaleeli et al, 2015 <sup>12</sup>	F	35	Pakistan	Yes	No	c.517G>A (p.A173T)	+	NR	35	33	35	35	headache
Menezes-Cordeiro et al, 2015 <sup>13</sup>	M	45	Portugal	No	1 sister	c.496C>T (p.R166C) homozygous	Teens	33	45	45	33	45	/
	F	32					32	NR	32	32	32	NR	cerebellar hemorrhage
Cai et al, 2015 <sup>14</sup>	M	28	China	Yes	1 brother	c.161_162insAG (p.G56Afs*160)	18	28	28	28	NR	NR	cerebral microbleed
	M	29					29	29	29	30	NR	NR	/
Preethish-Kumar et al, 2017 <sup>15</sup>	M	26	India	Yes	No	c.739delG (p.E247Rfs)	23	NR	26	25	25	25	papular facial rash, broad-based rigido-spastic gait
	M	24	India	No	1 brother	c.830_831delAG (p.E277Vfs)	22	NR	24	24	NR	NR	postural tremor
	M	24					22	NR	24	22	NR	24	status epilepticus
	F	33	India	Yes	No	c.502A>T (p.K168ter)	0	24	33	33	NR	33	migraine-like headaches
Ibrahimi et al, 2017 <sup>16</sup>	M	24	Puerto Rico	Yes	No	c.616G>A (p.G206A)	24	Teens	24	24	NR	24	dizziness, skull asymmetry, hearing loss

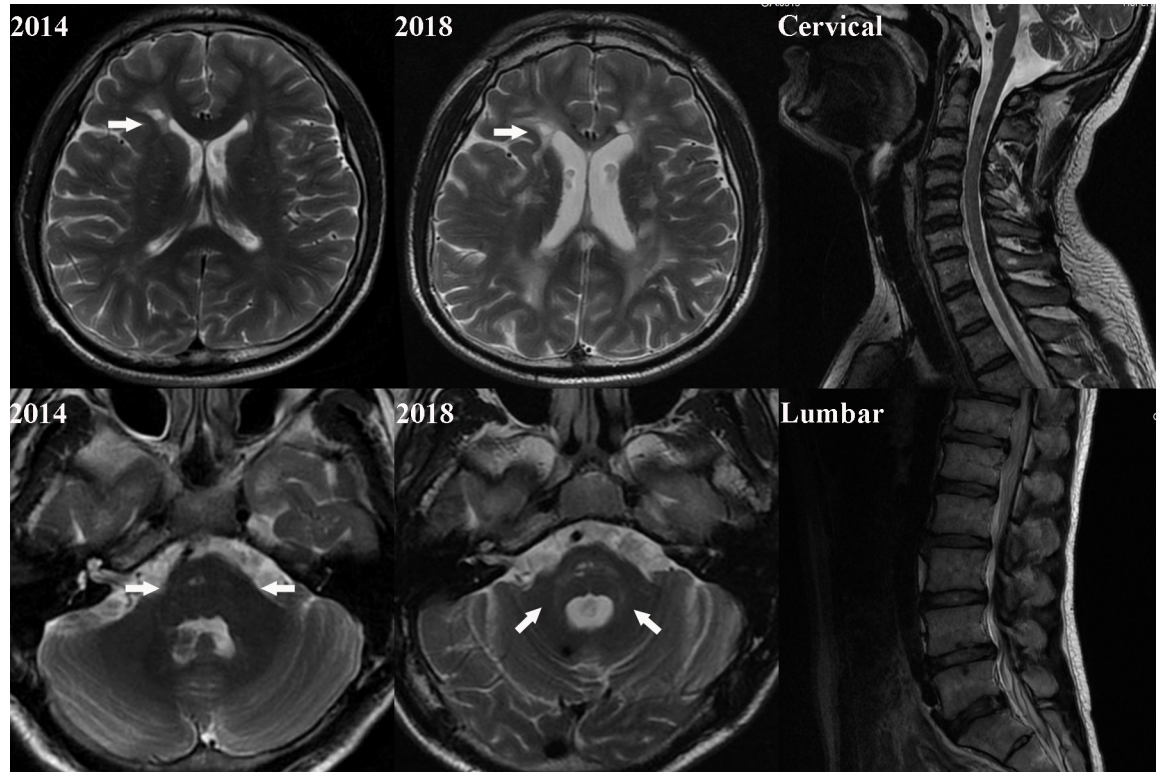


Bougea et al, 2017 <sup>17</sup>	M	31	Greece	No	No	c.496C>T heterozygous	21	No	31	NR	NR	31	vertigo, migraine, deafness, degenerative knee arthritis
Xie et al, 2018 <sup>18</sup>	F	40	China	No	No	c.958G>A/c.1021G>A (p.D320N/p.G341J)	10	22	40	No	NR	No	migraine, multiple cerebral microbleeds
Liu et al, 2018 <sup>19</sup>	F	33	China	No	No	c.854C>T (p.P285L)	30	30	33	28	NR	33	/
Ziaei et al, 2019 <sup>20</sup>	F	34	Iran	Yes	2 sisters	c.805_806insG (p.Ser270fs)	34	34	34	34	34	34	myelitis, recurrent chronic nonseasonal rhinitis
	F	32					32	32	32	32	32	32	myelitis, recurrent chronic nonseasonal rhinitis
	F	30					30	30	30	30	30	30	myelitis, recurrent chronic nonseasonal rhinitis
Li et al, 2019 <sup>21</sup>	F	36	China	Yes	1 sister 1 brother	c.589C>T (p.R197X)	5	32	36	No	NR	36	right hearing loss
	F	37					No	31	35	37	NR	37	no alopecia, diffuse cerebral microbleeds
	M	26					21	24	26	No	NR	No	/
Gündüz et al, 2019 <sup>22</sup>	M	35	Turkey	Yes	No	c.983C>A (p.Ser328*)	+	20	35	26	30	30	/
Present case	M	28	China	Yes	No	c.847G>T (p.Gly283Ter)	20	28	24	25	28	28	multiple cerebral microbleeds

+: symptoms of uncertain time. 0: at birth; NR: not reported. (Note: 16 for teens and 25 for 20s)







### **Highlights**

CARASIL is an exceedingly rare hereditary cerebrovascular disease, and the HTRA1 gene is the causative gene.

A novel mutation site of c.847G>T (p.Gly283Ter) in the HTRA1 gene can result in CARASIL.

Familiarity with the early clinical and imaging features of CARASIL combined with a genetic test is helpful for its early diagnosis and differential diagnosis.

Journal Pre-proof

## Abbreviations

Abbreviations

CARASIL, cerebral autosomal recessive arteriopathy with subcortical infarcts and leukoencephalopathy

SVD, small vessel disease

HTRA 1, HtrA serine protease 1

MRI, magnetic resonance imaging

CTA, computed tomography angiography

DWI, diffusion-weighted imaging

CSF, cerebrospinal fluid

AQP4-Ab, anti-aquaporin-4 antibody

MS, multiple sclerosis

MRC, Medical Research Council

MMSE, Mini-Mental State Examination

MoCA, Montreal Cognitive Assessment

SWI, susceptibility-weighted imaging

NOTCH3, Notch receptor 3

TGF- $\beta$ , transforming growth factor- $\beta$

CADASIL, cerebral autosomal dominant arteriopathy with subcortical infarcts and leukoencephalopathy

HERNS, hereditary endotheliopathy with retinopathy, nephropathy, and stroke

HANAC, hereditary angiopathy with nephropathy, aneurysms, and muscle cramps

T<sub>2</sub>WI, T<sub>2</sub>-weighted imaging

T<sub>2</sub>/FLAIR, T<sub>2</sub>/fluid-attenuated inversion recovery

NR, not reported

### **Conflict of Interest**

The authors have no conflicts of interest to declare.

Journal Pre-proof