



Rare anatomic variation on a 10,000-year-old South American skeleton: the case of Iuzu, Toca dos Coqueiros, Piauí State, Brazil

Jennifer Kerner¹ · Nadia Benmoussa² · Éric Boëda³ · Leonardo Robert De Carvalho Braga⁴

Received: 9 February 2020 / Accepted: 28 May 2020
© Springer-Verlag France SAS, part of Springer Nature 2020

Abstract

Purpose A skeleton named Iuzu has been unearthed from an exceptional middle Holocene burial in Toca dos Coqueiros site, in Serra da Capivara National Park (UNESCO World Heritage Site, Piauí State, Brazil). During a bioarchaeological analysis of its remains, we discovered that Iuzu was suffering from rare vertebral malformations. A double foramen transversaria, the agenesis of a foramen on the atlas and the hypoplasia of the transverse process of the axis have been highlighted. We aimed to deduce the clinical consequences of the malformation on the patient's health.

Methods We proceeded to macroscopic observation and radiography of the bones, then we search for other examples of such a pathology in archaeological literature.

Result The malformation caused vascular insufficiency that may have led to neurological lesions leading to various pains and troubles. The very rare malformations Iuzu presented have not been found on a paleoindian skeleton from South America so far.

Conclusion This case allowed us to examine the conditions of selection of individuals buried in southern Piauí during the Middle Holocene, during which time this rite does not seem to predominate.

Keywords Double foramen transversaria · Neurology · Epilepsy · Brain stem lesion · Altered states of consciousness (ASC) · Shamanism

Introduction

The skeleton of Iuzu, unearthed from Toca dos Coqueiros site by N. Guidon's excavations team, is one of the oldest skeleton found in South America (10,640 BP \pm 50). Our study of this paleoindian skeleton reveals that the individual suffered from rare and disabling malformations. This new data is relevant as it reveals a pathology rarely observed in prehistoric individuals. Iuzu's illness also shed a new light on burial practises among Holocene people.

The Site

Toca dos Coqueiros is a 30 m long and 2,7 m wide rock shelter (Fig. 1a) located in a valley called "Baixão das Mulheres" in Serra da Capivara National Park (UNESCO World Heritage Site, city of Coronel José Dias, Piauí State, Brazil) (Fig. 1b). The site hosts paintings of Agreste style [11] and has been excavated in 1995, 1997 and 1998 by Brazilian Institute FUMDHAM. Since 2018, the excavations have been taken over by the Franco-Brazilian mission of Piauí, under supervision of Pr. É. Boëda.

The Burial

The body has been buried on the left side (Fig. 2a). Lower limbs were hyper flexed and pulled toward the chest. Upper arms were also flexed with the hands brought up near to the head. This flexed position of the body is part of normal funeral practises of Holocene peoples of the Nordeste [11].

✉ Jennifer Kerner
kerner.jennifer@gmail.com

¹ UPOND, Nanterre, France

² Department of Otolaryngology-Head and Neck Surgery, Gustave Roussy Institut, Villejuif, France

³ UMR 7041, UPOND, Nanterre, France

⁴ Departamento da Radiologia, Clínica UDI, CRM 1667, Teresina, Piauí, Brasil



Fig. 1 Archaeological site of Toca dos Coqueiros, Serra da Capivara National Park (city of Coronel José Dias, Piauí State, Brazil) **a** View of the site. **b** Location of the site



Fig. 2 **a** Burial of Iuzu, photography by Fumdam. **b** Projectile points. **c** Beads made of wood

Large arenite slabs were present around and on the corpse. Many lithic artefacts have been found in the immediate vicinity of the body. Four plano-convex scrapers called *lesmas*, 15 flakes, and two exceptional bifacial projectile points, respectively, made of chert and translucent quartz (Fig. 2b), were deposited near the corpse. This assemblage has been previously considered as burial offerings [10]. During our study of bones, we also discovered 26 burned wood beads that complement the funerary furnishings (Fig. 2c).

Unfortunately, no collagen was preserved in the bones. The dating of the burial is hence ensured by C14 dating of a human hair, doubtlessly associated with the corpse. The burial is dated from 10,640 BP \pm 50 (intercept of radiocarbon age with a calibration curve, Beta 104,571) [5].

The Skeleton

Slightly more than eighty osteological pieces taken from the grave have been curated by the museum. The state of conservation of bones is satisfying, except for the scapular and pelvis girdles, both humeri and the skull which have been destroyed by crushing. The acetabulum zone in particular is badly damaged and observations cannot be proposed.

Our study allowed us to go back to some anthropobiological data that had previously been discussed in Brazilian literature but also to discover new information of importance.

Sex: Scholars have not been able to find a consensus about sexual diagnosis. The first study pleads for a feminine individual [10], while the second one [15], see masculine morphological details as prevailing. Even if the sciatic notches seem female-like to us, we argue that a diagnosis remains hazardous considering the bad preservation of the pelvis (Fig. 3a).

Age-at-death: According to the pubic symphysis aspect, previous researchers estimated that Iuzu was aged between 35 and 45 years-old [10]. However, the persistence of metaphyseal incisura on one ulna distal epiphysis and on both femora heads (Fig. 3b) makes us think that the individual was a young adult.

State of health: Previous anthropological studies highlighted healed fractures. A Colle's fracture on the distal epiphysis of the left radius has been seen [10]. Unfortunately, this bone has been lost and we could not examine it. Arthritic lesions on the last lumbar vertebra were also mentioned [10].

During our reappraisal, we observed additional pathologies. We noticed that the intermediate phalanx of the left hallux shows a healed fracture (Fig. 3c). This injury led to a lame walk and an over-solicitation of the opposite lower limb which is clearly visible on right leg and foot bones. On the proximal articular surface of the right hallux intermediate phalanx, some stigmata resulting from intense activity can be seen (Fig. 3d). The distal articulation of the femora, the posterior face of the patella (Fig. 3e) and the proximal articulation of the tibia (Fig. 3f) also show signs of slight osteoporosis and carry some osteophytic neoformations.


Then, a rare malformation of the first two cervical vertebrae deserves to be discussed.

Malformations

Atlas

The atlas is well preserved and its state allowed us to underline an important malformation and some minor

Fig. 3 Elements providing clues to determine sex and age-at-death of the individual: **a** pelvis bone and **b** head of a femur. Pathologies from Iuzu skeleton: **c, d** proximal phalanges of the two hallux. The left one shows signs of a healed fracture (**c**) the right one shows signs of over-solicitation (**d**). **e** over-solicitation on right patella, **f** over-solicitation on proximal articulation of the right tibia

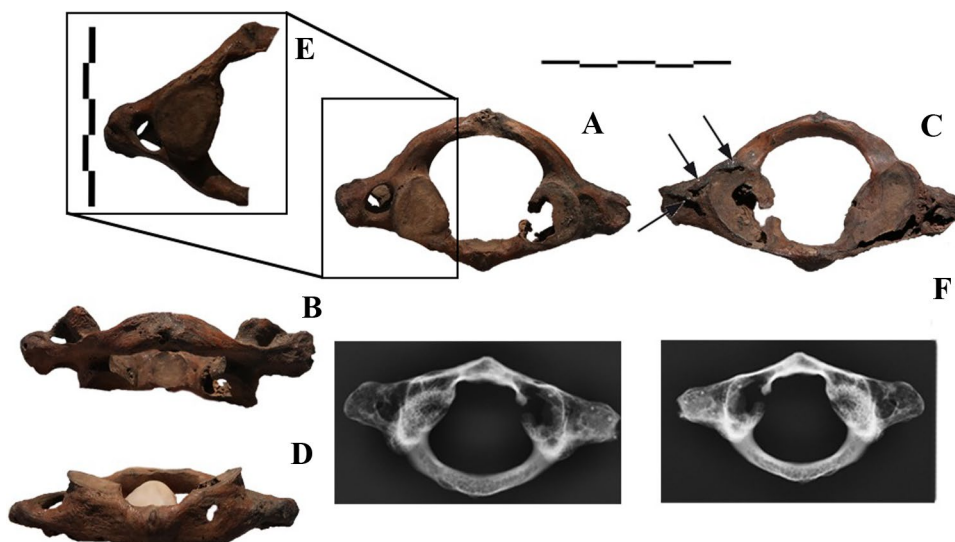


bone modifications. Indeed, on the atlas, some osteophytes may be highlighted. They settled on the transverse process (cranial face) and on the articular surface with the basioccipital bone on the right side (Fig. 4c, arrows). It is important to mention that the visible gap on the vertebral body (posterior face; Fig. 4d) is of taphonomic nature: it is not an accessory transverse foramen.

We note the lack of transverse foramen on the right transverse process of the atlas (Fig. 4). The hypothesis of a congenital agenesis of this foramen may be reasonably raised. Only few papers mention this agenesis and previous studies report this anatomical variation as very rare [13, 14, 19].

The transverse foramen on the left transverse process is a round-shaped hole, following type 1 of Rekha and Neginhal classification [16] which has been based on Taitz and Nathan criteria [20]. This foramen is bipartite, split by a small bony bridge which considerably reduces the space allocated to the passage of the left vertebral artery (Fig. 4e). This variation is also rare on the atlas and usually causes disturbances in the blood flow. The widest of the two available apertures barely exceeds 2 mm: this size is considered insufficient by Gupta et al. [6] who mentioned that at around 2 mm in diameter we can consider that the patient owns a hypoplastic vertebral artery. It is, therefore, difficult to imagine a compensation by the left artery for poor circulation on the right one.

Fig. 4 Atlas. **a** caudal view **b** anterior views **c** cranial view **d** posterior views. **e** The close-up image shows the left double transverse foramen. **f** X-Ray of the atlas



Axis

The axis is not perfectly preserved but we can see that the transverse foramen was at least partially present on the left side (Fig. 5b, red circle). Given the incompleteness of this bone, it is impossible for us to know the morphology of this foramen. It could normally be formed, only partially closed, or bipartite. All blood circulation conditions are, therefore, imaginable in the vertebral artery for the right side at the level of the axis.

The area of the right transverse foramen is lacking. Osteophytic neoformations are observed on the right branch of the axis, anterior to the transverse process location (Fig. 5b, arrow). Significant bone remodelling is also to be highlighted on the right transverse process, making us consider that the transverse process was partially missing (Fig. 5d). A congenital hypoplasia or aplasia of the transverse process is regarded as highly probable. Indeed, a trauma in this zone would have damaged the axis, which remains here perfectly intact. The bone remodelling may have been the consequence of the running of the vertebral artery along the reduced transverse process. Arterial malposition can also explain the presence of a line of osteophytic neoformations settled on the right branch of the

axis. Indeed, it is known that the tortuosity of the vertebral artery can cause severe erosion of the bone [8].

Cervical spine and skull

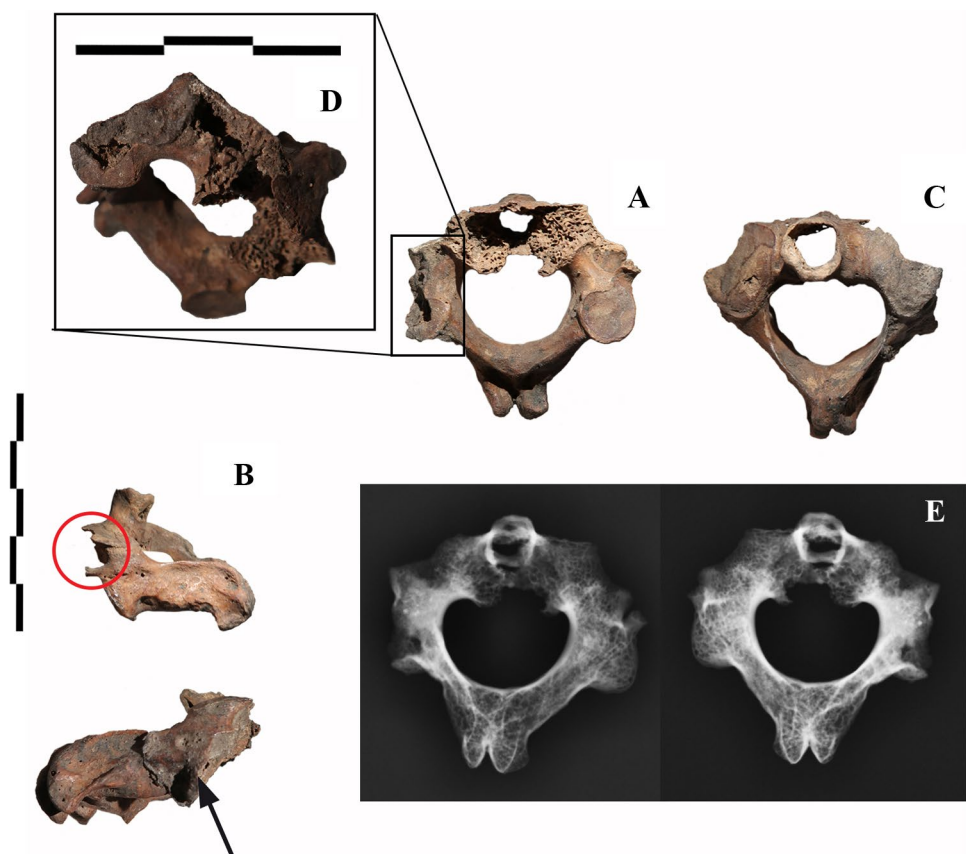
The poor preservation of the bones from the cervical spine prevents us from discussing the state of transverse processes and foramina of the vertebra C3 to C7.

We did not noticed any osteological abnormalities leading to craniovertebral junction issues. Anyway, preservation issues on the skull may have made evidence disappear.

Discussion

Regarding C1, the two malformations combined—the obliteration of the right transverse foramen and the bipartition of the left one—necessarily had consequences on blood circulation in the vertebral artery, since it could not run correctly, and this bilaterally. In case of congenital agenesis of a foramen, the right vertebral artery, therefore, could not go through its usual path. The artery can then have run along the transverse process or have followed the spinal canal, as it has been observed in case of occipitalization of the atlas

Fig. 5 Axis. **a** caudal view **b** lateral views. The circle surrounds the evidence of a transverse foramen. **c** cranial view. **d** The close-up image shows remodelling of the transverse branch of the axis on a postero-caudal view. **e** X-Ray of the axis



[21]. Anyway, regarding the alteration of C2 transverse process, it is more plausible that the vertebral artery has run along the transverse process. This option may create severe vascular insufficiency, but these risks are not well measured in medical literature.

To measure the possible clinical effects on the patient, we focused on studies about hypotrophy of the vertebral artery and arcuate foramen. We did so because these variations may have had the same clinical consequences as obliteration/bipartition of foramina, considering that these morphological modifications lead to a deficit of blood flow in the vertebral artery. The clinical consequences of blood flow deficit on the artery may cause vertebrobasilar insufficiency, thrombus formation, then cerebral ischaemia which can lead to brain stem lesions and, hence, complex neurovascular consequences as vestibular neuronitis and migraine pathogenesis [2, 18]. Neurological disorders, a risk of premature ischaemic stroke and epileptic seizures were also to be feared [1, 4, 12].

Due to its vertebral malformations, the patient has probably endured various pains (headache, torticollis, etc.). Vascular insufficiency may have led to neurological lesions leading to abnormal behaviour or even faintings and staggering epileptic crisis.

The hypothesis of epileptic seizures is supported by different clues on the skeleton. The individual fractured its left radius on the distal level [10, p. 103]. Wrist fractures generally and Colle's fractures specifically are often seen as fractures resulting from adults falling, who suffer from osteoporosis [7]. The individual does not show signs of osteoporotic alteration of its bones: therefore, the fall must have been violent to cause such a fracture. Although there may be many causes for a violent fall during prehistoric times, the hypothesis of epileptic crisis may be considered.

The neurological consequences of the malformation of C1 and C2 may have influenced the role of Iuzu in his group. Indeed, in traditional societies, every disease which can create staggering physical manifestations and Altered States of Consciousness (ASC) may be seen as supernatural phenomena [3]. These individuals were thus regularly considered as "mediums" who were able to communicate with the invisible world and these people may access to position as shaman or sorcerer. Their crises were interpreted as "trances", before Homer offers a neurological explanation for symptoms of epilepsy and other neurological disorders [17].

It's plausible that the symptoms of Iuzu gave him access to a privileged status in the group, because they have been attributed to supernatural explanations. His connection with the sacred world could have been emphasized after his death, thanks to the establishment of a rich burial, settled in a privileged place, according to the funeral practice of inhumation which is probably not the predominant one in this region and at this time [9].

Conclusion

This malformation is likely to cause serious troubles but only few cases have been reported by medical literature. Concerning the archaeological data, to our knowledge, no pathology of this type has been found on paleoindian skeletons so far.

Acknowledgements We want to warmly thank the Museum of American Man, the FUMDHAM, Niede Guidon, Kieran Anslow, Dr. Christiano from Clínica Cristiano Paes Landim, Iderlan and Marabela Souza.

Author contributions Statement of Contribution of Authors for the article "Rare anatomic variation on a 10 000-year-old South American skeleton: the case of Iuzu, Toca dos Coqueiros, Piauí State, Brazil." Jennifer Kerner (Ph.D, UPOND, kerner.jennifer@gmail.com), Nadia Benmoussa (M.D., Department of Otolaryngology-Head and Neck Surgery, Gustave Roussy Institut, Villejuif, France, nadia.benmoussa@yahoo.fr), Éric Boëda (M.D., Ph.D, UPOND, UMR 7041, boeda.eric@gmail.com) and Leonardo Robert De Carvalho Braga (M.D. CRM 1667, Clínica UDI, Departamento da Radiologia, Teresina, Piauí, Brasil, leonardorb@gmail.com). JK: project development, data collection, data analysis, manuscript writing. NB: data analysis, and manuscript editing. EB: manuscript editing. LRDCB: manuscript editing.

Compliance with ethical standards

Conflict of interest No conflict of interest to declare.

References

1. Chang Y-M, Huang Y-C, Huc HH (2006) Toward a further elucidation: role of vertebral artery hypoplasia in acute ischemic stroke. *Eur Neurol* 55:193–197. <https://doi.org/10.1159/000093868>
2. Chuang Y-M, Chan L, Wu HM, Lee SP, Chu YT (2012) The clinical relevance of vertebral artery hypoplasia. *Acta Neurol Taiwan* 21(1):1–7
3. Dobkin de Rios M, Winkelman M (1989) Shamanism and altered states of consciousness: an introduction. *J Psychoact Drugs* 21(1):1–7. <https://doi.org/10.1080/02791072.1989.10472137>
4. Elgafy H, Pompo F, Vela R, Elsamaloty HM (2014) Ipsilateral arcuate foramen and high-riding vertebral artery: implication on C1–C2 instrumentation. *Spine J* 14(7):1351–1355. <https://doi.org/10.1016/j.spinee.2014.01.054>
5. Guidon N, Parenti F, Oliveira C, Vergne C (1998) Nota sobre a Sepultura da Toca dos Coqueiros. *Clio* 13:187–192
6. Gupta R, Kapoor K, Kochhar S, Sharma A, Sahni D, Chawla K (2014) Variations in morphometry of foramina transversaria and vertebral artery in subaxial cervical region and its surgical implications. *Int J Healthc Biomed Res* 3(1):47–54
7. Hove LM, Fjeldsgaard K, Reitan R, Skjeie R, Sörensen FK (1995) Fractures of the distal radius in a Norwegian city. *Scand J Plast Reconstr Surg Hand Surg* 29(3):263–267. <https://doi.org/10.3109/02844319509050137>
8. Hyypä SE, Laasonen EM, Halonen V (1974) Erosion of cervical vertebrae caused by elongated and tortuous vertebral arteries. *Neuroradiology* 7:49–51

9. Kerner J, Benmoussa N, Boëda E, De Carvalho Braga L R (in press). Um enterro excepcional de 10.000 anos de idade no sítio da Toca dos Coqueiros, Piauí, Brasil. *Revista da Arqueologia*
10. Lessa A, Guidon N (2002) Osteobiographic analysis of skeleton i, sítio toca dos coqueiros, Serra da capivara national park, Brazil, 11,060 BP: first results. *Am J Phys Anthropol* 118:99–110. <https://doi.org/10.1002/ajpa.10084>
11. Martin G (1994) Os rituais funerários na Pré-História do Nordeste. *Clio* 1(10):29–46
12. Mehrotra A, Chunnilal JS, Das KK, Srivastava A, Kumar R (2013) Atlanto-axial dislocation associated with anomalous single vertebral artery and agenesis of unilateral internal carotid artery. *Asian J Neurosurg* 8(3):164. <https://doi.org/10.4103/1793-5482.121692>
13. Metin Tellioglu A, Durum Y, Gok M, Polat AG, Karaman CZ, Karakas S (2017) Evaluation of morphologic and morphometric characteristic of foramen transversarium on 3-dimensional multidetector computed tomography angiography. *Turk Neurosurg*. <https://doi.org/10.5137/1019-5149.JTN.18839-17.3> (on line consultation, 28/11/2018)
14. Murlimanju BV, Prabhu LV, Shilpa K, Rai R, Dhananjaya PJ (2011) Accessory Transverse Foramina in the Cervical Spine: Incidence, Embryological Basis. *Morphol Surg Import Turkish Neurosurg* 21(3):384–387. <https://doi.org/10.5137/1019-5149.JTN.4047-10.0>
15. Nelson AR (2005) "Osteobiographics" of dos coqueiros paleoindian reconsidered: comment on lessa and guidon (2002). *Am J Phys Anthropol* 126(4):401–403. <https://doi.org/10.1002/ajpa.20072>
16. Rekha BS, Neginhal DD (2014) Variations in foramen transversarium of atlas vertebra: An osteological study in South Indians. *Int J Res Health Sci* 2(1):224–228 (on line consultation, 28/11/2018)
17. Riggs Allison J, Riggs Jack E (2005) Epilepsy's role in the historical differentiation of religion, magic, and science epilepsy. *Off J Int Leag Against Epilepsy* 46(3):452–453
18. Sabnis A (2015) Anatomical variations in foramen transversarium. *Med Sci* 5(12):504–506
19. Qudusia S, Ramakrishana A, Varalakshmi KL, Shariff MH, Blessina (2015) Variation of foramen transversarium in atlas vertebrae: a morphological study with its clinical significance. *Nitte Univer J Health Sci* 5(2):80–83
20. Taitz C, Nathan H (1978) Some observations on the posterior and lateral bridge of atlas. *Acta Anat (basel)* 127(3):212–217
21. Wang S, Wang C, Liu Y, Yan M, Zhou H (2009) Anomalous vertebral artery in craniovertebral junction with occipitalization of the atlas. *Spine* 34(26):2838–2842. <https://doi.org/10.1097/BRS.0b013e3181b4fb8b>

Publisher's Note Springer Nature remains neutral with regard to jurisdictional claims in published maps and institutional affiliations.