

Neurocase

The Neural Basis of Cognition

ISSN: (Print) (Online) Journal homepage: <https://www.tandfonline.com/loi/nncs20>

Unusual cortical symptoms of dural arteriovenous fistula mimicking transient ischemic attack

Sukyoon Lee , Jin-Ho Jung , Eun Joo Chung & Jung Hwa Seo

To cite this article: Sukyoon Lee , Jin-Ho Jung , Eun Joo Chung & Jung Hwa Seo (2020): Unusual cortical symptoms of dural arteriovenous fistula mimicking transient ischemic attack, Neurocase, DOI: [10.1080/13554794.2020.1775856](https://doi.org/10.1080/13554794.2020.1775856)

To link to this article: <https://doi.org/10.1080/13554794.2020.1775856>



Published online: 03 Jun 2020.



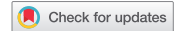Submit your article to this journal [↗](#)




View related articles [↗](#)



View Crossmark data [↗](#)



Unusual cortical symptoms of dural arteriovenous fistula mimicking transient ischemic attack

Sukyoon Lee , Jin-Ho Jung, Eun Joo Chung and Jung Hwa Seo

Department of Neurology, Inje University College of Medicine, Busan Paik Hospital, Busan, South Korea

ABSTRACT

The clinical presentation of dural arteriovenous fistula (DAVF) can vary. A 47-year-old man complained of transient difficulty playing badminton and speech disturbance for 10 minutes. His symptoms were suspected to be visuomotor coordination deficit similar to optic ataxia and anomic aphasia. Magnetic resonance imaging and angiography revealed vasogenic edema and perfusion delay in the left temporo-occipital area and an abnormal connection between the left occipital artery and transverse sinus. Transverse sinus DAVF was diagnosed by conventional cerebral angiography. We believe that this is the unique case of DAVF manifested as visuomotor coordination deficit suspected optic ataxia and anomic aphasia.

ARTICLE HISTORY

Received 12 May 2019
Accepted 18 May 2020

KEYWORDS

Dural arteriovenous fistula;
transient ischemic attack;
visuomotor coordination;
optic ataxia; anomic aphasia

Introduction

Intracranial dural arteriovenous fistulae (DAVF) are a rare vascular malformation and are most commonly located in the transverse, sigmoid, and cavernous sinuses. DAVF may present as acute lesions in brain magnetic resonance imaging (MRI) that seem like an ischemic stroke.

The common clinical manifestations of DAVF include tinnitus, headache, cranial nerve palsies, and focal neurologic deficits. Cortical neurologic symptoms are not rare as well.

Herein, we report the unique case of DAVF manifested as transient ischemic attack (TIA) with visuomotor coordination deficit and anomic aphasia. We also presented the changes in MRI findings and neuropsychological result after the treatment of DAVF.

Case

A 47-year-old, right-handed man presented at the emergency department because of transient difficulty playing badminton and speech disturbance that had occurred 90 minutes prior to the visit. He was reportedly a good badminton amateur. While playing badminton as usual, 90 minutes prior to his visit, he noticed that he was unable to hit the shuttlecock when it arrived from a near distance, yet, he was able to hit it when it arrived from a farther distance. However, he did not experience any arm weakness. At that point, he took a break, and he noticed that he could not recall a familiar word, which lasted for 10 minutes. Subsequently, all symptoms subsided. There was no report of decline in consciousness or memory.

The past medical history was significant for deep vein thrombosis (DVT) in the right leg; he had been diagnosed and treated at another hospital about 7 years prior. The patient denied smoking, severe headache, or tinnitus. He reported drinking

alcohol (Soju one bottle) two or three times per week. The family history was significant for DVT in one of his brothers.

At initial visit, the patient's blood pressure was 140/80 mmHg, pulse rate was 88 bpm, and body temperature was 36.5°C. A neurologic examination revealed no abnormal findings in the motor, coordination, language, and memory function, except for a mild impairment in the immediate recall. The National Institutes of Health Stroke Scale score was zero.

Based on the history, we suspected that his right arm symptom might represent visuomotor coordination deficit, since the patient's ability to hit the shuttlecock depends on the degree of visual guidance. We thought his symptom was similar to optic ataxia, one of the visuomotor coordination deficits. We suspected the transient speech disturbance to represent anomic aphasia.

Coagulation function tests, including protein C antigen, protein S antigen, factor V Leiden mutation, antiphospholipid antibody, anti-cardiolipin antibody, and antithrombin III and lupus anticoagulant antibody, were normal. All other laboratory parameters were within the normal limits, but D-dimer level was elevated to 1.11 µg/mL. The initial diffusion-weighted MR images did not reveal any diffusion-restricted lesions. The fluid-attenuated inversion recovery (FLAIR) images revealed a cortical high-signal-intensity lesion in the left temporo-occipital area, and the susceptibility-weighted images (SWI) revealed two microbleeds in the same area. The perfusion-weighted magnetic resonance images revealed prolonged time-to-peak and mean transit time parameters in the same area. There were no abnormalities in cerebral blood flow and cerebral blood volume images. No steno-occlusive arterial lesion was detected with the time-of-flight (TOF) magnetic resonance angiography (MRA) and the gadolinium-enhanced MRA. However, the TOF-MRA and its source images revealed an abnormal flow void signal between the left occipital artery and the left transverse sinus (Figure 1).

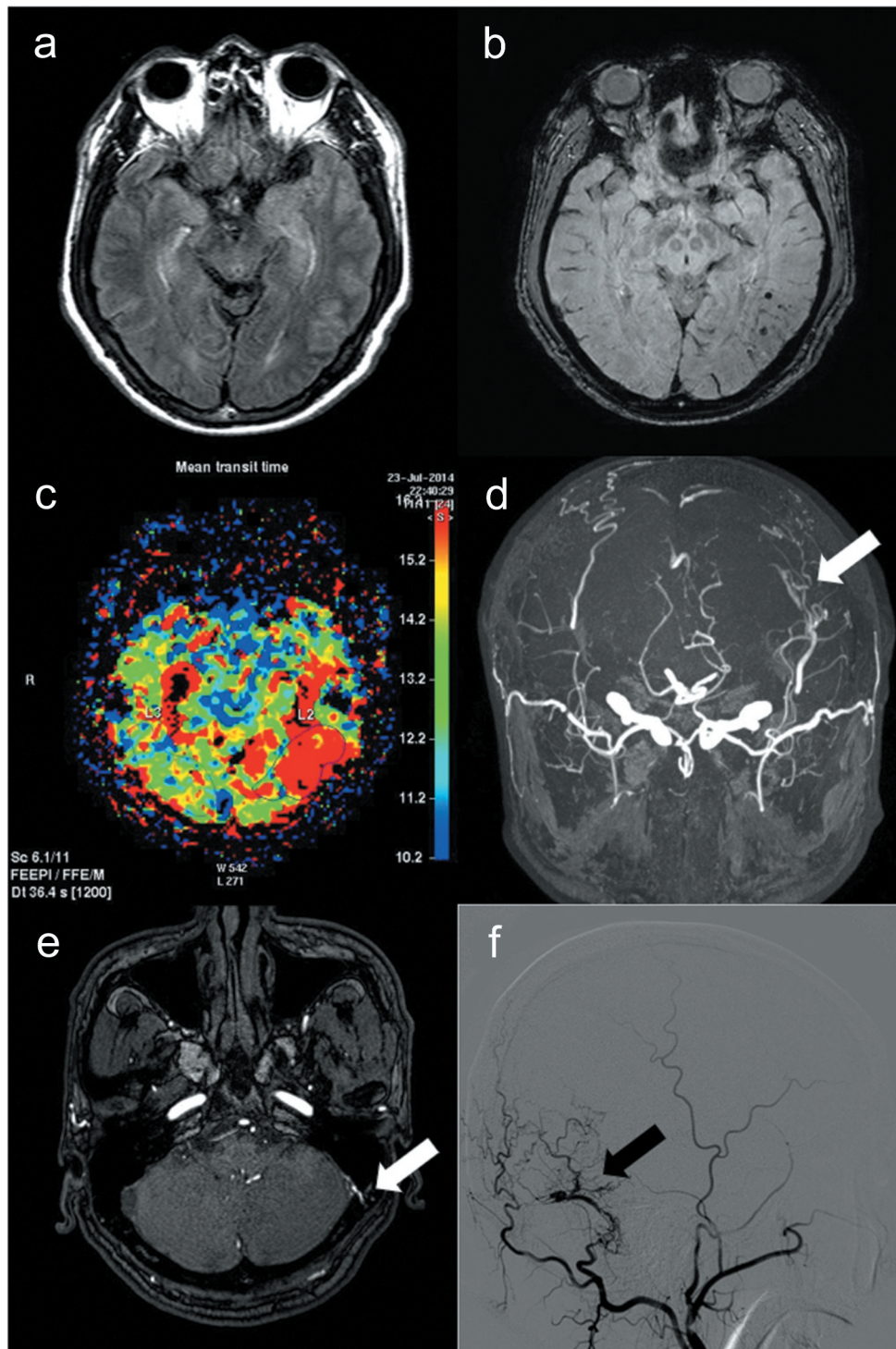


Figure 1. Findings of cortical hyperintensity in fluid-attenuated inversion recovery image (a), microbleeding in a susceptibility-weighted image (b), and mean transit time delay (c) in the left temporo-occipital area. Abnormal artery-to-dural sinus shunt (white arrow) was identified on magnetic resonance angiography (d) and its source image (e). Left external carotid angiography (f) revealed a dural arteriovenous fistula supplied by the left occipital artery and drained to the left transverse sinus (black arrow).

Seoul Neuropsychological Screening Battery (SNSB) was performed and cognitive impairment was determined with the digit span test (DST, 5.17 percentile), the Korean version of the Boston naming test (K-BNT, 0.10 percentile), and the Seoul verbal learning test elderly version: delayed recall (SVLT-E: DR, 3.13 percentile).

The MRI and the perfusion imaging study revealed only a restricted lesion in the temporo-occipital area. This lesion could account for the optic ataxia-like transient symptoms in the patient. However, anomia, that is, difficulty in word finding, can be caused by a lesion in the temporo-occipital area as well. We, therefore, suspected that the patient's transient

symptoms could be related to a perfusion defect in the temporo-occipital area.

Conventional digital subtraction angiography (DSA) was performed and the findings revealed a connection between the left occipital artery and the left transverse sinus, with surrounding engorged pial veins. On the eighth day from admission, transarterial DAVF embolization was performed via the left occipital artery and the middle meningeal artery, using Onyx. Transthoracic echocardiography, 24-hour Holter monitoring, and 24-hour ambulatory blood pressure monitoring were normal, whereas transesophageal echocardiography revealed an incidental finding of patent foramen ovale with bi-directional shunt.

One month after the embolization, the SNSB was repeated and neuropsychological improvement was observed in DST (18 percentile), K-BNT (3.2 percentile), and SVLT-E: DR (29.22 percentile). There was also an incidental impairment in Rey complex figure test: copy (11.03 percentile). A month later, MRI, MRA, and perfusion-weighted images were repeated, and there were no findings of an abnormal signal, abnormal vascular connection, or perfusion delay (Figure 2). During the 1-year follow-up, the patient was free of any neurologic symptoms and there was no interval change of the embolization site, as evaluated with MRA.

Discussion

DAVF can be accompanied with various neurologic symptoms and can have different imaging presentations. According to the present literature, DAVF could have a TIA-like presentation, such as motor or sensory symptoms, as well as various cortical symptoms (Kim et al., 2012; Lagares et al., 2010; Reynolds et al., 2017). The various symptoms can be induced by regional decreases in cerebral blood flow, caused by cortical venous reflux, venous congestion, and retrograde venous drainage. Furthermore, the intermittently increased pressure from the engorged and congested veins can produce the transient neurological symptoms in DAVF (Kim et al., 2012).

The neurologic symptoms in this patient could be summarized as transient visuomotor coordination deficit and anomia. The patient complained that he could hit the shuttlecock coming from a farther distance, but not the shuttlecock coming from a near distance. We suspected that degree of visual guidance may have caused this difference. We found that the patient's symptom is similar to symptom seen in optic ataxia. Optic ataxia is an abnormal neurological symptom characterized by impaired visuomotor guidance (Bálint & Harvey, 1909). The difficulties in

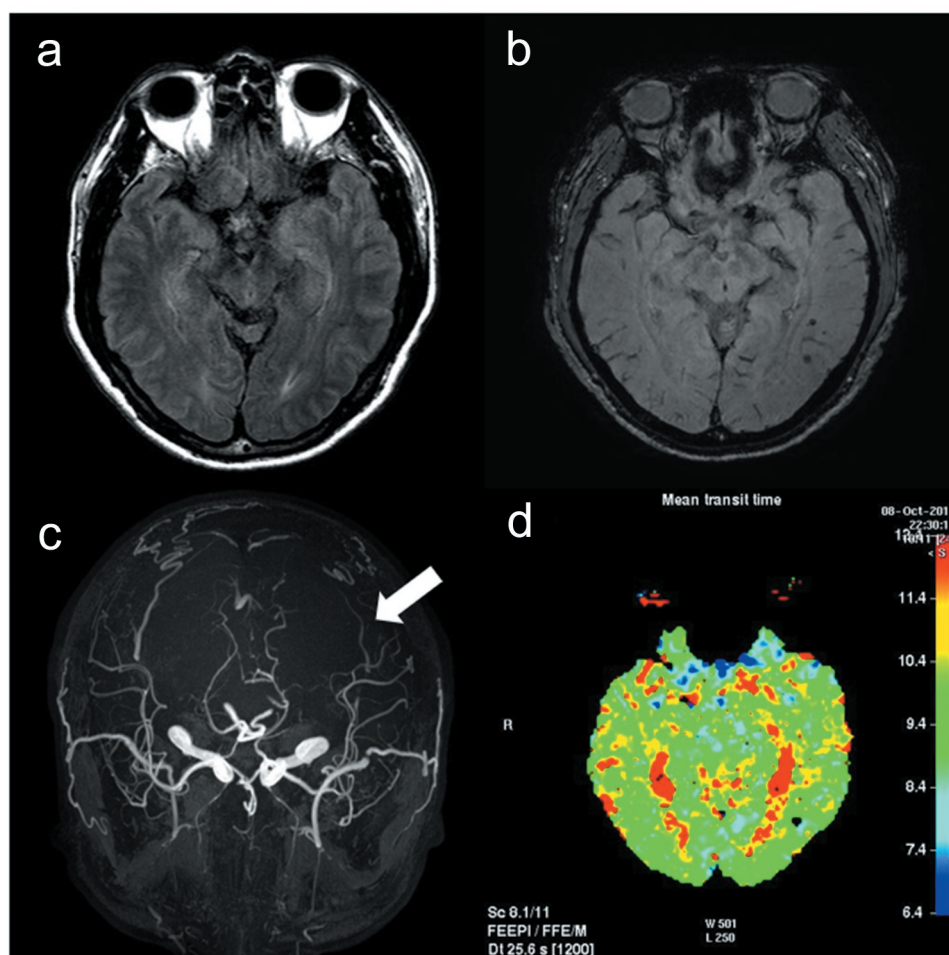


Figure 2. The cortical hyperintensity (a) and the abnormal artery-to-dural sinus shunt (white arrow in c) disappeared and the mean transit time was normalized (d) after fistula embolization. However, microbleeding was still noted in the left temporo-occipital area (b).

optic ataxia are especially obvious when both the target and the hand are present in the visual periphery, as for perceiving/reacting to target jump (McIntosh et al., 2011). In this case, the shuttlecock coming from a near distance was likely to be in the periphery of the patient's vision, so he was unable to hit it. Conversely, the shuttlecock coming from a farther distance was likely to be in the center of the patient's vision and he was, therefore, able to hit it. However, the patient's symptoms disappeared, and neurological examination could not confirm the sign of optic ataxia.

Anomic aphasia is a subtype of aphasia characterized by word finding and retrieval difficulty. Anomia may arise from dysfunction caused by lesions of the left anterior, inferior, and posterior middle/superior temporal cortex, the posterior inferior frontal and inferior parietal cortices (DeLeon et al., 2007). In this case, the transient word finding and recall difficulty was suspected to be anomic aphasia, which was supported by the SNSB result as well. Both optic ataxia and anomic aphasia could be associated with the hypoperfused lesion in the temporo-occipital area.

This patient might have been diagnosed with TIA-mimicking syndrome because of the transient neurologic symptoms and the absence of diffusion restriction in the MR images. However, there were abnormal findings indicative of vasogenic edema, such as cortical FLAIR hyperintensity and no diffusion restriction (Reynolds et al., 2017), microbleeds, localized perfusion delay (Kim et al., 2012; Lagares et al., 2010) and abnormal occipital artery to transverse sinus connections on TOF-MRA (Azuma et al., 2015) that could not be explained by arterial ischemia. These findings indicated that venous hypertension is likely to be involved in the pathophysiology of the symptoms. Hence, the above multimodal neuroimaging techniques played an important role for the suspicion and diagnosis of DAVF in a patient that might have been diagnosed with TIA.

Interestingly, the patient reported that all symptoms had disappeared, while in fact, multiple domain cognitive impairments were confirmed with the neuropsychological evaluation. This means that even patients previously diagnosed with TIA might have subclinical signs, such as cognitive impairment or higher cortical deficits. Moreover, it may be necessary to make a detailed neurologic evaluation even if a patient diagnosed with DAVF does not report any neurologic symptoms.

In conclusion, we believe that this is the unique case of DAVF with unusual cortical symptoms, such as transient

visuomotor coordination deficit suspected optic ataxia and anomic aphasia. After the DAVF was treated, the perfusion defects recovered, and there was no recurrence of neurologic symptoms over the 1-year follow-up period.

Disclosure statement

The authors have no financial conflicts of interest.

ORCID

Sukyoon Lee  <http://orcid.org/0000-0002-5551-0273>

References

- Azuma, M., Hirai, T., Shigematsu, Y., Kitajima, M., Kai, Y., Yano, S., Nakamura, H., Makino, K., Iryo, Y., & Yamashita, Y. (2015). Evaluation of intracranial dural arteriovenous fistulas: comparison of unenhanced 3T 3D time-of-flight MR angiography with digital subtraction angiography. *Magnetic Resonance in Medical Sciences*, 14(4), 285–293. <https://doi.org/10.2463/mrms.2014-0120>
- Bálint, R., & Harvey, M. (1909). Seelenlähmung des «Schauens», optische Ataxie, räumliche Störung der Aufmerksamkeit. *Monatsschrift für Psychiatrie und Neurologie*, 25(1), 51–81. <https://doi.org/10.1159/000210464>
- DeLeon, J., Gottesman, R. F., Kleinman, J. T., Newhart, M., Davis, C., Heidler-Gary, J., Lee, A., & Hillis, A. E. (2007). Neural regions essential for distinct cognitive processes underlying picture naming. *Brain*, 130(5), 1408–1422. <https://doi.org/10.1093/brain/awm011>
- Kim, Y. W., Kang, D. H., Hwang, Y. H., & Park, S. P. (2012). Unusual MRI findings of dural arteriovenous fistula: Isolated perfusion lesions mimicking TIA. *BMC Neurology*, 12(1), 77. <https://doi.org/10.1186/1471-2377-12-77>
- Lagares, A., Millan, J. M., Ramos, A., Alen, J. A., & Gallego, J. H. (2010). Perfusion computed tomography in a dural arteriovenous fistula presenting with focal signs: Vascular congestion as a cause of reversible neurologic dysfunction. *Neurosurgery*, 66(1), E226–227; discussion E227. <https://doi.org/10.1227/01.NEU.0000361996.27921.6C>
- McIntosh, R. D., Mulroue, A., Blangero, A., Pisella, L., & Rossetti, Y. (2011). Correlated deficits of perception and action in optic ataxia. *Neuropsychologia*, 49(1), 131–137. <https://doi.org/10.1016/j.neuropsychologia.2010.11.017>
- Reynolds, M. R., Lanzino, G., & Zipfel, G. J. (2017). Intracranial dural arteriovenous fistulae. *Stroke*, 48(5), 1424–1431. <https://doi.org/10.1161/STROKEAHA.116.012784>