

Case Report

Asymmetric SIRPIDs in a vertebrobasilar stroke: Implications for understanding its origin

José L. Fernández-Torre^{a,d,e,*}, María Martín-García^{a,e}, Enrique Marco de Luca^{b,e}, Miguel A. Hernández-Hernández^{c,e}

^a Department of Clinical Neurophysiology, Marqués de Valdecilla University Hospital, Santander, Cantabria, Spain

^b Departments of Radiology Marqués de Valdecilla University Hospital, Santander, Cantabria, Spain

^c Departments of Intensive Medicine, Marqués de Valdecilla University Hospital, Santander, Cantabria, Spain

^d Department of Physiology and Pharmacology, University of Cantabria (UNICAN), Santander, Cantabria, Spain

^e Biomedical Research Institute (IDIVAL), Santander, Spain

ARTICLE INFO

Keywords:

Stimulus-induced rhythmic
Periodic, or ictal discharges
Vertebrobasilar stroke
Thalamus
Midbrain
Pathophysiology

1. Introduction

Stimulus-induced rhythmic, periodic, or ictal discharges (SIRPIDs) are abnormal discharges occurring after alerting stimuli, including auditory, tactile or nociceptive stimulation in comatose or stuporous patients. In recent years, several studies have described the incidence and clinical significance of SIRPIDs [1,2], but the pathophysiology remains incompletely understood.

The aim of this report is to describe the case of a patient who had a vertebrobasilar ischemic event in whom asymmetric SIRPIDs due to an extensive right thalamic and mesencephalic infarction, were noted. This case provides data that allows us to understand the mechanisms that might underlie SIRPIDs.

2. Case report

A 72-year-old woman was admitted to our emergency unit because of an acute decrease in the level of consciousness. She had history of atrial fibrillation on treatment with oral acenocoumarol and bisoprolol. A computed tomography (CT) scan of the brain revealed an acute ischemic stroke involving the right thalamus and midbrain from a top of the basilar thrombosis. No signs of acute bleeding were observed. She

was transferred to the intensive care unit (ICU), where neurological examination showed her to be comatose with the right pupil larger and with an absent pupil reaction. At 72 h, a second cranial CT scan disclosed a significant increase in infarction of the right thalamus and midbrain, and the appearance of new acute ischemic lesions in the right occipital lobe and right hemicerebellum (Fig. 1), along with a small ischemic lesion in the left thalamus. Despite 4 days without sedation, the patients' clinical state worsened to a Glasgow Coma Scale 4 and extensor posturing to noxious stimuli. Video-electroencephalogram (v-EEG) showed slowing of the background activity consistent with a diffuse encephalopathy. Pain and auditory stimulation produced asymmetric bilateral rhythmic, negative-positive sharp waves involving both frontal regions notably more prominent on the left (Fig. 2), corresponding to SIRPIDs. Two days later, v-EEG remained unchanged. Given the neurological situation and the poor prognosis, the clinical team and family decided to limit therapeutic support and the patient died on day 5.

3. Discussion

At present, the exact pathophysiology of SIRPIDs is unknown. SIRPIDs lie on an electroencephalographic spectrum now known as the

* Corresponding author at: Department of Clinical Neurophysiology, Marqués de Valdecilla University Hospital, Avda. Valdecilla 25, 39008, Santander, Cantabria, Spain.

E-mail address: joseluis.fernandezt@scsalud.es (J.L. Fernández-Torre).

<https://doi.org/10.1016/j.clineuro.2020.105980>

Received 28 April 2020; Received in revised form 24 May 2020; Accepted 29 May 2020

Available online 02 June 2020

0303-8467/ © 2020 Elsevier B.V. All rights reserved.

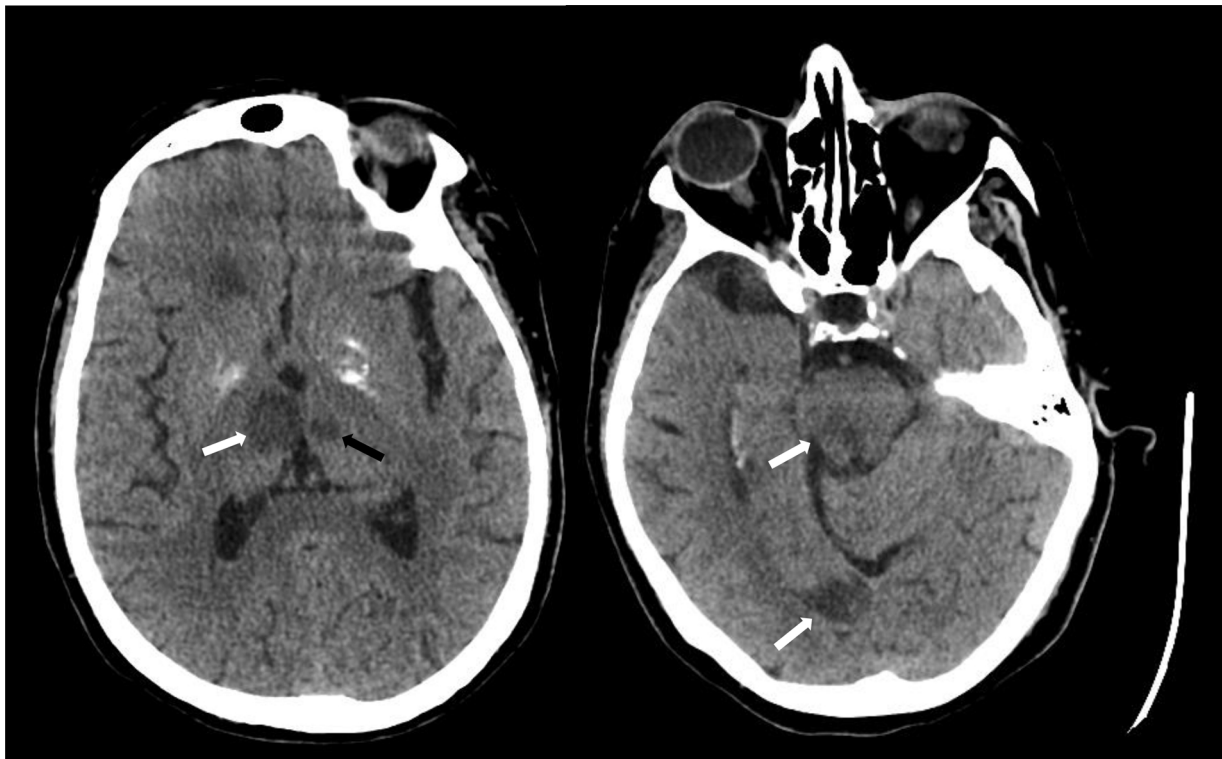

Fig. 1. A Brain CT scan revealing ischemic lesions involving the right thalamus, midbrain and occipital lobe (white arrows). Note the presence also of a small infarct in the left thalamus (black arrow).

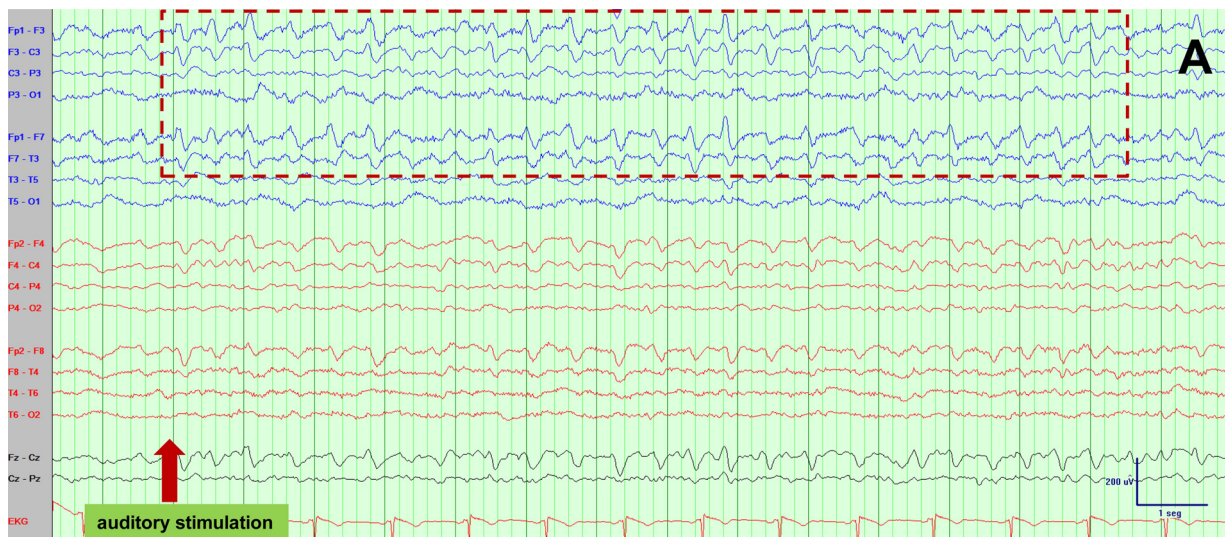


Fig. 2. A, B and C) Observe the occurrence of bilateral but asymmetric rhythmic, frontal sharp waves notably more prominent on the left side elicited by auditory and painful stimulation compatible with SIRPIDs. Note the significant asymmetry of SIRPIDs on the right side. Low filter: 0.53 Hz; High filter: 70 Hz; Notch filter: 50 Hz. Vertical bar: 200 µV; horizontal bar: 1 s (30 mm/s) in A and B, and 2 s (15 mm/s) in C.

"ictal-interictal continuum" [2]. SIRPIDs occur when a sensory stimulus of a different nature (tactile, auditory, nociceptive) facilitates the appearance of rhythmic or periodic discharges from an injured cortex. The process likely involves dysregulation of subcortical–cortical projections, particularly thalamocortical in a markedly abnormal brain with a hyperexcitable cortex. Of note, there does not appear to be a specific cause of SIRPIDs, and they have been associated with anoxic brain injury and cardiac arrest, cerebral hemorrhage, traumatic brain injury, drug toxicity, and metabolic disturbances [1,2].

The thalamus contains excitatory thalamocortical projections from neurons that transmit modality-specific inputs (sensory relay nuclei) in

an organized topographic manner to the middle layers of specific cortical areas; and of neurons that receive less clear subcortical inputs which project more diffusely to the cerebral cortex [3]. Moreover, the thalamus has reciprocal connections with the cerebral cortex, representing the thalamo-cortico-thalamic network (Fig. 3). Cortico-thalamic projections provide excitatory signals to both neuronal populations and to the thalamic reticular nucleus (TRN). The TRN contains GABAergic interneurons which provide feedback inhibition to the thalamocortical neurons.

SIRPIDs occur mainly in patients with severe impairment of the level of consciousness. It is reasonable to think that the structures

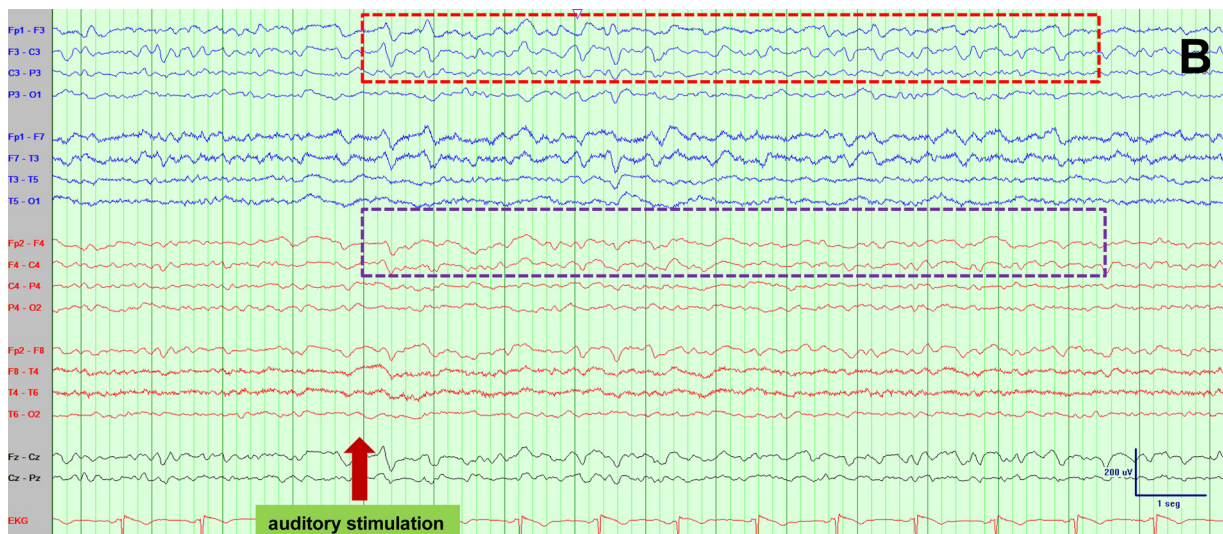


Fig. 2. (continued)

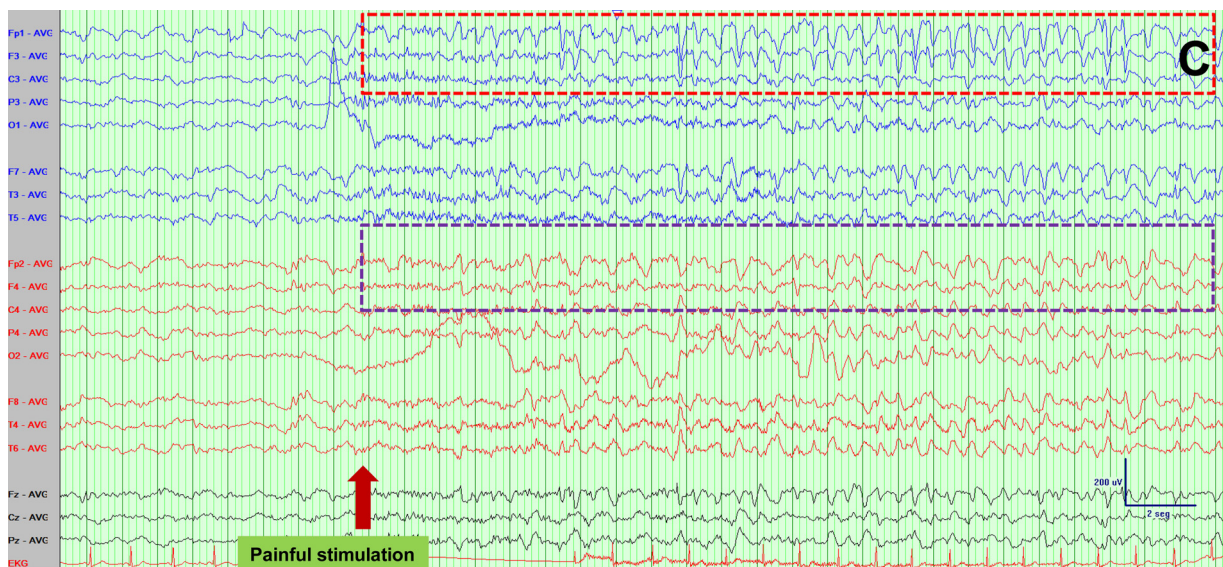

Fig. 2. (continued)

involved in the arousal system could have a role in its pathophysiology. Thus, an abnormal state of arousal has been implicated in the source of stimulus-induced seizures and SIRPIDs. It seems reasonable to speculate that there is cortical hyperexcitability in which sudden activation of sensory pathways can trigger epileptiform-induced EEG patterns. Conversely, the TRN might also play a critical role in enabling the conscious appreciation of stimuli and events by synchronizing activity in the thalamus with cortical activity. Hence, the TRN can be considered the "gatekeeper of the gatekeeper (thalamus)". In the presence of a disruption of the excitatory cortico-thalamic axons, the absence of inhibition mediated by the TRN, might facilitate the occurrence of SIRPIDs.

In our case, there was an extensive right thalamic and mesencephalic infarction apparently closely related to the abolition of the SIRPIDs in the right hemisphere. There was no evidence suggesting the coexistence of diffuse cortical damage. The involvement of the TRN-mediated inhibition by the thalamic infarct might lead to an excess of cortical stimulation, facilitating the occurrence of reflex epileptiform discharges. Another hypothesis is that the thalamic lesions caused a decrease in the activity of the excitatory thalamocortical projections resulting in the asymmetry of the right SIRPIDs (Fig. 3). Interestingly,

the presence of SIRPIDs between 36 and 72 h in comatose patients after cardiac arrest has been recently reported with a favorable outcome. The investigators suggested that SIRPIDs might be considered as a type of reactivity in the context of a viable hyperexcitable cortex [4]. However, it is possible that in specific clinical situations, the source of SIRPIDs is via a different pathophysiological mechanism and, therefore, may be associated with a different prognosis. Of note, a recent case exhibiting corneal reflex-induced SIRPIDs suggests more extensive damage that includes the brainstem [5].

In conclusion, while the exact pathophysiology of SIRPIDs has not been determined, our clinical case provides some evidence of the role of the thalamus and midbrain in the generation of this intriguing electroencephalographic phenomenon.

Ethical position statement

“We confirm that we have read the Journal’s position on issues involved in ethical publication and affirm that this report is consistent with those guidelines.”

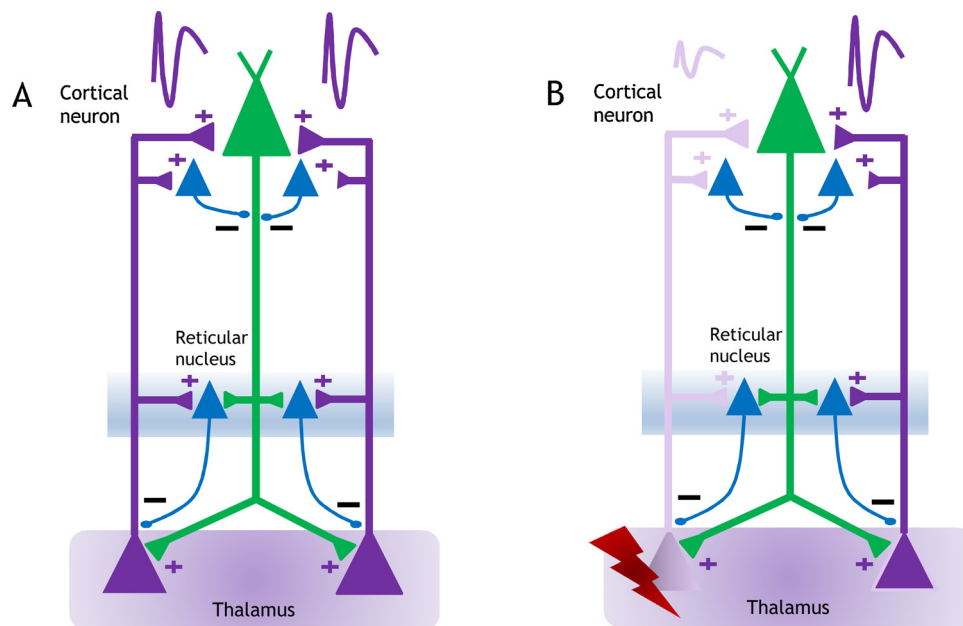


Fig. 3. A) Thalamocortico- thalamic network that could be implicated in the origin of SIRPIDS; B) Note that the lesion of the right thalamus and decrease of the function of the right thalamo-cortical projections could explain the presence of asymmetric SIRPIDS.

Declaration of Competing Interest

The authors declare that they have no conflicts of interests.

References

[1] L.J. Hirsch, J. Claassen, S.A. Mayer, R.G. Emerson, Stimulus-induced rhythmic, periodic, or ictal discharges (SIRPIDS): a common EEG phenomenon in the critically ill, *Epilepsia* 45 (2004) 109–123, <https://doi.org/10.1111/j.0013-9580.2004.38103.x>.
 [2] E.L. Johnson, P.W. Kaplan, E.K. Ritzl, Termination patterns of stimulus-induced

rhythmic, periodic, or ictal patterns and spontaneous electrographic seizures, *Clin. Neurophysiol.* 128 (2017) 2279–2285, <https://doi.org/10.1016/j.clinph.2017.09.006>.
 [3] E.E. Benarroch, The midline and intralaminar thalamic nuclei. Anatomic and functional specificity and implications in neurologic disease, *Neurology* 71 (2008) 944–949, <https://doi.org/10.1212/01.wnl.0000326066.57313.13>.
 [4] G. Barbella, J.W. Lee, V. Alvarez, et al., Prediction of regaining consciousness despite an early epileptiform EEG after cardiac arrest, *Neurology* 94 (2020) e1675–e1683, <https://doi.org/10.1212/WNL.0000000000009283>.
 [5] H.-J.-J. Lin, T.-Y.-Y. Hung, Y.-J.-J. Hsieh, J.-J.-J. Tsai, C.-W.-W. Huang, Spontaneous and stimulus-induced rhythmic periodic or ictal discharges (SIRPIDS) with rhythmic eye blinking and ocular dipping in a post-anoxic comatose patient: a case report, *Neurol. Sci.* 37 (2016) 2027–2030, <https://doi.org/10.1007/s10072-016-2677-8>.