



Clinical letter

A case of COVID-19 infection presenting with a seizure following severe brain edema

Yoshinori Kadono^{a,b,*}, Yusaku Nakamura^c, Yoshihiko Ogawa^d, Shota Yamamoto^{a,b},
Ryuichiro Kajikawa^b, Yoshikazu Nakajima^b, Masayasu Matsumoto^c, Haruhiko Kishima^a

^a Department of Neurosurgery, Osaka University Graduate School of Medicine, Suita, Japan

^b Department of Neurosurgery, Sakai City Medical Center, Sakai, Japan

^c Department of Neurology, Sakai City Medical Center, Sakai, Japan

^d Department of Infectious disease, Sakai City Medical Center, Sakai, Japan

ARTICLE INFO

Keywords:

Brain edema

Cerebral venous thrombosis

COVID-19

Coronavirus

Focal seizure

1. Introduction

The novel infection of coronavirus disease 2019 (COVID-19) caused by severe acute respiratory syndrome coronavirus 2 (SARS-CoV-2) began in December 2019 in China and is now widely spread worldwide. COVID-19 commonly presents with respiratory symptoms including cough and dyspnea. However, the neuroinvasive propensity through the angiotensin-converting enzyme 2 (ACE2) receptor [1], which is expressed in glial cells and neurons as well, and the cerebrovascular complication because of the hypercoagulable state are also reported as a feature of COVID-19 [2]. An immediate neurological care is important to minimize the mortality and morbidity of patients with convulsion and other neurological emergencies. An understanding of potential neurological manifestations in COVID-19 cases is crucial to care for patients and the protection of medical workers appropriately. We report a case of a patient presenting an acute symptomatic seizure with a recurrence of severe brain edema post cerebral venous thrombosis who was later found to have a COVID-19 infection.

2. Case presentation

In April 2020, a 44-year-old man was transferred to our emergency room for an intermittent twitch on the left hand and face. Six months previously, he had symptomatic epilepsy following cerebral venous thrombosis with acute hemorrhagic infarction because of nephrosis.

The venous thrombosis was involved the right sphenoparietal sinus and a right front-temporal decompression surgery was performed. After surgery, he was seizure-free with 1500 mg/day levetiracetam for five months. He also received anticoagulation therapy with warfarin (international normalized ratio [INR] range: 2.0–3.0) and a maintenance dose of 20 mg/day prednisone for nephrosis. Before admission, the last INR was 2.3. A week before admission, he felt bulging of a scalp flap. Two days before admission, he noticed the loss of smell. On the morning of the admission day, he had numbness in his left hand and face and called the ambulance. In the ambulance, his oxygen saturation was 97%, and his body temperature was 37.5 °C. Just after arrival, he had a seizure, starting from jerking of his left hand and then the entire body. The focal aware seizure lasted for a few minutes before the administration of 7.5 mg diazepam. A head computed tomography (CT) showed severe brain swelling of the right temporal lobe, which was injured by the previous hemorrhagic infarction, compared to the last CT (Fig. 1A and B). Brain magnetic resonance images did not show any acute cerebral infarction or any new vessel obstruction (Fig. 1D, E, and F). After the seizure, he claimed anosmia. A chest CT was scanned to rule out COVID-19, showing peripheral ground glass-like opacities in bilateral dorsal lungs (Fig. 1G and H). The laboratory analysis revealed a white blood cell count of 9,620 per microliter, lymphocyte percentage of 19.0%, platelet count of 188,000 per microliter, C-reactive protein of 2.97 mg/L, D-dimer of 200 ng/mL, and INR of 1.33 despite the anticoagulation therapy of 3 mg/day warfarin.

* Corresponding author at: Department of Neurosurgery, Osaka University Graduate School of Medicine, 2-2 Yamadaoka, Suita, Osaka 565-0871, Japan.

E-mail address: y-kadono@nsurg.med.osaka-u.ac.jp (Y. Kadono).

<https://doi.org/10.1016/j.seizure.2020.06.015>

Received 5 June 2020; Accepted 6 June 2020

1059-1311/ © 2020 British Epilepsy Association. Published by Elsevier Ltd. All rights reserved.

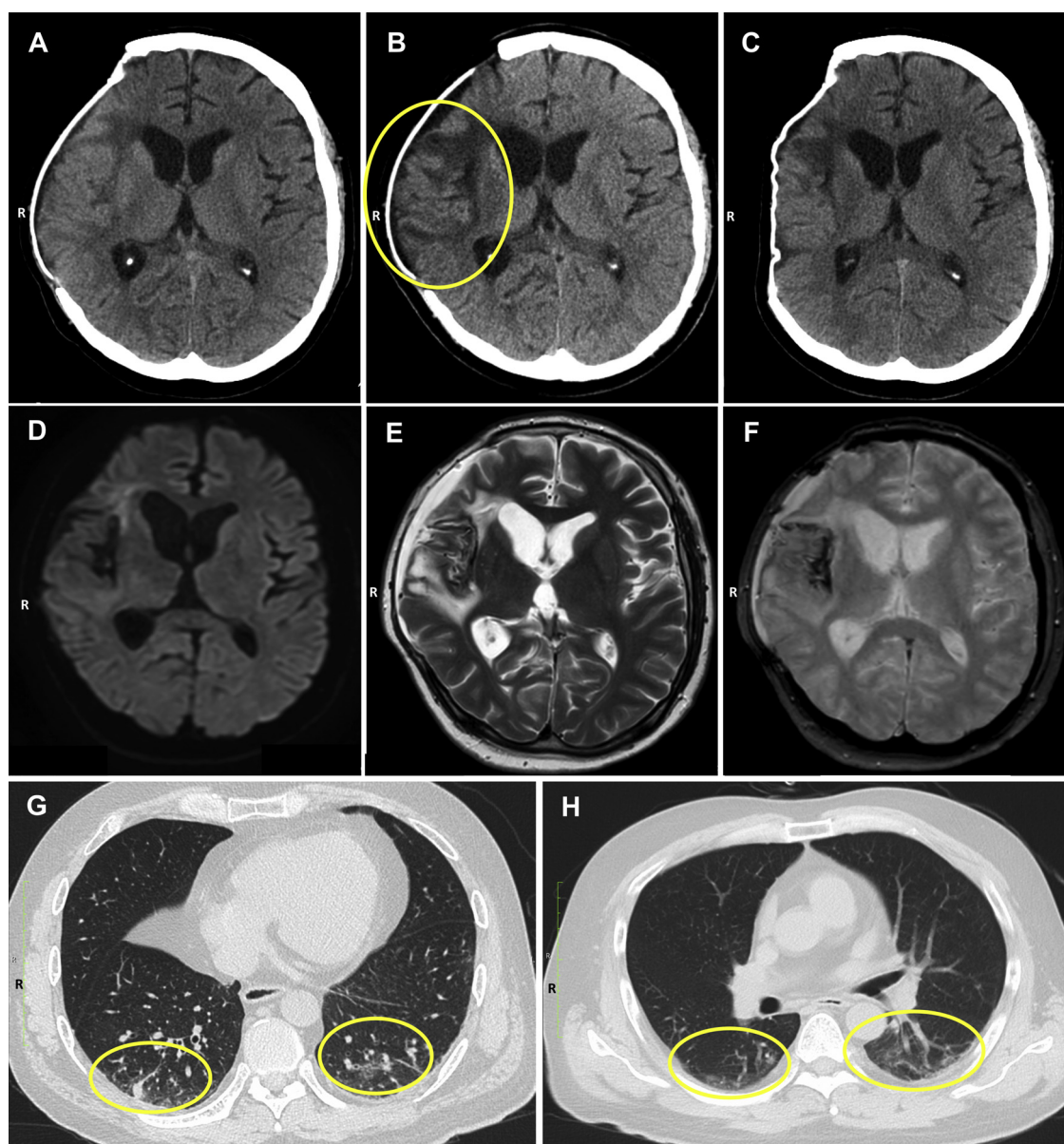


Fig. 1. Radiological findings.

The head Computed tomography (CT) two months before admission showing the previous right extra decompression surgery and less brain edema (A); The head CT on admission showing severe brain edema at the right temporal lobe beyond the skull line (B, circle). After discharge, the head CT showing the regression of brain edema within the skull line (C). Diffusion-weighted magnetic resonance image on admission showing no new infarction (D). A T2 and T2-star weighted magnetic resonance image showing severe brain edema and no new vessel obstruction (E and F). A chest CT scan on admission showing the peripheral ground glass-like opacities in bilateral dorsal lungs (G and H, circle).

The antiepileptic and anticoagulation therapies were strengthened with 2000 mg/day levetiracetam and 3.5 mg/day warfarin. The first day, he suffered from a fever of 38.5 °C and hypoxia and was started on oxygen therapy (up to 5 L/min of face mask oxygen). He had no contact with any patient positive for SARS-CoV-2. However, the characteristic anosmia and the glass-like shadows were adequate for suspicion of COVID-19. Thus, a real-time polymerase chain reaction assay (RT-PCR) was performed, which showed positive results for SARS-CoV-2. The patient was transferred to the COVID-19 unit and started on hydroxychloroquine (600 mg/day for the first day, 400 mg/day for nine days) along with azithromycin (500 mg/day for the first day, 250 mg/day for four days) and ciclesonide 400 µg/day. After initiation of the treatment, the clinical conditions of the patient improved, with the resolution of the fever in four days and the skin flap sinking day by day. The treatment prevented a seizure recurrence. On hospital day 13, a negative

report of RT-PCR for SARS-CoV-2 was obtained twice, then he was discharged. At discharge, the D-dimer level was normal, and INR was 4.1. The head CT two weeks after discharge showed improvement in the brain swelling (Fig. 1C).

3. Discussion

COVID-19 is a novel infection that became pandemic but the pathophysiology has been uncertain. Coronaviruses commonly have the pathogenic mechanisms of neuroinvasion through ACE2 receptor [1], which may be applicable for SARS-CoV-2. This may explain anosmia in COVID-19 [3]. Furthermore, COVID-19 may predispose the patient to a hypercoagulable state. In a study of Italy, although patients received standard thromboprophylaxis, the cumulative rate of venous thromboembolism was 21% in 388 patients with COVID-19 [2]. Although we

lack data on the cerebrospinal fluid of the patient, the anosmia and transient brain edema indicate a neurological invasion of COVID-19. A cerebrovascular event because of the hypercoagulable state of COVID-19 may also cause the recurrence of brain edema. Cerebral angiography and perfusion study were not performed; however, the magnetic resonance results do not show major vessel thrombosis. In this case, microcirculation might be disturbed in COVID-19 infection that could develop edema and lead to the seizure. Although data are lacking to verify the hypothesis, another case of COVID-19 presenting a post-encephalitic status epilepticus [4] and previous reports on the hypercoagulable and neuroinvasive features of COVID-19 support this. However, we believe that COVID-19 infection has a potential to develop brain edema and lead to the seizure in patients with post-stroke symptomatic epilepsy. Thus, we hope that this case report will increase the awareness of neurologists about epilepsy during a COVID-19 infection in emergent medicine and help in providing appropriate care to the patients.

Declaration of Competing Interest

The authors declare that they have no known competing financial interests or personal relationships that could have appeared to influence the work reported in this paper.

References

- [1] Li YC, Bai WZ, Hashikawa T. The neuroinvasive potential of SARS-CoV2 may play a role in the respiratory failure of COVID-19 patients. *J Med Virol* 2020;92(6):552–5. 01-Jun-2020. John Wiley and Sons Inc.
- [2] Bikdeli B, et al. COVID-19 and thrombotic or thromboembolic disease: implications for prevention, antithrombotic therapy, and follow-up. *J Am Coll Cardiol* 2020. NLM (Medline), 15 April.
- [3] Vaira LA, Salzano G, Fois AG, Piombino P, De Riu G. Potential pathogenesis of ageusia and anosmia in COVID-19 patients. *Int Forum Allergy Rhinol* 2020. NLM (Medline), 27 April.
- [4] Vollono C, et al. Focal status epilepticus as unique clinical feature of COVID-19: a case report. *Seizure* 2020;78(May):109–12.