

Early aortic repair and decompressive hemicraniectomy in aortic dissection with ischaemic stroke

Perfusion

1–5

© The Author(s) 2020

Article reuse guidelines:

sagepub.com/journals-permissions

DOI: 10.1177/0267659120932413

journals.sagepub.com/home/prf



Walid Mohamed,¹  Aneel Zaheer² and Ranjit Deshpande²

Abstract

The presence of stroke in patients with type A acute aortic dissection confers worse clinical outcomes and represents a therapeutic dilemma. While emergency surgical repair is the ideal management strategy, the risk of further cerebral insult is a cause of concern, especially in the elderly moribund patient, where delayed repair or a conservative approach may be considered. A 67-year-old female presented with chest pain and left-sided hemiparesis and was diagnosed with extensive type A acute aortic dissection and ischaemic stroke secondary to right common carotid artery stenosis. She underwent two major operations (emergency dissection repair and hemicraniectomy) and sustained several complications. Despite her eventful postoperative recovery, she was discharged after 6 weeks to a neurorehabilitation unit with a mild neurological deficit. Due to subsequent pulmonary complications, the patient died 5 weeks later. The present report appraises the current evidence on the management of patients with type A acute aortic dissection presenting with neurological sequelae.

Keywords

aortic dissection; stroke; repair; hemicraniectomy; complications

Introduction

Aortic dissection (AD) is a rare yet life-threatening condition with a mean annual incidence of 6 cases per 100,000 persons¹ and estimated mortality of 50% within the first 48 hours for untreated type A acute aortic dissection (TAAAD).²

AD commonly manifests with neurological involvement as the initial complication in up to 40% of cases. Ischaemic stroke is the most common initial neurological finding due to the extension of dissection into supra-aortic vessels.³ The neurological deficit in high-risk groups is further aggravated by operative management of their TAAAD which also carries the risk of cerebral reperfusion injury.⁴ Furthermore, managing ischaemic stroke with thrombolysis carries a significant risk of dissection extension into the pericardium and coronary origins or aortic rupture. Emergency repair of AD in patients with neurological manifestations represents an intervention dilemma. Ischaemic stroke was previously considered a contraindication to early surgical intervention^{5,6} with medical management of acute dissection with large established strokes (>4 hours onset) being a recommended management strategy.⁷ However, surgical

repair is associated with improved late survival and neurological function in such cases when compared with medical management.⁸ The present report discusses the management of a case with TAAAD complicated by ischaemic stroke and summarises the current evidence on different treatment strategies of this presentation.

Case report

A 67-year-old lady presented to her local hospital with a few hours' history of left-sided hemiparesis and chest pain. Her medical history included hypertension, hypercholesterolemia, obesity and stage-two chronic kidney disease. An initial chest radiograph showed a widened mediastinal shadow which raised the suspicion of AD. A chest and abdomen computed tomography angiography

¹Department of Cardiac Surgery, Glenfield Hospital, Leicester, UK

²Department of Cardiac Surgery, King's College Hospital, London, UK

Corresponding author:

Ranjit Deshpande, Department of Cardiac Surgery, King's College Hospital, Denmark Hill, London, SE5 9RS, UK.

E-mail: ranjit.deshpande@nhs.net

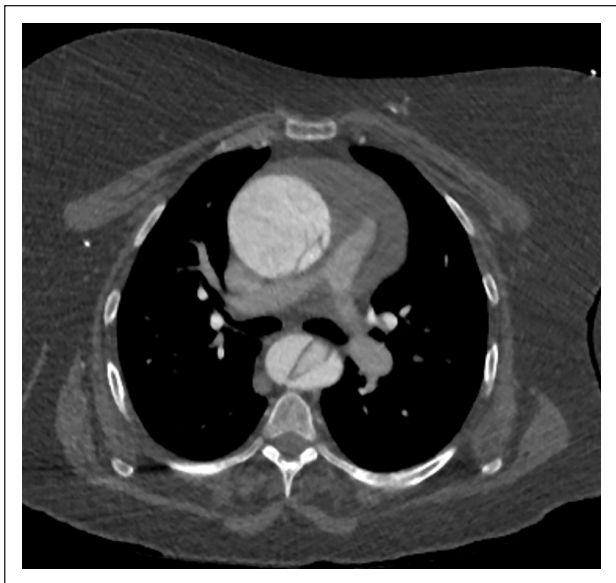


Figure 1. CTA axial section showing extension of the dissection to involve both ascending and descending aorta.

(CTA) (Figures 1-2) revealed extensive TAAAD involving the aortic root, with a pericardial haematoma and extension to the supra-aortic vessels. There was also compromise of the coeliac axis and both renal arteries with left renal infarcts. Head CTA showed right common carotid artery (CCA) stenosis due to a crescentic thrombus with tandem right middle cerebral artery (MCA) and internal carotid artery (ICA) emboli. No evidence of parenchymal infarct was identified at that point. The left CCA, subclavian artery and the brachiocephalic trunk were mostly fed by the false lumen. The patient's National Institutes of Health Stroke Scale (NIHSS) score was 17.

The patient was immediately transferred to our hospital where she underwent an overnight emergency aortic root and hemi-arch replacement with a hemoshield graft. She was then transferred to the coronary care unit and started on 300 mg of aspirin after stroke team review. At that point, her left hemiparesis had not worsened. Her electrocardiogram showed rate-controlled atrial fibrillation and she also started to develop acute kidney injury (AKI) secondary to the bilateral renal artery stenosis, which was conservatively managed. On the first postoperative day, she was extubated and reviewed again by the stroke team who noted dense left hemiplegia. A repeat head CT was obtained, which showed a right-sided malignant MCA infarct with mass effect but no haemorrhage (Figure 3). She underwent an overnight emergency right decompressive hemicraniectomy later that day and was then transferred postoperatively to intensive treatment unit for further monitoring. Over the next few weeks her AKI and inflammatory markers improved. However, 3 weeks postoperative and while

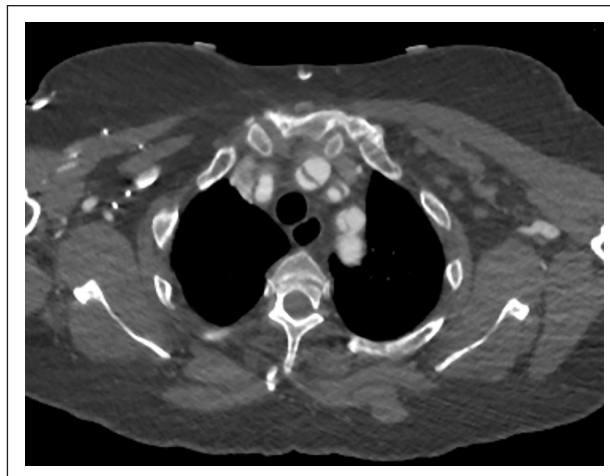


Figure 2. CTA axial section showing extension of the dissection flap to involve the common carotid artery, leading to the right MCA infarct due to occlusion of the right common carotid artery.

on heparin and clopidogrel, she developed evidence of acute haemorrhage in her established parieto-occipital infarct with intraventricular extension. This was conservatively managed and remained stable on a head CT performed 48 hours later (Figure 4).

The patient recovered slowly in-hospital with an improvement in neurological function and only a mild residual left-sided hemiparesis prior to her transfer to a neurorehabilitation ward at her local hospital. She was transferred with no anticoagulation treatment after taking into consideration her haemorrhagic stroke and risk of future bleeding. The length of her in-hospital stay from the time of presentation was 6 weeks. Unfortunately, she later developed pulmonary embolism while on the rehabilitation ward and died shortly afterwards.

Discussion

The present case highlights the complexities in managing patients presenting with TAAAD and neurological involvement, who are often old and multimorbid and require timely intervention. Despite the inherent risk of mortality associated with TAAAD, which was heightened in our case as evidenced by her mortality risk score (EuroSCORE II = 13.38%),⁹ the patient survived the aortic valve and root replacement and then underwent a second major operation within 2 days for a potentially fatal complication (decompressive hemicraniectomy reduces 6-month mortality from malignant middle cerebral artery infarction (MMCAI) from 71.2% to 48.3% in elderly patients).¹⁰

There is a variation in surgeons' preference with regard to the optimal management strategy of TAAAD

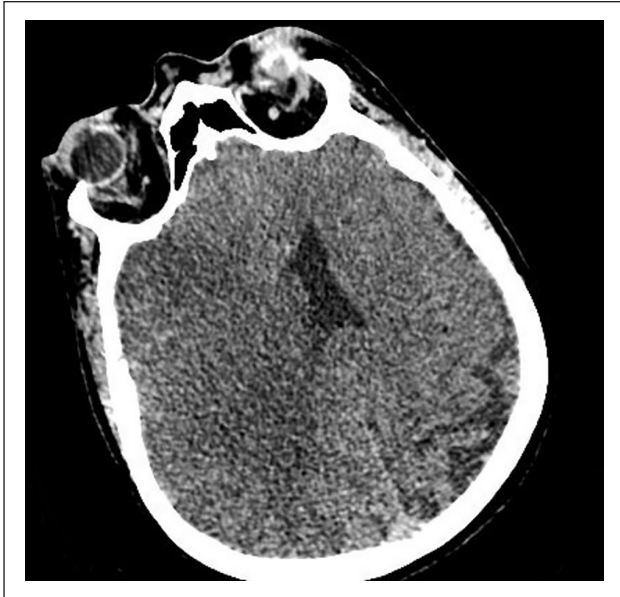

Figure 3. Head CT axial section with malignant MCA infarct but no mass effect.

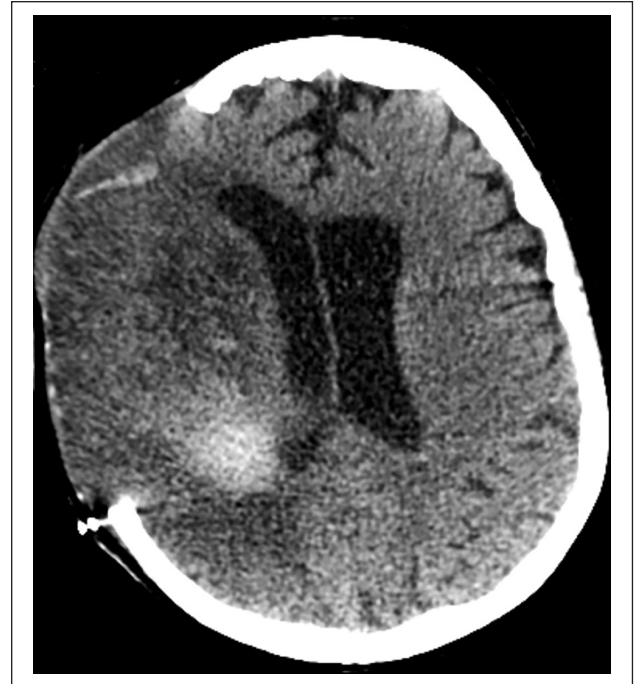

Figure 4. Head CTA axial section showing haemorrhagic transformation in the established infarct.

with neurological involvement. Although the high risk of mortality associated with a conservative approach is well recognised, the risk of mortality and complications as a result of intervention may potentially outweigh its benefits. Therefore, a risk-based approach that takes into account both surgeons' and patients' preferences is strongly recommended. In the case reported, a decision was made to immediately repair the AD as a potentially life-saving measure. However, other strategies may have been adopted at that stage, including delayed surgical repair and medical or conservative management.

The evidence on optimal timing of surgery in TAAAD (early vs. delayed surgical repair) complicated by ischaemic stroke is inconsistent. Although some studies have regarded cerebral ischaemia or stroke as a contraindication to immediate repair,^{5,6} Fann et al. reported lower operative mortality (14%) with immediate surgical repair in seven patients who presented with AD and stroke as compared with overall mortality (25%) in 272 patients who presented with AD and peripheral vascular complications.¹¹ This was reiterated by Estrera et al. who concluded that early surgical repair of TAAAD can be performed safely in the setting of preoperative stroke and that neurologic function does not worsen with subsequent full anticoagulation.⁴ However, no randomised studies of medical versus surgical management have been performed.¹² One review advocates immediate surgical repair in TAAAD patients with evolving stroke and medical management for those with a sizable or established stroke (4 hours or more since onset) because of the risk of heparin-induced intraoperative haemorrhagic infarcts.⁷

As with type B dissection, medical therapy is part of initial TAAAD management. However, definitive medical management of TAAAD is still an option in TAAAD presenting with stroke and delayed diagnosis, advanced age, significant comorbidities, or previous aortic valve replacement. Scholl et al.¹³ investigated 75 patients with TAAAD and reported no difference in short-term survival between 34 patients who underwent delayed surgery or medical treatment only and 41 patients who underwent immediate repair ($p=0.42$).

Whether medical management would have been more suitable for our case is a matter of debate. The postoperative complication of MMCAI could be used as a counterargument for conservative rather than operative management. A review of the International Registry of Aortic Dissection (IRAD) in 2013 compared hospital and 5-year survival in TAAAD patients presenting with cerebrovascular accident (CVA) and coma who underwent surgery versus medical management. It concluded that patients who were operated on showed improved late survival and frequent improvement of neurologic function.⁸ Although the patient in our report had symptoms of stroke for more than 4 hours and a significant operative mortality risk, this was not above the 58% mortality risk above which medical and surgical management achieve equal outcomes as suggested by Centofanti et al.¹⁴ in their analysis of the IRAD database, and the operation was deemed a life-saving measure.

Despite the significant risk, AD is not an absolute contraindication to thrombolysis.¹⁵ There are isolated case reports of patients undergoing thrombolysis for ischaemic stroke followed by emergency AD repair for a previously undiagnosed TAAAD with some of the surviving patients having acceptable neurological outcomes.¹⁶ However, in the present report, the patient presented after the currently recommended windows of 3 hours for thrombolysis and 5 hours for mechanical thrombectomy¹⁷ and aortic dissection repair took priority as a life-saving emergency procedure. Conservative management of her ischaemic stroke with aspirin was initiated immediately postoperative.

Decompressive hemicraniectomy (DH) is another aspect of the debate. MMCAI is a life-threatening condition characterised by neurological decline due to space-occupying cerebral oedema following MCA territory infarcts. Treatment is directed towards limiting oedema by medications and surgical decompression.¹⁸ A pooled analysis of 93 DH patients from three European multicentre randomised controlled trials (RCTs) published in 2007 showed that DH undertaken within 48 hours of stroke onset had a 1-year survival of 78% compared with 29% with medical management. DH was found to be associated with favourable functional outcome; however, the authors concluded that decompressive surgery should be considered on an individual basis in every patient.¹⁹ The debate around DH is due to the significant disability associated with survival, and a review of seven RCTs published on DH for MMCAI suggested an argument can be made for not performing DH in patients over 60 years old due to poor outcomes.²⁰

Conclusion

Our case highlights the challenges faced when managing patients with TAAAD complicated by stroke, and the gaps in current evidence to support surgeons' decision making. It raises the question of whether early repair of TAAAD presenting with established stroke is feasible, owing to the major neurovascular complications and mortality which may arise postoperatively. Despite the encouraging in-hospital survival after extensive multidisciplinary involvement, delayed complications as the cause of mortality may be used as an argument for medical management. A careful risk-benefit analysis of any intervention in this high-risk group is imperative, as is the need for further research on the optimal management strategy of this presentation.

Consent

Waiver of consent to publish this case report was obtained from legal services at King's College Hospital since the patient is deceased and despite several attempts we have been unable to get in contact with the patient's family members or

immediate next of kin to obtain consent waiver. No identifiable information is included in this article.

Declaration of Conflicting Interests

The author(s) declared no potential conflicts of interest with respect to the research, authorship, and/or publication of this article.

Funding

The author(s) received no financial support for the research, authorship, and/or publication of this article.

ORCID iD

Walid Mohamed  <https://orcid.org/0000-0003-2747-3900>

References

1. Howard DPJ, Sideso E, Handa A, et al. Incidence, risk factors, outcome and projected future burden of acute aortic dissection. *Ann Cardiothorac Surg* 2014; 3: 278–284.
2. Erbel R, Aboyans V, Boileau C, et al. 2014 ESC Guidelines on the diagnosis and treatment of aortic diseases: document covering acute and chronic aortic diseases of the thoracic and abdominal aorta of the adult. The task force for the diagnosis and treatment of aortic diseases of the European Society of Cardiology (ESC). *Eur Heart J* 2014; 35: 2873–2926.
3. Gaul C, Dietrich W, Friedrich I, et al. Neurological symptoms in type A aortic dissections. *Stroke* 2007; 38: 292–297.
4. Estrera AL, Garami Z, Miller CC, et al. Acute type A aortic dissection complicated by stroke: can immediate repair be performed safely. *J Thorac Cardiovasc Surg* 2006; 132: 1404–1408.
5. Cambria RP, Brewster DC, Gertler J, et al. Vascular complications associated with spontaneous aortic dissection. *J Vasc Surg* 1988; 7: 199–209.
6. Ergin MA, Galla JD, Lansman S, et al. Acute dissections of the aorta: current surgical treatment. *Surg Clin North Am* 1985; 65: 721–741.
7. Feldman M, Shah M, Elefteriades JA. Medical management of acute type A aortic dissection. *Ann Thorac Cardiovasc Surg* 2009; 15: 286–293.
8. Di Eusanio M, Patel HJ, Nienaber CA, et al. Patients with type A acute aortic dissection presenting with major brain injury: should we operate on them. *J Thorac Cardiovasc Surg* 2013; 145: S213–s221.
9. Roques F, Michel P, Goldstone AR, et al. The logistic EuroSCORE. *Eur Heart J* 2003; 24: 881–882.
10. Yu JW, Choi JH, Kim DH, et al. Outcome following decompressive craniectomy for malignant middle cerebral artery infarction in patients older than 70 years old. *J Cerebrovasc Endovasc Neurosurg* 2012; 14: 65–74.
11. Fann JI, Sarris GE, Mitchell RS, et al. Treatment of patients with aortic dissection presenting with peripheral vascular complications. *Ann Surg* 1990; 212: 705–713.
12. Bonser RS, Ranasinghe AM, Loubani M, et al. Evidence, lack of evidence, controversy, and debate in the provision

- and performance of the surgery of acute type A aortic dissection. *J Am Coll Cardiol* 2011; 58: 2455–2474.
13. Scholl FG, Coady MA, Davies R, et al. Interval or permanent nonoperative management of acute type A aortic dissection. *Arch Surg* 1999; 134: 402–405.
 14. Centofanti P, Flocco R, Ceresa F, et al. Is surgery always mandatory for type A aortic dissection. *Ann Thorac Surg* 2006; 82: 1658–1663.
 15. Fugate JE, Rabinstein AA. Absolute and relative contraindications to IV rt-PA for acute ischemic stroke. *Neurohospitalist* 2015; 5: 110–121.
 16. Pilato F, Iodice F, Distefano M, et al. Aortic dissection in the thrombolysis era: rare but potentially fatal cause of stroke. *Neurol India* 2017; 65: 1395–1399.
 17. Rudd AG, Bowen A, Young GR, et al. The latest national clinical guideline for stroke. *Clin Med (Lond)* 2017; 17: 154–155.
 18. Treadwell SD, Thanvi B. Malignant middle cerebral artery (MCA) infarction: pathophysiology, diagnosis and management. *Postgrad Med J* 2010; 86: 235–242.
 19. Vahedi K, Hofmeijer J, Juettler E, et al. Early decompressive surgery in malignant infarction of the middle cerebral artery: a pooled analysis of three randomised controlled trials. *Lancet Neurol* 2007; 6: 215–222.
 20. Hatefi D, Hirshman B, Leys D, et al. Hemicraniectomy in the management of malignant middle cerebral artery infarction: lessons from randomized, controlled trials. *Surg Neurol Int* 2014; 5: 72.