

NOTE

CROSSED APHASIA: FUNCTIONAL STUDIES WITH SINGLE PHOTON EMISSION COMPUTERIZED TOMOGRAPHY

Daniela Perani¹, Costanza Papagno², Stefano Cappa³, Paolo Gerundini¹ and Ferruccio Fazio¹

(From the ¹Department of Biomedical Technologies, S. Raffaele Hospital, University of Milan, ²Department of Neurology, Policlinico Hospital, University of Milan, and ³Department of Neurology, Niguarda Hospital, Milan)

Crossed aphasia, i.e. aphasia resulting from hemispheric lesions ipsilateral to the dominant hand, is an exceptional syndrome among right handed subjects. If strict selection criteria are adopted, few cases of crossed aphasia in dextrals are reported in literature. These reports describe the correlation between language disturbances and locus of the brain lesions as assessed by autopsy or CT scan (Joannette, Puel, Nespoulous, Rascol and Lecours, 1982; Basso, Capitani, Laiacona and Zanobio, 1985). This paper describes two right handed patients with language disturbances after right hemispheric stroke who underwent regional cerebral blood flow (rCBF) studies by single photon emission computerized tomography (SPECT). A relationship between presence and severity of aphasia, and decrease of rCBF in right cortical and subcortical structures was demonstrated together with a normalization of cerebral perfusion paralleling the clinical recovery in one case.

CASE REPORTS

Case 1

History

A 69 year old male, with 8 years of schooling, was admitted a few hours after the sudden onset of left hemiparesis and aphasia. Past medical history revealed mild treated hypertension. B.P. was 180/100. The patient had no history of any previous neurological disorder. The neurological examination showed that the patient was alert and cooperative. Cranial nerves examination showed intact visual fields on confrontation and left supra-nuclear facial palsy. There was left hemiparesis with increased deep tendon reflexes and a Babinski response on that side. Neuropsychological evaluation revealed a conduction aphasia, but no signs of unilateral neglect and apraxia. On the Edinburgh Inventory Test (Oldfield, 1971) the patient's right handedness score was + 100. No left handedness was reported in siblings and parents. Computed tomography (CT) of the brain performed on the day of admission did not reveal abnormalities in the supratentorial and cerebellar structures. A diagnosis of an early phase of stroke with negative CT scan was done. The patient recovered completely within a few days and on a control language examination, 1

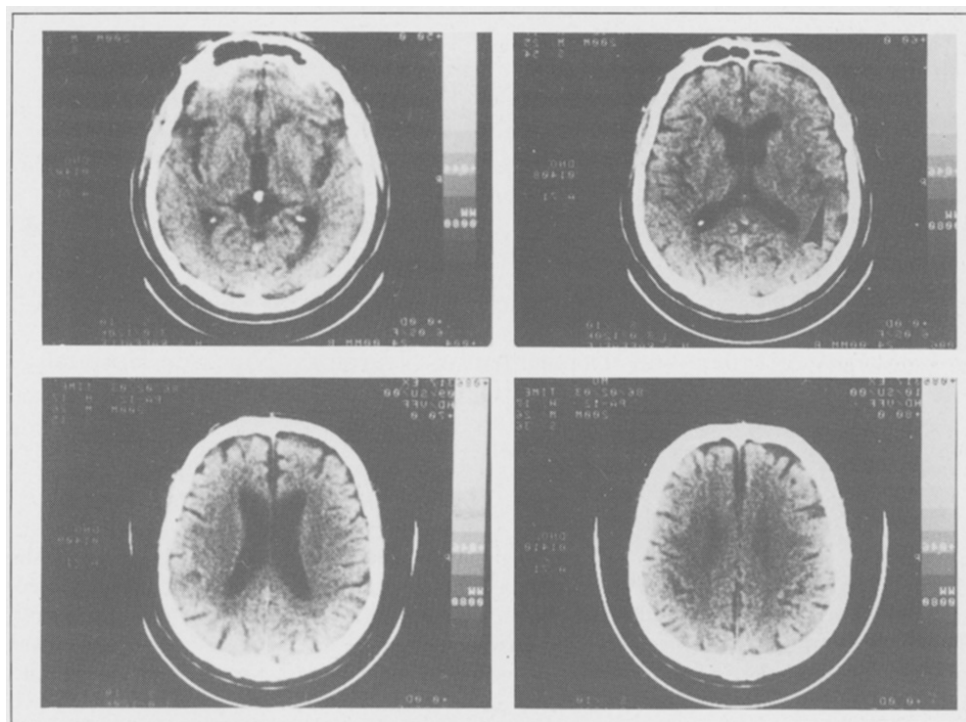


Fig. 1 (a) — Case 1, CT scan: small hypodense lesion in the right insula (arrow).

week after admission, all the patient's performances were within the normal range. A second CT scan revealed a small hypodense ischemic lesion deeply located in the right insula (Figure 1a). SPECT perfusion studies were performed in the acute and subacute phase, within 24 hours and 6 days after the onset of stroke and again in the chronic phase, 5 weeks after.

Neuropsychological Examination

The patient was evaluated on the day of admission with a shortened form of the Standard Language Examination of the Aphasia Unit of the University of Milan (Basso, Capitani and Vignolo, 1979). On oral description, the speech was fluent with frequent phonemic paraphasias. Articulation was mildly dysarthric, due to facial paresis. In a naming task phonemic paraphasias were present. Auditory comprehension was normal in conversation. Sentence comprehension was mildly impaired (Token Test: 27/36). The comprehension of written stimuli (words, sentences) was well preserved. Repetition and reading aloud of real words and sentences were performed slowly and interrupted by pauses. There were frequent phonemic and verbal paraphasias. Repeating non-sense syllables was characterized by phonemic paraphasias. Spontaneous written expression was reduced, with rare verbal paraphasias. Copying letters and words as well as dictation were fairly well preserved. No bucco-linguo-facial, ideomotor and constructional apraxias were demonstrated. The patient did not show signs of unilateral neglect: on cancellation task there were no omissions in crossing out left and right circles (Bisiach, Luzzatti and Perani, 1979). Spontaneous drawing and copy were normal. The patient was a professional

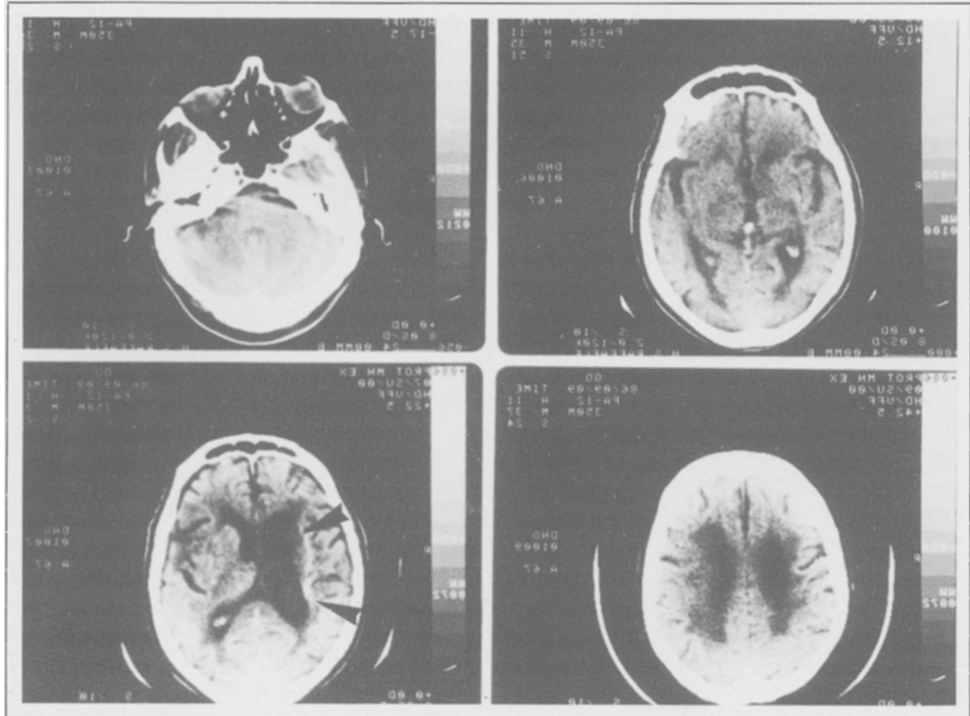
painter, and was able to produce complex drawings (self portraits, landscapes, etc.). He was aware of the language deficits and motor impairment.

Case 2

History

A 67 years old right handed man, with 5 years of schooling, had suffered in March 1983 a right intracerebral hematoma involving the basal ganglia and centrum semiovale. On neurological examination there was a left hemiplegia, with right gaze deviation and aphasia. He never recovered and, on September 1986, three years after the stroke, the patient was submitted to a control CT scan and neurological examination in order to plan a rCBF assessment by SPECT. He still showed left hemiplegia with hyperreflexia and aphasia. A neuropsychological evaluation revealed a mixed transcortical aphasia and bucco-facial and limb apraxia. There was no family history of left handedness, CT scan showed a right ventricular enlargement and a large right hypodense area in the right hemisphere, unchanged after contrast injection, involving basal ganglia, internal capsule and thalamus (Figure 1b). On the same day of the CT scan, the patient underwent a SPECT perfusion study.

Fig.1 (b) — Case 2, CT scan: ventricular enlargement and subcortical hypodense lesion in the right hemisphere (residual of hematoma).



Neuropsychological Examination

The patient was given the Standard Language Examination of the Aphasia Unit of the University of Milan (Basso et al., 1979).

Description of an event was poor: the patient, asked how to shave, produced strings of unrelated words (verbal jargon), mainly days of the week and animal names, often uttered stereotyped conventional expression and tended to sing popular themes spontaneously. Picture naming was 30% correct: errors were mainly anomias and semantic paraphasias. He was not able to produce automatic sequences.

Auditory comprehension was severely impaired: he pointed correctly only to one stimulus item out of 20, with a marked tendency to repeat iteratively the given name. He responded correctly to 50% of verbal commands. Token Test score was 12/36. On repetition tasks, he reproduced correctly 80% of the letters and syllables, 45% of words, 10% of non-words and 20% of sentences. He was able to perform his signature, but refused the other written language tasks.

The patient showed also bucco-facial apraxia (7/20), ideomotor apraxia (21/72) and constructional apraxia (see Basso et al., 1985, for test description).

No unilateral neglect was detected on cancellation task and drawing. The patient was aware of his aphasia and left hemiplegia.

rCBF Tomographic Assessment

Regional cerebral blood flow (rCBF) was assessed by SPECT about 10 minutes after i.v. injection of 20 mCi of Tc 99m HM-PAO (Leonard, Nowotnik and Neirinckx, 1986), using a rotating gamma camera and a dedicated computer.

All SPECT data were reconstructed obtaining a complete set of axial tomographic slices, 2 pixels thick (1.2 cm).

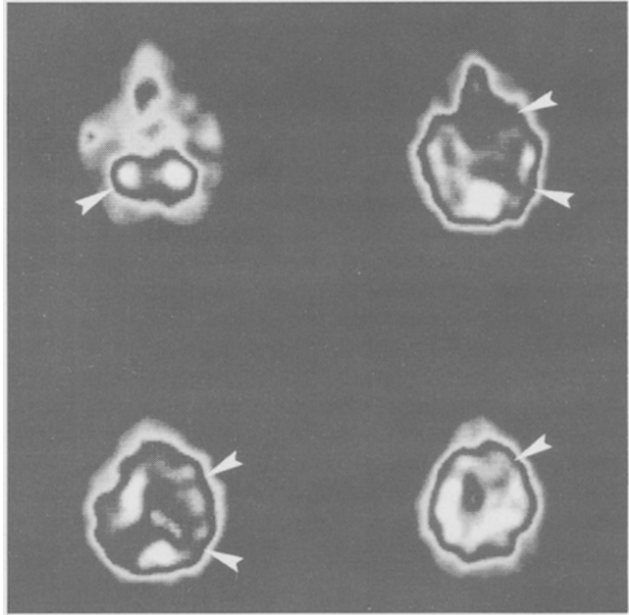
Regions of interest (ROIs), 4×4 pixels large, were symmetrically located on each cerebral hemispheric slice, both on right and left cortical and subcortical structures, as well as at the cerebellar level. A semiquantitative assessment of rCBF was performed determining the left to right ratio of counts for each pair of symmetrical ROIs in the two hemispheres. Values outside the normal range (i.e. 2SD below the control values: 1.00 ± 0.05) were used to define the degree of cerebral hypoperfusion.

RESULTS

In case 1 the first SPECT study performed within 24 hours from the onset of neurological and neuropsychological symptoms, when the CT scan was still negative, showed a significant asymmetry of perfusion between left and right middle cerebral artery territories, with the right side decreased by 22%; a reduction of rCBF was also demonstrated in the right thalamus, which appeared decreased by 28% with respect to the left, and in the left cerebellar hemisphere, with 18% reduction compared to the right one (Figure 2a). At the second SPECT examination performed one week after, when recovery of aphasia was complete, no asymmetry of perfusion between left and right hemisphere was shown either at cortical or subcortical level (Figure 2b). At that time a small insular infarct was present on CT scan. These findings were confirmed at CT control and SPECT study 5 weeks later.

In case 2, examined in the chronic stage with persistent neuropsychological deficits, the

Fig. 2 (a) — Case 1, SPECT in acute phase: presence of crossed cerebellar diaschisis and reduced perfusion in temporo-parietal cortical areas and thalamus in the right hemisphere (arrows).



SPECT study demonstrated a severe reduction of perfusion in the right hemisphere. The hypoperfusion involved the CT-hypodense subcortical structures as well as cortical areas which appeared unaffected on CT scan. In fact, rCBF values were reduced by 37% in right temporal and parietal cortex as well as by 20% in right frontal regions with respect to the contralateral side; an asymmetry of perfusion was also detected in the cerebellar hemispheres, with the left side decreased by 38% (Figure 2c).

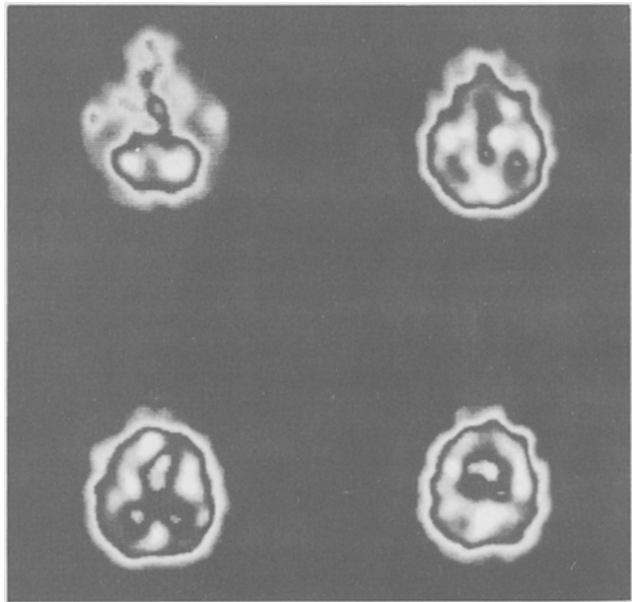


Fig. 2 (b) — Case 1, follow-up SPECT study (1 month after stroke): no asymmetry of perfusion both at cerebellar and supratentorial level.

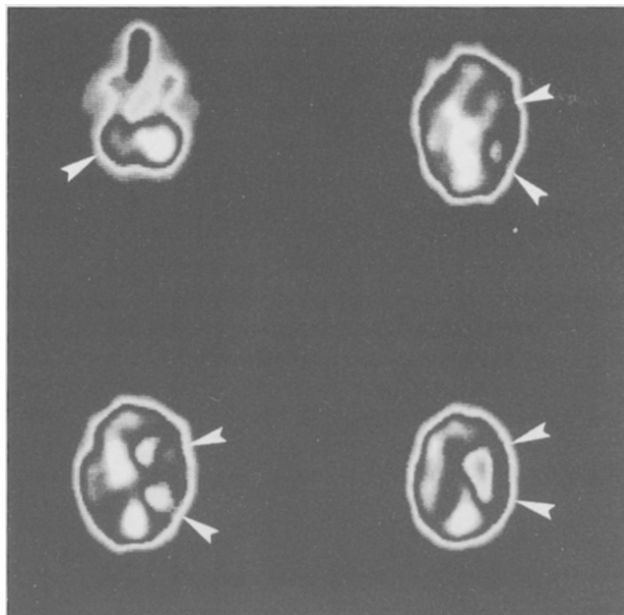


Fig. 2 (c) — Case 2, SPECT study in chronic stage: severe cortical and subcortical hypoperfusion in the right hemisphere (arrows).

DISCUSSION

Our findings indicate that rCBF assessment by SPECT can add important functional information for evaluating patients with cognitive deficits. In the two cases of crossed aphasia reported here, the perfusion condition of the right hemisphere explained the neuropsychological symptoms better than the CT scan data per se. In fact, the hypoperfusion of the right hemisphere involving temporo-parietal cortical areas as well as the thalamus in case 1, was the only functional correlate of the mild conduction aphasia in the acute stage, a small lesion of the right insula being apparent on the second CT scan when the patient had recovered completely. In case 2 the CT-assessed lesion was confined to the right subcortical structures, while the overlying cortical areas, normal on CT, showed on SPECT study a major functional derangement which can be related to the neuropsychological deficits. Aphasia is frequent after left subcortical cerebrovascular lesions (see Crosson, 1985, for a review) and has also been reported after right subcortical stroke lesions in right handed subjects (Carr, Jacobson and Boller, 1981; Habib, Joannette, Ali-Cherif and Poncet, 1983). In case 2 a subcortical lesion was associated with a profound cortical hypofunction which must be taken into account in order to explain both the presence and the persistence of severe cognitive disturbances. In fact, a coupled reduction of blood flow and metabolism, reflecting a functional impairment, has been demonstrated by PET studies in cortical areas overlying subcortical lesions (Powers and Raichle, 1985). Such cortical remote effects, attributed to a deafferentation process, seem to be related to the presence of cognitive deficits (Metter, Jackson, Kempler, Riege, Hanson, Mazziotta and Phelps, 1986; Perani, Vallar, Cappa, Messa and Fazio, 1987). In case 1, the mild language disturbances were associated with a minor degree of right hemispheric hypoperfusion and the good recovery was matched with the normalization of cerebral blood flow. In the acute stage, in the presence of language disturbances, a functional involvement of right thalamus was also observed: a close thalamo-cortical interaction has been shown

in aphasic patients by Positron Emission Tomography (Metter, Wasterlain, Kuhl, Hanson and Phelps, 1981).

As for the aphasic syndromes presented by our patients, they do not differ from those found in left hemisphere brain damaged patients with similar lesions. In fact aphasia with transcortical features has been reported for thalamic and basal ganglia lesions and conduction aphasia can be observed for lesions located in the upper bank of the sylvian fissure (Benson, 1979). Henderson (1981) has found that the correlation between clinical syndromes and infarct localization is similar to left hemisphere lesion, a finding confirmed by Basso et al. (1985).

Our patients did not show unilateral neglect or constructional impairment which have also been demonstrated in cases of crossed aphasia (see Basso et al., 1985). However hemispheric damage was minor in case 1 and case 2 was examined only in the chronic stage.

Apraxias are usually reported for lesions in the left hemisphere, also involving subcortical structures (De Renzi, Faglioni, Scarpa and Crisi, 1986). Several cases of "crossed apraxia" however have been reported in association with aphasia after right hemispheric lesions (see Basso et al., 1985). In case 2 presenting with a chronic subcortical lesion in association with a massive reduction of right cortical perfusion severe bucco-facial and ideomotor apraxias were found, suggesting possibly the role of cortical dysfunction in the genesis of this long-lasting apraxia.

Our rCBF studies, showing a functional involvement of right hemispheric structures, far beyond the anatomical lesion demonstrated by CT, give further evidence supporting the relationship between a selective dysfunction of the right hemisphere and appearance of crossed aphasia.

ABSTRACT

The correlation between clinical picture, CT scan and regional cerebral blood flow (rCBF) assessed by single photon emission computerized tomography (SPECT) was investigated in two patients with crossed aphasia. The presence and degree of right hemisphere dysfunction, beyond the areas affected by CT, closely paralleled the time course of language disturbances in both patients: transient aphasia in case 1 was associated with temporary reduction of perfusion in the right hemisphere, while in case 2 persistent aphasia and apraxia were found along with severe right hemisphere hypoperfusion three years after the onset of stroke.

Acknowledgements. This research was supported in part by C.N.R. grant. The authors are indebted to Prof. G.L. Lenzi for suggestions and criticisms.

REFERENCES

- BASSO, A., CAPITANI, E., and VIGNOLO, L.A. Influence of rehabilitation on language skills in aphasic patients. *Archives of Neurology*, 36: 190-196, 1979.
- BASSO, A., CAPITANI, E., LAIACONA, M., and ZANOBI, M.E. Crossed aphasia: one or more syndromes? *Cortex*, 21: 25-45, 1985.
- BENSON, BENSON D.F. *Aphasia, Alexia, Agraphia*. New York: Churchill Livingstone, 1979.
- BISIACH, E., LUZZATTI, C., and PERANI, D. Unilateral neglect, representational schema and consciousness. *Brain*, 102: 609-618, 1979.
- CARR, M.S., JACOBSON, T., and BOLLER, F. Crossed aphasia: analysis of four cases. *Brain and Language*, 14: 190-202, 1981.

- CROSSON, B. Subcortical functions in language: a working model. *Brain and Language*, 25: 257-292, 1985.
- DE RENZI, E., FAGLIONI, P., SCARPA, M., and CRISI, G. Limb apraxia in patients with damage confined to the left basal ganglia and thalamus. *Journal of Neurology, Neurosurgery and Psychiatry*, 49: 1030-1038, 1986.
- HABIB, M., JOANNETTE, Y., ALI-CHERIF, A., and PONCET, M. Crossed aphasia in dextrals: a case report with special reference to site of lesion. *Neuropsychologia*, 41: 413-418, 1983.
- HENDERSON, V.W. Speech fluency in crossed aphasia. *Brain*, 106: 837-857, 1983.
- JOANNETTE, Y., PUEL, M., NESPOULOUS, J.L., RASCOL, A., and LECOURS, A.R. Aphasie croisée chez les droitiers. I. Revue de la littérature. *Revue Neurologique (Paris)*, 138: 575-586, 1982.
- LEONARD, J.P., NOWOTNIK, D.P., and NEIRINCKX, R.D. Technetium-99m-d, 1-HM-PAO: a new radiopharmaceutical for imaging regional brain perfusion using SPECT. *The Journal of Nuclear Medicine*, 12: 1819-1823, 1986.
- METTER, E.J., WASTERLAIN, C.G., KUHL, D.E., HANSON, W.R., and PHELPS, M.E. 18-FDG positron emission computed tomography in a study of aphasia. *Annals of Neurology*, 10: 173-183, 1981.
- METTER, E.J., JACKSON, C., KEMPLER, D., RIEGE, W.H., HANSON, W.R., MAZZIOTTA, J.C., and PHELPS, M.E. Left hemisphere intracerebral hemorrhages studied by (F-18)-fluorodeoxyglucose PET. *Neurology*, 36: 1155-1162, 1986.
- OLDFIELD, R.C. The assessment and analysis of handedness: the Edinburgh Inventory. *Neuropsychologia*, 9: 97-113, 1971.
- PERANI, D., VALLAR, G., CAPPÀ, S., MESSA, C., and FAZIO, F. Aphasia and neglect after subcortical stroke. A clinical/cerebral perfusion correlation study. *Brain*, 110, 1211-1229, 1987.
- POWERS, W.J., and RAICHEL, M.E. Positron Emission Tomography and its application to the study of cerebrovascular disease in man. *Stroke*, 3: 361-376, 1985.
- YARNELL, P.R. Crossed dextral aphasia: a clinical radiological correlation. *Brain and Language*, 12: 128-139, 1981.

Dr. Daniela Perani, Department of Biomedical Technologies, University of Milan, Istituto S. Raffaele, Via Olgettina 60, 20132 Milano, Italy.