



The use of WhatsApp Messenger: an important tool in modern neurological examination

Iris H. M. Meeuwis¹ · Emma M. van Rooijen¹ · Wim I. M. Verhagen¹

Received: 23 April 2020 / Accepted: 3 July 2020
© Belgian Neurological Society 2020

Abstract

WhatsApp Messenger is one of the most popular and still growing mobile applications worldwide in telemedicine. WhatsApp Messenger can be used as a communication tool and an adjunctive tool within telemedicine, but it is the ability or inability to use WhatsApp Messenger correctly that provides a powerful clinical neurological function tool. The easy use and the application's popularity make it extremely useful in obtaining clues in patients' neurological history. Dystextia or dystypia, the inability to send correct text messages, can be used as an indicator of neurological deficits, and is an upcoming term in neurological vascular pathology. In this case series, we present three cases in which the inability to send text messages were the clue for neurological pathology. This easy and useful evaluation of the ability to use a text message program should be incorporated in standard neurological history taking and examination, as it can provide clues for underlying neurological pathology.

Keywords WhatsApp Messenger · Neurological history · Neurological examination · Dystextia · Dystypia · Stroke

Introduction

The use of mobile technologies and mobile phones is a feature of twenty-first century daily life. Using mobile phones or mobile technology for exchanging texts and data like audio, video or images with patients or other health care professionals, is known as telemedicine [1].

In countries like India, Brazil and certain European countries, such as The Netherlands, one of the most popular mobile applications in telemedicine is WhatsApp Messenger. This app, started as an alternative for texting by Short Messaging Service (SMS), is a communication tool that allows users to send different types of data like images, videos, and voice messages [1]. The app has been downloaded

in over 180 countries, and it has over one billion users with no exception among physicians [2, 3].

Telemedicine by mobile applications is gradually becoming a natural part of everyday hospital care and extramural care. Searching WhatsApp Messenger in PubMed, increasingly more studies become available that describe the use of WhatsApp Messenger in general health care, including the field of neurology. For example, a preliminary study was recently published about using WhatsApp Messenger as a neurosurgical referral service [4], or as a communication and clinical discussion tool in stroke systems of care [3]. Terms like “telestroke” in recent scientific literature prove the importance of telemedicine in current neurological health care [5].

Besides the familiar functions and use of WhatsApp in telemedicine, the use of WhatsApp Messenger might be of significant importance in another way. The relatively easy use and popularity of the app worldwide makes WhatsApp extremely useful in obtaining clues in patients' neurological history and examination. We describe three cases in which the inability to send correct messages by WhatsApp or having difficulties in using the application were important clues leading to a neurological diagnosis.

✉ Iris H. M. Meeuwis
I.Meeuwis@cwz.nl

Emma M. van Rooijen
E.vanRooijen@cwz.nl

Wim I. M. Verhagen
W.Verhagen@cwz.nl

¹ Department of Neurology C05, Canisius Wilhelmina Hospital, P.O. Box 9015, 6500 GS Nijmegen, The Netherlands

Case descriptions

Case 1

A 41-years old female with a history of migraine with aura and hypermenorrhea who had had a severe headache for 3 days, presented to our outpatient clinic. In the first 24 h she had experienced visual flickering and distortions in the visual field. The headache was located on the right side of the head. She woke up from her afternoon nap and noticed the headache with a numeric rating scale (NRS) score of nine out of ten. She felt light-headed and had vomited multiple times during the day over the last few days. She had difficulty concentrating, and was slower in her actions. Although her speech was a little slower, she did not notice any difficulties finding the right words. This was confirmed by her sister. Although the patient knew what words she wanted to say and pronounced them correctly, it was remarkable that she was not able to text those words using her mobile phone, and to put her signature on paper. Beside the red flags concerning the headache, not being able to text properly was interpreted as an alarm symptom.

She used an oral contraceptive agent. She had taken paracetamol and ibuprofen during the last 3 days, however, without sufficient effect. Her father was known with recurrent venous leg thrombosis. Physical and neurological examination showed hypertension (190/90 mmHg), and an increased BMI (41.52 kg/m²). Although she was orientated in triplo and adequate, she was bradyphrenic. There was a right sided hemianopsia and hemispatial neglect. Papilloedema was absent. There were no signs of aphasia, dysarthria or dyspraxia. She walked slowly and very concentrated without any balance disturbances. Neurological examination showed no further abnormalities.

Laboratory investigations and diagnostic tests

Orientating laboratory investigations were normal. Brain Computed tomography (CT) without intravenous contrast (Fig. 1) showed a hypodensity in the left parieto-occipital region, primary suspect for vasogenic cerebral edema. Brain Magnetic Resonance Imaging (MRI) showed this edema in the T2-weighted-Fluid-Attenuated Inversion Recovery (T2-FLAIR) series, with some swelling in the left parietal area. The Diffusion Weighted Imaging (DWI) series showed a remarkable diffusion restriction of the cerebral cortex with sparing of the white matter (Fig. 2). Because this did not match with any arterial areas, the diagnosis of a venous infarct with cortical ischemia was made. The T1-series showed an empty delta sign

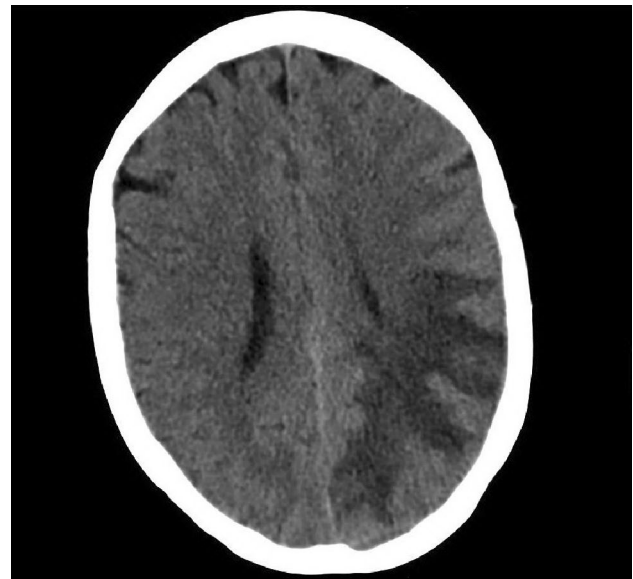


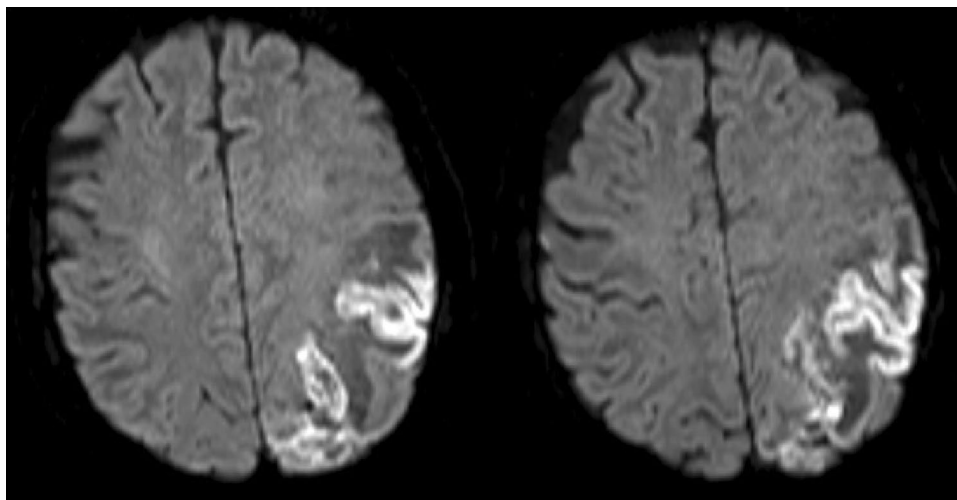
Fig. 1 Brain Computed tomography (CT) showing a hypodensity in the left parieto-occipital region, suspect for vasogenic cerebral edema

occipito-parietal in the sinus sagittalis, and there were missing cortical venous structures in this area. In conclusion, there was a venous sinusthrombosis of the sinus sagittalis superior with a venous infarct in the left hemisphere. This was confirmed by CT venography. The risk factors for a venous thrombosis in this patient were being overweight, a positive family history with deep venous thrombosis and the use of an oral contraceptive. She was admitted to hospital, and therapeutic low molecular weight heparin (LMWH) was started. Her oral contraceptive agent was stopped. Additional coagulation testing was normal. After 5 days, acenocoumarol was started and LMWH was stopped.

Case 2

A 66-years old female with a history of hypertension for which she used an angiotensin II receptor antagonist, presented to our emergency department with acute onset of speaking difficulties. At presentation, we saw a hyperventilating woman who stuttered, suggesting a functional speech problem. However, she spoke some of her sentences fluently and all were grammatically correct sentences. Sometimes she was unable to name an item, suggesting a motor aphasia. The further neurological examination was normal. All her vitals were normal, as well as her blood glucose. Brain CT was normal. We started thrombolysis because of the mild motor aphasia, despite the stutter and fluent sentences, [National Institutes of Health Stroke Scale, (NIHSS = 1)]. After 24 h clopidogrel was started as secondary prophylaxis. On the day after, the patient did not notice any improvement

Fig. 2 Diffusion weighted imaging (DWI) brain images revealing diffusion restriction of the cortex and sparing of the white matter without matching arterial area



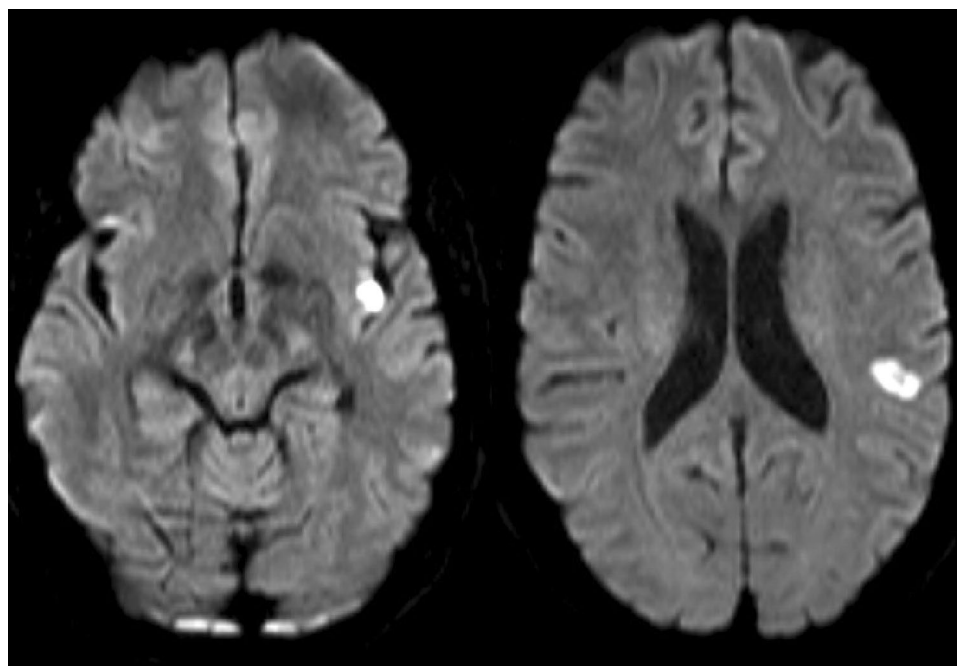
of speech. She told us she had had a lot of stress during the last few weeks. At neurological examination, the stutter remained, without paraphasia or agrammatism. She showed no hesitation in reading, repeating words and in sentences. Our diagnosis changed to a functional speech disorder. However, because of the other two patients described in our case series who presented earlier than this patient, we were aware of the value of WhatsApp Messenger in the neurological history and examination. After we actively asked for it, the patient told us she could not send her family grammatically correct text messages on WhatsApp Messenger. In the messages, words were skipped or written incorrectly, which was confirmed by her husband. Because of this atypical finding regarding a functional speech disorder, an MRI was made

(Fig. 3). On the DWI-series, there were multiple foci of diffusion-restriction in the left hemisphere, in the area supplied by the arteria cerebri media, with corresponding findings on the apparent diffusion coefficient (ADC) series, matching with recent ischemia. We continued the secondary prophylaxis. A duplex of the carotid arteries showed no significant stenosis. The patient is doing well now, although she still notices some difficulties to find words sometimes.

Case 3

A 65-years old male with a history of hypertension and type 2 diabetes presented to our emergency department with a (partially) transient speech disorder and weakness of his

Fig. 3 Diffusion weighted imaging (DWI) brain images showing multiple foci of diffusion-restriction in the left hemisphere



right arm. The patient woke up around 7.30 a.m. and was not able to put on his glasses with his right hand, and then he noticed that he was unable to tell his wife because of the inability to find the right words. The patient was last seen well around 6.30 a.m., when he woke up briefly. While transported to the emergency department, the symptoms improved. Neurological examination showed a mild expressive aphasia and a mild paresis of the right arm. Laboratory findings were normal, except for a high fasting glucose (9.6 mmol/l). CT showed an old brain infarction in the left hemisphere. After the CT a repeated neurological examination was normal. The patient was diagnosed with a transient ischemic attack (TIA) of the left hemisphere and he was admitted to our stroke unit, mainly for monitoring because there was a two-and-a-half hour window for intravenous thrombolysis left. Further stroke work-up did not show any abnormalities. The next day neurological examination showed no changes, i.e. no signs of aphasia. Nonetheless, the patient told us that he still had trouble texting his children via WhatsApp Messenger. He had trouble putting the letters in the right order, while he told us which words he wanted to text. Because he was unable to send correct text messages, it was concluded that he still suffered from a mild variant of aphasia which changed the diagnosis to a minor stroke of the left hemisphere. Two weeks later he no longer had any trouble sending messages.

Discussion

We presented three different cases in which the inability to send correct messages or to use WhatsApp Messenger, also called dystextia or dystypia, led to additional investigations or a change in diagnosis. Dystextia or dystypia is a term that was first used by Cawood et al. [6], and evaluation of this phenomenon is a very useful additive or even a clue for cerebral pathology in modern neurological history taking [7].

The proportion of elderly people with neurological diseases is growing. Also, the proportion of elderly people using social media, like WhatsApp Messenger, increases worldwide. In The Netherlands, by the end of 2017, 64% of all people over 65 and 35% of all people over 75 use smartphones and social networks like WhatsApp Messenger [8, 9]. The use of Telemedicine in the elderly is expanding, in particular around chronic conditions such as type 2 diabetes mellitus, but also in diseases associated with aging, such as dementia [10, 11]. Initiatives like these motivate the elderly even more to use their smartphones. Given these still growing numbers, we believe that asking after the ability to send text messages is certainly relevant and can lead to important clues in the medical history, even in our aging population. Texting is not a standardized subject in our neurological history taking and examination. However, as presented

above, dystextia or dystypia could be a sign of a neurological disorder and is asked for in diagnosing especially strokes. As presented in the first case, the venous infarction due to thrombosis of the sagittal sinus, led to the inability to send text messages as a result of dyspraxia combined with hemianopsia and hemispatial neglect. Our second patient suffered from nonfluent aphasia with paraphasia, resulting in grammatically incorrect text messages. This observation even led to additional radiological evaluation, revealing underlying pathology. In the last case, dystextia could have been an indicator that there were still slight symptoms of aphasia, which changed the diagnosis to a minor stroke.

The evaluation of the use of texting applications should be part of the routine neurological history taking, for three reasons. First, if texting is used as a part of neurological examination, it is a test not only for language disturbances like reading or grammatical correct writing, but also for the fine motor skills, coordination, visual and sensory input which are all needed using our devices. Second, when clarifying which neurological symptoms are described, like clumsiness with a hand, hemianopsia or writing incoherent text messages, it helps localizing the anatomic origin of the pathology. And finally, the patient's last sent messages, including its timeframe, can be used as an indicator for intravenous thrombolysis or not as a treatment for ischemic stroke, especially when no witnesses are around [12, 13]. This modern technology makes the time of onset far more accurate than using people's subjective opinion. Reporting the duration of symptoms of a transient ischemic attack is often incorrectly guessed by patients. Therefore, using the element of text messaging to get more accurate information about the time of onset can influence our management.

It is important to concretize the problem into a neurological language (e.g. aphasia) and a neurological functional disorder (e.g. apraxia). When speech disturbances are atypical, or in cases when there are no relatives to confirm speech disturbances, the inability to send text messages is an important and specific tool. Although cases about dystextia in arterial stroke have been described, it can also be found in other disorders like meningioma or migraine [14, 15], and sinus thrombosis, which makes the finding and specifying of the problem even more essential.

Conclusion

In conclusion, we present three cases that reveal the importance of evaluating the ability to correctly use text message applications such as WhatsApp Messenger. Text message programs can be used as Telemedicine or as a communication tool, yet it is the incorrect use or the inability to use these applications that can serve as potential clues for underlying neurological pathology, especially pathology of

vascular origin. We therefore advocate for the implementation of a systematic evaluation of the use of text message programs in a standard neurological history taking and examination. Asking after dystextia or dystypia specifically implicates many neurological deficits, helps localizing the anatomic origin, and gives us more accurate information about the time of onset of the symptoms. It is easy and often applicable, even in the elderly.

Author contributions IM and EVR were the major contributors in writing the manuscript. WV contributed to checking the manuscript. All authors read and approved the final manuscript.

Data availability All authors had access to all the data and checked for data accuracy. Anonymized data will be shared by request from any qualified investigator.

Compliance with ethical statements

Conflict of interest The authors declare that the research was conducted in the absence of any commercial or financial relationships that could be construed as a potential conflict of interest.

Ethics statement All patients gave written informed consent in accordance with the Declaration of Helsinki, and they also gave written informed consent for publication of this report.

References

- Giordano V, Koch H, Godoy-Santos A, Dias BW, Esteves Santos Pires R, Labronici P (2017) WhatsApp Messenger as an adjunctive tool for telemedicine: an overview. *Interact J Med Res* 6(2):e11. <https://doi.org/10.2196/ijmr.6214>
- About WhatsApp Messenger.(2019) URL: <https://www.whatsapp.com/about/>. Accessed Aug 2019
- Calleja-Castillo JM, Gonzalez-Calderon G (2018) WhatsApp in stroke systems: current use and regulatory concerns. *Front Neurol* 9:388. <https://doi.org/10.3389/fneur.2018.00388>
- Joshi SS, Murali-Krishnan S, Patankar P, Choudhari KA (2018) Neurosurgical referral service using smartphone client WhatsApp: preliminary study at a tertiary referral neurosurgical unit. *Br J Neurosurg* 32(5):553–557. <https://doi.org/10.1080/02688697.2018.1490944>
- Srivastava PV, Sudhan P, Khurana D et al (2014) Telestroke a viable option to improve stroke care in India. *Int J Stroke* 9(Suppl A100):133–134. <https://doi.org/10.1111/ijss.12326>
- Cawood TJ, King T, Sreenan S (2006) Dystextia—a sign of the times? *Ir med J* 99(5):157
- Ravi A, Rao VR, Klein JP (2013) Dystextia: acute stroke in the modern age. *JAMA Neurol* 70(3):404–405. <https://doi.org/10.1001/jamaneurol.2013.604>
- Ouderen maken inhaalslag op social media. Statistics Netherlands (CBS).(2019) URL: <https://www.cbs.nl/nl-nl/nieuws/2017/26/ouderen-maken-inhaalslag-op-sociale-media>. Accessed Sept 2019
- Ouderen actiever op social media.(2019) URL: <https://www.maxvandaag.nl/sessies/themas/media-cultuur/ouderen-actiever-op-sociale-media/>. Accessed Sept 2019
- Kim H, Jhoo JH, Jang JW (2017) The effect of telemedicine on cognitive decline in patients with dementia. *J Telemed Telecare* 23(1):149–154. <https://doi.org/10.1177/1357633X15615049>
- Alghafri TS, Alharthi SM, Al-Farsi Y et al (2018) ‘MOVEDiabetes’: a cluster randomized controlled trial to increase physical activity in adults with type 2 diabetes in primary health in Oman. *BMJ Open Diabetes Res Care* 6(1):e000605. <https://doi.org/10.1136/bmjdr-2018-000605>
- Burns B, Randall M (2014) ‘Dystextia’: onset of difficulty writing mobile phone texts determines the time of acute ischaemic stroke allowing thrombolysis. *Pract Neurol* 14(4):256–257. <https://doi.org/10.1136/practneurol-2014-000930>
- Gallardo-Molina N (2020) Stroke in the 21st century: dystextia and dystypia as indicators of neurological injury. *Clin Neurol Neurosurg* 194:105817
- Hannah J, Kissel P, Russell B, Hose J (2014) Dystextia: an early sign of pregnancy-associated meningioma. *Open J Modern Neurosurg* 4:69–75. <https://doi.org/10.4236/ojmn.2014.42015>
- Whitfield P, Jayathissa S (2011) Evolving neurological terminology in the 21st century: “dystextia” associated with complex migraine. *Intern Med J* 41(8):646–646. <https://doi.org/10.1111/j.1445-5994.2011.02507.x>

Publisher's Note Springer Nature remains neutral with regard to jurisdictional claims in published maps and institutional affiliations.