



# A Very Rapidly Growing, Spontaneous, Internal Carotid Artery Dissecting Aneurysm Triggering Simultaneous Complete Ophthalmoplegia and a Cerebral Infarct

Sanghyuk Im<sup>1</sup> and Young Woo Kim<sup>2</sup>

## Key words

- Dissecting aneurysm
- Ophthalmoplegia
- Carotid artery dissection

## Abbreviations and Acronyms

**DSA:** digital subtraction angiography

**FDS:** flow diversion stent

**ICA:** internal carotid artery

From the <sup>1</sup>Department of Neurosurgery, Eunpyeong St. Mary's Hospital; and <sup>2</sup>Department of Neurosurgery, Uijeonbu St. Mary's Hospital, College of Medicine, The Catholic University of Korea, Seoul, Korea

To whom correspondence should be addressed:

Young Woo Kim, M.D., Ph.D.

[E-mail: [youngwookim1732@gmail.com](mailto:youngwookim1732@gmail.com)]

Citation: *World Neurosurg.* (2020) 142:269-273.

<https://doi.org/10.1016/j.wneu.2020.07.028>

Journal homepage: [www.journals.elsevier.com/world-neurosurgery](http://www.journals.elsevier.com/world-neurosurgery)

Available online: [www.sciencedirect.com](http://www.sciencedirect.com)

1878-8750/\$ - see front matter © 2020 Elsevier Inc. All rights reserved.

## BACKGROUND

The clinical manifestations of spontaneous dissections of the internal carotid artery (ICA) are rather variable. The typical presenting symptom is ipsilateral head, face, or neck pain accompanied by partial Horner syndrome.<sup>1,2</sup> A large aneurysm involving a cavernous ICA may trigger cranial nerve palsy caused by a mass effect.<sup>3,4</sup>

Ophthalmoplegia involving the third, fourth, or sixth cranial nerves is a rare clinical manifestation (2.5% of cases).<sup>5</sup> Intracranial artery dissections account for 10% to 25% of strokes in young and middle-aged patients.<sup>2,6</sup>

We report a case with simultaneous presentation of ipsilateral complete ophthalmoplegia and multiple cerebral infarctions secondary to a very rapidly growing, spontaneous dissecting aneurysm in the cavernous segment of the ICA.

## CASE DESCRIPTION

A 26-year-old woman suffered sudden-onset headache. After 10 days, she visited

■ **BACKGROUND:** Simultaneous ipsilateral complete ophthalmoplegia and multiple cerebral infarctions are very rare, especially secondary to a very rapidly growing, spontaneous dissecting aneurysm in the cavernous segment of the internal carotid artery (ICA).

■ **CASE DESCRIPTION:** We describe a 26-year-old woman who presented with sudden-onset, right-sided, spontaneous ophthalmoplegia with left hemiparesis. Magnetic resonance imaging revealed a middle cerebral artery territory infarction. Digital subtraction angiography (DSA) revealed multiple arterial dissections involving both the vertebral artery and right ICA, with a dissecting aneurysm in the cavernous segment of the ICA. On day 3, the partial ophthalmoplegia worsened to complete ophthalmoplegia (third, fourth, and sixth cranial nerve palsies), despite conservative treatment. Follow-up DSA showed increased aneurysm size. The dissecting aneurysm was successfully managed by stent-assisted coil embolization. After endovascular treatment, the ophthalmoplegia, ptosis, and headache gradually resolved.

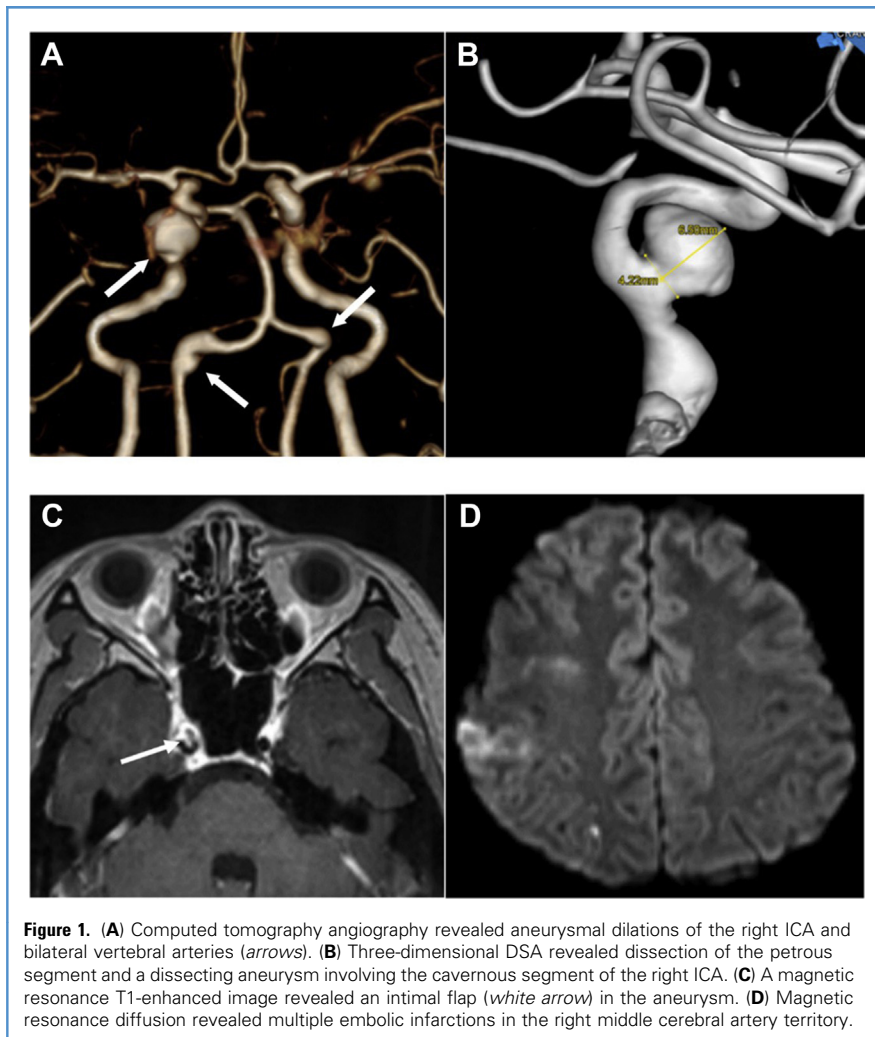
■ **CONCLUSION:** This is the first reported case of simultaneous cerebral infarction and complete ophthalmoplegia attributed to a rapidly growing dissecting aneurysm of the cavernous ICA; such aneurysms readily cause thromboembolism. Physicians who treat patients with dissecting aneurysms should carefully monitor aneurysm growth.

our emergency department with sudden-onset diplopia and left-side hemiparesis. A neurological examination revealed impaired lateral gaze and ptosis of the right eye. There was no family history of stroke or vascular disease. Computed tomographic angiography revealed an aneurysmal dilation involving the cavernous segment of the right ICA, bilateral vertebral arteries, and a normal aorta and subclavian artery. Magnetic resonance imaging and digital subtraction angiography (DSA) revealed a middle cerebral artery territory infarction with aneurysmal dilation and an intimal flap, suggestive of a dissecting aneurysm of the cavernous segment of the ICA (Figure 1).

Laboratory rheumatologic data were within the normal ranges. Conservative treatment including dual antiplatelet agents was commenced. The patient was given 450 mg clopidogrel and 100 mg aspirin on the first hospital day, and a daily maintenance dose of 75 mg

clopidogrel and 100 mg aspirin. Given the DSA result, endovascular aneurysm treatment was scheduled for 1 week later because the patient's initial condition was stable. On day 3 of admission, the partial ophthalmoplegia progressed to complete ophthalmoplegia (cranial nerve 3, 4, and 6 palsies) (Figure 2). Follow-up DSA showed that the aneurysm had increased in size (Figure 3).

The patient underwent emergency, endovascular aneurysm treatment. Before treatment, we checked platelet responsiveness to various antiplatelet medications, including aspirin or P2Y<sub>12</sub> inhibitors. In this patient, P2Y<sub>12</sub> reaction units were 9 and aspirin reaction units were 403. To prevent major bleeding, we changed the clopidogrel dose to 32.5 mg/d based on the results of platelet function tests. With the patient under general anesthesia, a 7-F sheath was placed in the right femoral artery and a heparin bolus (3000 IU) was delivered intravenously. A 7-F guiding



catheter was placed coaxially in the cervical segment of the right ICA and then a microcatheter was delivered into the

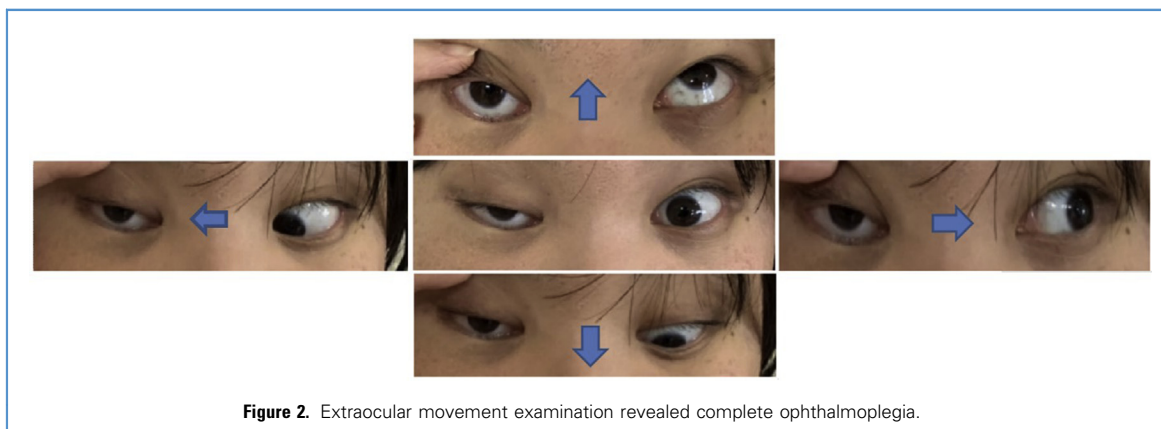
aneurysmal sac. A first coil was partially deployed and a 4 × 39 mm Enterprise stent (Cordis, Miami Lakes, FL) was

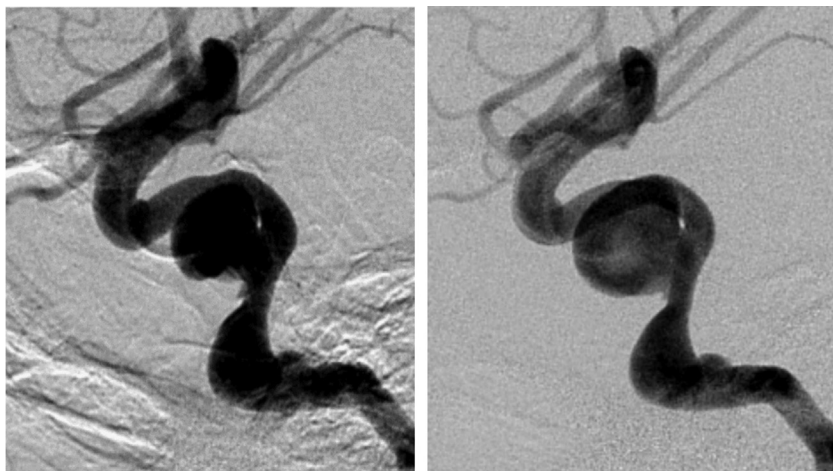
deployed from the horizontal segment of the cavernous ICA to the ICA petrous segment. The aneurysm was embolized through a jailed microcatheter using 10 detachable coils with different features and sizes (Figure 4). To enhance flow diversion, a 5 × 30 mm Solitaire stent (Medtronic Neurovascular, Irvine, CA) was overlapped with the first stent. Prednisolone (30 mg/day) was given orally for 7 days and then tapered. The ophthalmoplegia, ptosis, and headache gradually resolved (Figure 5).

## DISCUSSION

ICA dissecting aneurysms within the cavernous sinus can trigger palsy of the third, fourth, and sixth cranial nerves via different mechanisms. Abrupt enlargement of a cavernous sinus aneurysm may compress these nerves. In terms of palsy origin, Schievink et al. advanced 2 hypotheses: direct cranial nerve compression and stretching; or ischemia caused by occlusion of the nutritional arteries.<sup>5,7</sup> In some dissections, cerebral infarctions are caused by thromboembolisms attributable to intramural hematomas, or reduced blood flow secondary to vessel stenosis or occlusion. Although ICA dissection causes only 1% to 2% of all strokes, they account for 10% to 25% of strokes in young and middle-aged adults.<sup>1,8,9</sup> A thromboembolism caused by dissection may trigger a subsequent stroke.

Ophthalmoplegia involving the third, fourth, or sixth cranial nerves is a rare clinical manifestation of ICA dissection;





**Figure 3.** The aneurysm increased in size from 8.9 × 6.5 mm (hospital day 1) to 11.0 × 7.9 mm (hospital day 4).

simultaneous presentation of ipsilateral complete ophthalmoplegia and multiple cerebral infarctions is extremely rare. Schievink et al. reported that 4 of 155 patients with ICA dissections exhibited oculomotor palsies (one of cranial nerve VI, 2 of cranial nerve III, and one of cranial nerve IV).<sup>5</sup> Three of these patients had ipsilateral headache or facial pain, 1 had bilateral headache or facial pain, and 3 exhibited oculosympathetic palsies. No patient had cerebral or retinal ischemic symptoms. Biousse et al. studied 146

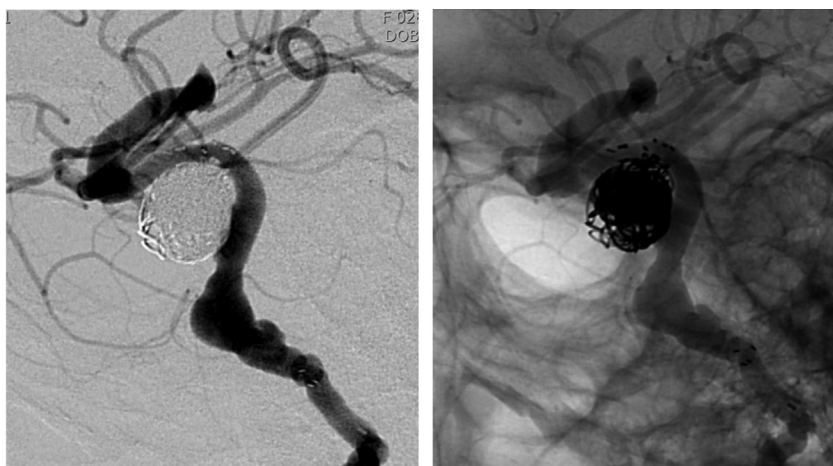
patients with ICA dissections; only 1 exhibited transient cranial nerve VI palsy.<sup>10</sup> Mokri et al. reported that 23 of 190 patients (12%) with ICA dissections had cranial nerve palsies that were low-level in 10.<sup>7</sup> Seven patients had cranial nerve V palsy, two had cranial nerve III palsy without Horner syndrome, 2 had cranial nerve VI palsy (1 with Horner syndrome), and 1 had cranial nerve IV palsy. Four patients exhibited cerebral ischemic symptoms including transient ischemic attacks or infarction. Of these,

2 had low-level cranial nerve palsies (cranial nerves IX, X, and XII), one had cranial nerve VI palsy, and 1 had dysgeusia without cranial nerve involvement. All ICA dissections involved only the extracranial vessel segment.<sup>5,7,10</sup>

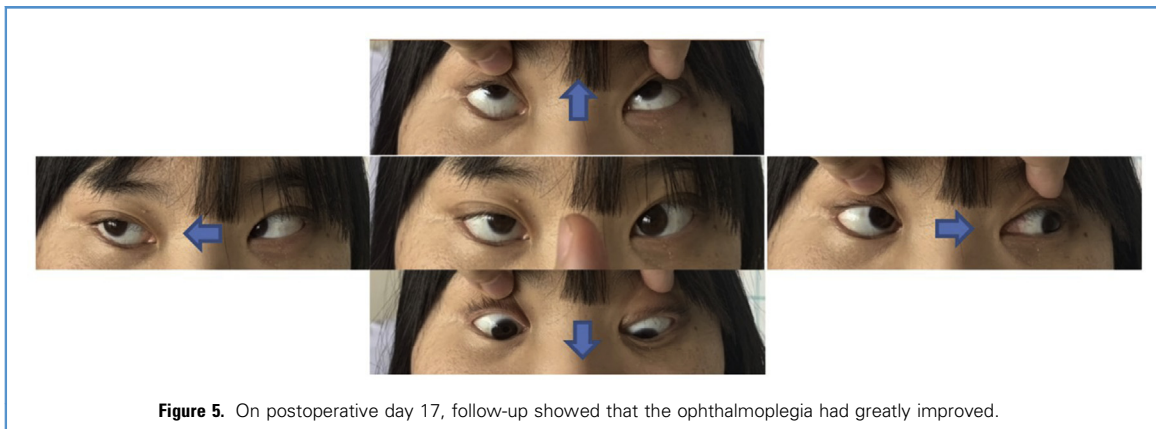
A recent trial indicated that antiplatelet agents should be considered first-line treatment.<sup>8,11</sup> This may be contraindicated in some patients at risk for bleeding, however. In addition, in some patients, symptoms may persist or become aggravated because of expansion of a concomitant pseudoaneurysm or progressive vessel narrowing. The neurological symptoms may deteriorate, with progression to hemodynamic brain ischemia. Therefore, an alternative treatment such as a neurointerventional approach should be considered for some patients. Xianjun et al. listed the indicators of patients requiring such therapy: a recurrent stroke despite the best medical therapy, hemodynamic instability because of poor collateral vessels or multiple vessel involvement, an expanding or symptomatic pseudoaneurysm, and a contra-indication for antiplatelet therapy because of a risk of (systemic or intracranial) bleeding.<sup>12</sup> In our case, the symptoms were abruptly aggravated and the aneurysm increased in size despite best medical treatment including the administration of antiplatelet agents. Neurointerventional treatment was our only option. After the procedure, the patient's symptoms improved.

In our case, the very rapid progression of ophthalmological symptoms indicated rapid aneurysm growth. Follow-up DSA performed on hospital day 3 revealed remarkable interval growth. Aneurysm growth increases the risk of rupture.<sup>13-15</sup> Abnormal blood flow around the intimal flap induces focal changes in blood pressure and reduces wall shear stress, causing endothelial damage and aneurysm remodeling.<sup>16,17</sup> Ischemic and inflammatory changes in the vessel contribute to such remodeling, aneurysm growth, and consequent rupture.<sup>16,17</sup> To the best of our knowledge, there is no prior report on a rapidly progressing dissecting aneurysm associated with ophthalmoplegia.

Initially, we considered a flow diversion stent (FDS) for treatment of this case, but



**Figure 4.** Postoperative angiography revealed that the aneurysm was completely packed after coil embolization and dual stenting.



**Figure 5.** On postoperative day 17, follow-up showed that the ophthalmoplegia had greatly improved.

the FDS has been covered by the National Health Insurance Service since November 2014 only in very limited cases with an unruptured intracranial aneurysm in Korea. In this case, the size of the aneurysm did not meet the National Health Insurance Service criteria for an FDS. Therefore, we used the double-stent method to achieve flow diversion. Another 2 endovascular treatment possibilities were ICA occlusion and coiling. Van Rooij et al. found that cranial nerve dysfunctions accompanying large or giant ICA aneurysms improved in 13 of 17 patients in a coiling group and in 31 of 39 patients in an ICA occlusion group; the between-group difference was not statistically significant.<sup>3</sup> In 41 of 48 aneurysms, the signs of cranial nerve deficits improved after treatment, and the signs remained unchanged in the remaining 7 aneurysms after therapy. Van Rooij<sup>4</sup> reported that, of 31 cavernous ICA aneurysms treated via coil embolization, 6 required additional coils, with improvements in 4 patients and cure in 2.<sup>4</sup> We successfully performed stent-assisted coil embolization. The reduced stent porosity caused by the overlapping stents, which resulted in marked hemodynamic changes inside the aneurysmal sac, may accelerate intraneurysmal thrombosis and help reduce aneurysm regrowth.<sup>18,19</sup>

## CONCLUSIONS

This is the first reported case of a simultaneous cerebral infarction and complete ophthalmoplegia attributable to a rapidly growing dissecting aneurysm of the

cavernous ICA; such aneurysms readily cause thromboembolisms. Physicians treating patients with dissecting aneurysms should carefully monitor aneurysm growth and thromboembolic complications. Close observation and short-term angiographic follow-up should also be considered.

## REFERENCES

1. Thanvi B, Munshi SK, Dawson SL, Robinson TG. Carotid and vertebral artery dissection syndromes. *Postgrad Med J*. 2005;81:383-388.
2. Schievink WI. Spontaneous dissection of the carotid and vertebral arteries. *N Engl J Med*. 2001;344:898-906.
3. van Rooij WJ, Sluzewski M. Unruptured large and giant carotid artery aneurysms presenting with cranial nerve palsy: comparison of clinical recovery after selective aneurysm coiling and therapeutic carotid artery occlusion. *AJNR Am J Neuroradiol*. 2008;29:997-1002.
4. van Rooij WJ. Endovascular treatment of cavernous sinus aneurysms. *AJNR Am J Neuroradiol*. 2012;33:323-326.
5. Schievink WI, Mokri B, Garrity JA, Nichols DA, Piegras DG. Ocular motor nerve palsies in spontaneous dissections of the cervical internal carotid artery. *Neurology*. 1993;43:1938-1941.
6. Leys D, Bandu L, Henon H, et al. Clinical outcome in 287 consecutive young adults (15 to 45 years) with ischemic stroke. *Neurology*. 2002;59:26-33.
7. Mokri B, Silbert PL, Schievink WI, Piegras DG. Cranial nerve palsy in spontaneous dissection of the extracranial internal carotid artery. *Neurology*. 1996;46:356-359.
8. Markus HS, Hayter E, Christopher L, et al. Antiplatelet treatment compared with anticoagulation treatment for cervical artery dissection (CADISS): a randomised trial. *Lancet Neurol*. 2015;14:361-367.
9. Lucas C, Moulin T, Deplanque D, Tatu L, Chavot D. Stroke patterns of internal carotid artery dissection in 40 patients. *Stroke*. 1998;29:2646-2648.
10. Biousse V, Touboul PJ, D'Anglejan-Chatillon J, Levy C, Schaison M, Bousser MG. Ophthalmologic manifestations of internal carotid artery dissection. *Am J Ophthalmol*. 1998;126:565-577.
11. Kennedy F, Lanfranco S, Hicks C, et al. Antiplatelets vs anticoagulation for dissection: CADISS nonrandomized arm and meta-analysis. *Neurology*. 2012;79:686-689.
12. Xianjun H, Zhiming Z. A systematic review of endovascular management of internal carotid artery dissections. *Interv Neurol*. 2013;1:164-170.
13. Koffijberg H, Buskens E, Algra A, Wermer MJ, Rinkel GJ. Growth rates of intracranial aneurysms: exploring constancy. *J Neurosurg*. 2008;109:176-185.
14. Rinkel GJ. Natural history, epidemiology and screening of unruptured intracranial aneurysms. *J Neuroradiol*. 2008;35:99-103.
15. Juvela S, Poussa K, Lehto H, Porras M. Natural history of unruptured intracranial aneurysms: a long-term follow-up study. *Stroke*. 2013;44:2414-2421.
16. Matheus MG, Castillo M. Development of de novo intracranial aneurysm in three months: case report and literature review. *AJNR Am J Neuroradiol*. 2003;24:709-710.
17. Schebesch KM, Doenitz C, Zoepfel R, Finkenzeller T, Brawanski AT. Recurrent subarachnoid hemorrhage caused by a de novo basilar tip aneurysm developing within 8 weeks after clipping of a ruptured anterior communicating artery aneurysm: case report. *Neurosurgery*. 2008;62:E259-E260 [discussion: E60].
18. Doerfler A, Wanke I, Egelhof T, Stolke D, Forsting M. Double-stent method: therapeutic alternative for small wide-necked aneurysms. Technical note. *J Neurosurg*. 2004;100:150-154.
19. Park WB, Sung JH, Huh J, et al. Double stent assist coiling of ruptured large saccular aneurysm

in proximal basilar artery fenestration. *J Cerebrovasc Endovasc Neurosurg.* 2015;17:227-233.

*Conflict of interest statement: All authors declare that the article content was composed in the absence of any*

*commercial or financial relationships that could be construed as a potential conflict of interest.*

*Received 28 April 2020; accepted 5 July 2020*

*Citation: World Neurosurg. (2020) 142:269-273.  
<https://doi.org/10.1016/j.wneu.2020.07.028>*

*Journal homepage: [www.journals.elsevier.com/world-neurosurgery](http://www.journals.elsevier.com/world-neurosurgery)*

*Available online: [www.sciencedirect.com](http://www.sciencedirect.com)*

*1878-8750/\$ - see front matter © 2020 Elsevier Inc. All rights reserved.*