



## Rescue Surgery in the Flow Diverter Era: Partial Trapping Plus Revascularization Technique for a Giant Carotid-Ophthalmic Aneurysm

Ramon Torné<sup>1</sup>, Ana Rodríguez-Hernández<sup>5</sup>, Ana Tercero-Uribe<sup>2</sup>, Paola Hurtado<sup>3</sup>, Antonio López-Rueda<sup>4</sup>, Jose Poblete<sup>1</sup>, Joaquim Enseñat<sup>1</sup>

### Key words

- Bypass
- Flow diverter
- Giant aneurysm
- Rescue surgery
- Thrombectomy
- Trapping

### Abbreviations and Acronyms

**EC-IC:** Extracranial-to-intracranial

**FD:** Flow diverter

**ICA:** Internal carotid artery

From the Departments of <sup>1</sup>Neurological Surgery, <sup>2</sup>Neurology, <sup>3</sup>Anesthesiology, and <sup>4</sup>Interventional Neuroradiology, Hospital Clínic de Barcelona, Universidad de Barcelona; and <sup>5</sup>Neurological Surgery, Germans Trias i Pujol, University Hospital, Barcelona, Spain

To whom correspondence should be addressed:

Ramón Torné, M.D., Ph.D.

[E-mail: [torne@clinic.cat](mailto:torne@clinic.cat)]

Citation: *World Neurosurg.* (2020) 143:73-78.

<https://doi.org/10.1016/j.wneu.2020.07.061>

Journal homepage: [www.journals.elsevier.com/world-neurosurgery](http://www.journals.elsevier.com/world-neurosurgery)

Available online: [www.sciencedirect.com](http://www.sciencedirect.com)

1878-8750/\$ - see front matter © 2020 Elsevier Inc. All rights reserved.

### INTRODUCTION

The use of new endovascular treatments has been increasing in recent years, being currently part of our usual therapeutic armamentarium. Among these treatments, the development of flow diverters (FDs) deserves special mention. These devices by themselves or in combination with coils (FD+C) have represented a major technologic advance and a paradigm shift in the management of some intracranial aneurysms.

FDs were approved for the treatment of large or giant wide-necked aneurysms of the paraophthalmic internal carotid artery. This type of aneurysms harbors intrinsic features that make them especially favorable for endovascular treatment with FDs, which can achieve occlusion rates of 86.6% at 12 months.<sup>1,2</sup> However, despite their reported safety and good results, in

■ **BACKGROUND:** Flow diverters (FDs) are an excellent option for the management of giant carotid artery aneurysms. However, in a nonnegligible percent of cases, the aneurysm may continue to grow despite multiple endovascular treatments and apparent occlusion on the angiogram. Due to the recent introduction of FDs, surgical experience after their failure is scarce and neurosurgeons have to face these challenging cases without much previous reference. Here we describe a giant ophthalmic-carotid aneurysm that presented with new severe mass effect 5 years after initially successful treatment with FDs and coils. We investigate the likely advantages of partial trapping versus complete trapping in this particular type of case.

■ **CASE DESCRIPTION:** A 63-year-old patient with a subarachnoid hemorrhage from a 26-mm left carotid-ophthalmic aneurysm was initially embolized with coils. One year later a recanalization was observed and treated with an FD. Five years afterward, the patient's mild cognitive impairment prompted a magnetic resonance image that showed significant aneurysm growth despite apparent occlusion on angiogram. Rescue surgery consisted of partial trapping + extracranial-intracranial bypass and aneurysm debulking. The patient recovered from his deficits and remains asymptomatic 2 years later.

■ **CONCLUSIONS:** In selected patients with previous long-term FDs, partial trapping may be a choice even if aneurysm debulking is needed. After years of stent placement, some endothelialization and neointimal membrane formation could have a summing effect to facilitate surgical exclusion and enable a safe thrombectomy. Classic revascularization techniques must be rethought and retested in this new FD era scenario.

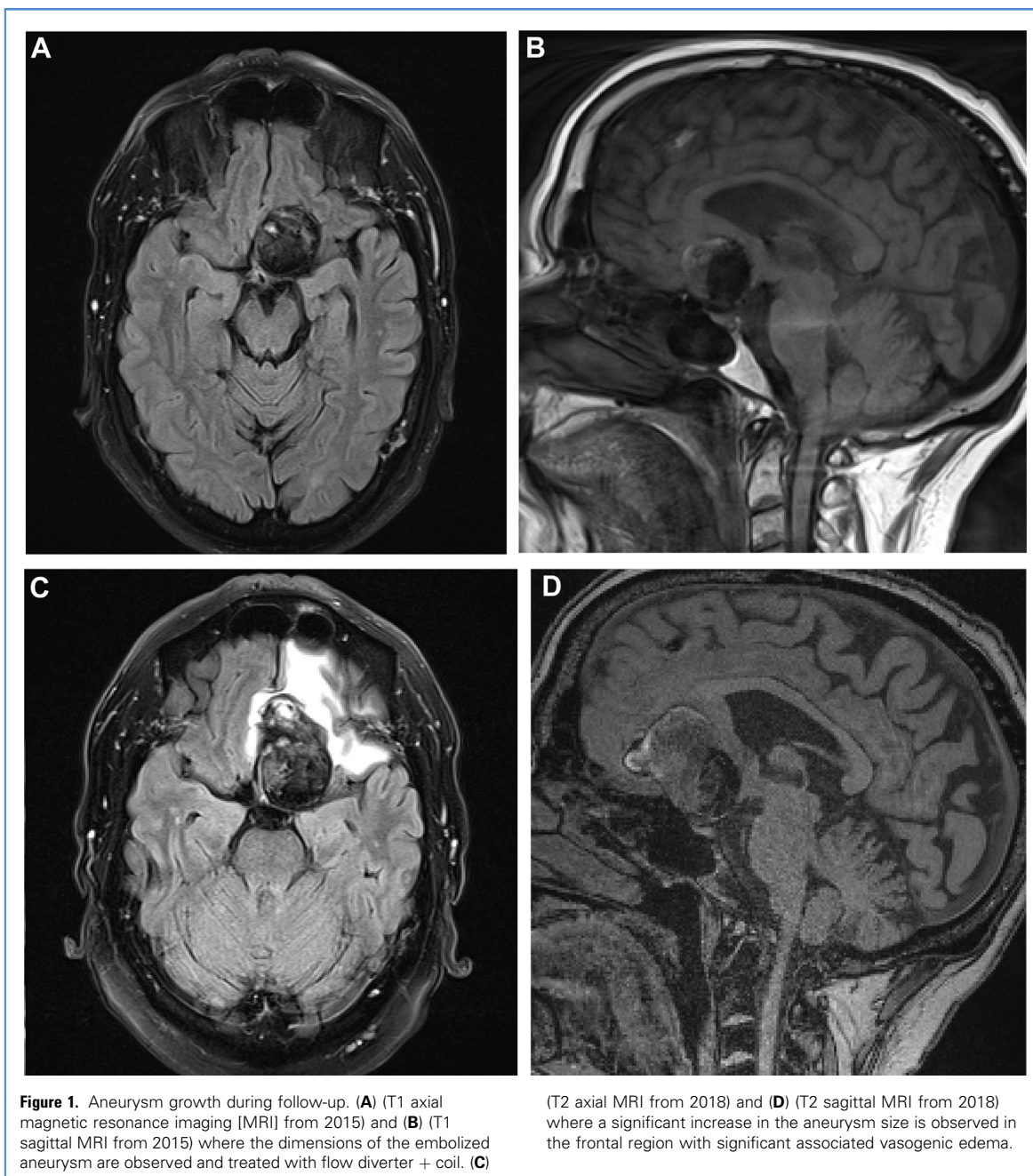
a minority of these patients the desired clinical objective is not achieved, requiring rescue microsurgical treatment. Due to their recent introduction, surgical experience after FD failure is limited and the scarce literature regarding this topic consists of case reports and small case series. Nevertheless, the continued report of these cases should not be disregarded since it may enable to create a sufficient knowledge base for future treatment algorithms that would allow us to face this pathology successfully.

Here we describe microsurgical rescue treatment in a patient with a paraophthalmic aneurysm initially managed with FD+C who presented delayed growth with mass effect. Out of the available

surgical options, based on the experience with complex aneurysms non previously managed endovascularly, partial trapping may be considered as the last tier resource. Here, we discuss the specifics of partial trapping, thrombectomy and revascularization and we investigate its likely advantages in this particular type of case.

### CASE REPORT

A 63-year-old right-handed patient with a history of hypertension, diabetes and obesity, presented to our emergency department in December 2012 with a sudden severe headache. He was diagnosed with a subarachnoid hemorrhage from a giant left carotid-ophthalmic



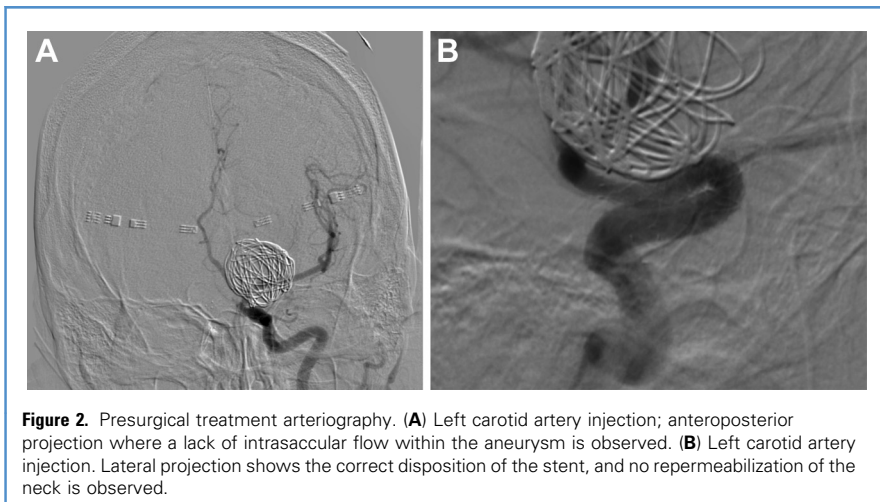
aneurysm (26 mm). An endovascular treatment with coils was initially performed. One year later, a recanalization with intrasaccular flow was detected and the patient underwent another endovascular procedure for FD placement (SILK stent-Balt Extrusion, Montmorency, France). The final arteriographic control showed complete occlusion of the

aneurysm and the patient was discharged asymptomatic.

In 2018, the patient's family reported a mild memory disorder and a mild cognitive impairment. Brain magnetic resonance imaging was performed, showing a significant size increase of the lesion at the expense of the frontal component with significant edema of the entire left frontal

lobe (**Figure 1**). A new cerebral angiography revealed a lack of aneurysm filling. A balloon test occlusion prompted aphasia and motor claudication within 15 minutes. Surgical treatment of the aneurysm to ameliorate mass effect was then proposed.

The surgical plan ruled out the possibility of simple clipping due to the



dimensions of the aneurysm and the absence of a residual neck, which would have allowed the secure placement of clips (Figure 2). Therefore a trapping plus revascularization was planned. The cervical segment of the internal carotid artery was exposed in the neck, and a pterional craniotomy was performed next. Subsequently, a high-flow extracranial-to-intracranial (EC-IC) bypass was performed using a graft of the radial artery from the common carotid artery to a left M2 middle cerebral artery branch. Once the bypass's patency was verified by micro-Doppler and indocyanine-green videoangiography, a proximal occlusion of M1 and a transient clipping of the cervical carotid artery were performed. After 30 minutes, intraoperative somatosensory and transcranial motor evoked potentials remained without changes and thus a definitive ligation of the cervical ICA was performed. The A1 segment of the anterior cerebral artery remained open, providing flow from the contralateral ICA to the anterior choroidal artery and suspected residual filling of the aneurysm, which was consequently considered partially trapped (Figure 3). Next, the aneurysm dome was dissected in order to perform a thrombectomy. The dome was incised, and an intraneurysmatic thrombectomy was performed with the "CUSA" (Cavitron Ultrasonic Surgical Aspirator) until a significant mass effect alleviation was achieved. The aneurysm walls were thoroughly coagulated. During the partial

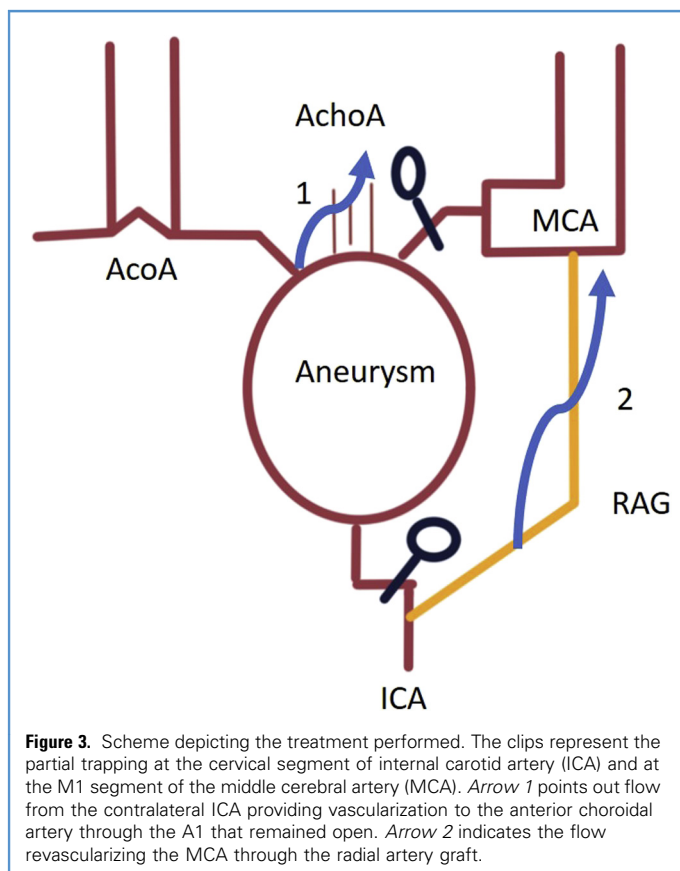
thrombectomy, no blood flow through the aneurysm was observed and thus the aforementioned partial trapping was deemed sufficient. Furthermore, the

manipulation of the distal internal carotid artery in order to perform a complete trapping was not considered safe due to the reduced visibility of the final part of the stent and its relationship with the anterior choroidal artery (Figure 4). A postoperative angiogram confirmed the bypass patency and the absence of intrasaccular flow (Figure 5).

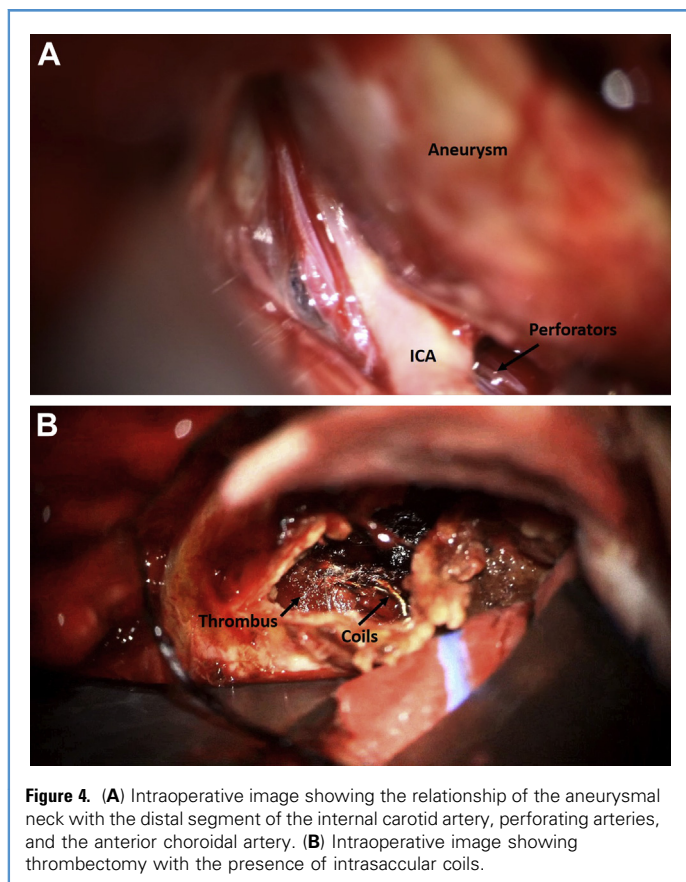
In the immediate postoperative period, the patient presented a mild language disorder and a slight motor deficit that he recovered in a few weeks. At the last available follow-up 2 years later, the patient has no neurologic deficits and the remaining aneurysm has not shown any new growth.

## DISCUSSION

Endovascular treatment with FDs for intracranial aneurysms has been expanding in recent years with good clinical results. Despite being an excellent management option for some challenging

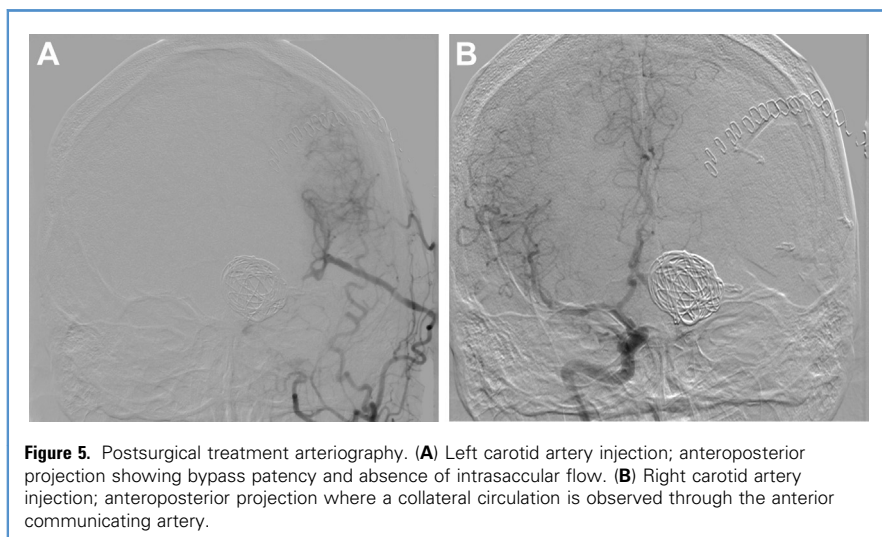






lesions, there is a nonnegligible percentage of patients in whom stents may not obtain the desired long-term result.<sup>3</sup> A well-known example is the giant

aneurysm—its continued growth can be observed despite an apparent occlusion with absence of aneurysm filling on the angiography, as happened to our patient.



This size increase is believed to be caused by inflammatory processes related to the growth of the vasa vasorum, the small vessels that nourish the aneurysm wall. These vessels will produce a release of inflammatory products and increased angiogenesis, with the subsequent formation of neomembranes and secondary growth of the aneurysmal sac.<sup>4,5</sup> This process causes the aneurysm to continue to grow. It is associated with significant edema despite arteriographic exclusion.<sup>6</sup>

There are few reports in the literature describing the microsurgical options for aneurysms that have been previously treated with stents.<sup>2,3</sup> Even more scarce are those reporting about surgical treatment of aneurysms previously treated with a stent plus coils. These cases are considered complex since they have characteristics that will hinder their surgical treatment. In coil-embolized aneurysms, manipulation of the aneurysm sac offers resistance to compression, reducing the visibility of anatomic structures.<sup>7</sup> In the particular case of giant carotid aneurysms, the coil mass may make it difficult to identify the anterior choroidal artery and posterior communicating artery that would be at risk when performing a complete trapping. Furthermore, the in vivo behavior of stent occlusion with vascular clips is still unknown, despite experimental studies suggesting a favorable response to compression.<sup>8</sup> Finally, most revascularization techniques have been tested with aneurysms not previously treated endovascularly. Consequently, cerebral revascularization techniques must be adapted to be able to face these surgical challenges.

Considering these challenges, different options for surgical treatment in aneurysms with FDs have been proposed in the literature. The first option to consider would be clipping of the aneurysm without revascularization.<sup>9</sup> Burkhardt et al<sup>10</sup> propose direct clipping with fenestrated clips whenever there is a coils-free aneurysmal neck, reserving revascularization and trapping for the rest. The second-best option would be to perform an EC-IC bypass and a complete trapping of the aneurysm. But in giant carotid aneurysms, it is complex to carry out a complete trapping without jeopardizing the patency of the anterior choroidal

artery. In these cases where perforator control may be at risk, partial trapping strategies could be a good option.<sup>11</sup>

Revascularization with partial trapping consists of a distal or proximal occlusion to obtain a reduction of the flow within the aneurysm.<sup>12-14</sup> The great risk of partial trapping is that, despite the redirection of the flow, a rupture of the sac may occur.<sup>15</sup> Therefore partial trapping appears as a minority option in the scarce series and case reports describing rescue surgery after FD. However, in well-selected cases, it could be the best option for a revascularization treatment following a failed initial endovascular management.

In the case here described, no contrast flow was observed within the aneurysm 5 years after the stent placement, which seems to suggest endothelialization of the stent wall with the formation of a neointimal membrane. Furthermore, the close relationship of the coils with the aneurysmal neck and absence of contrast in the aneurysm suggests that part of the growth must come from inflammatory processes in the wall of the aneurysmal sac. Nevertheless, it was considered essential to select a flow redirection technique to minimize the possibility of intrasaccular flow. We opted for an EC-IC bypass to an M2 branch with proximal M1 occlusion, allowing collateral flow from the right ICA to keep the anterior choroidal artery patent. Concomitantly, the ICA ligation was performed at the neck, which allowed a significant decrease in flow, thus facilitating definitive thrombosis of the aneurysm in case some residual intrasaccular flow may have persisted. Full trapping was pondered as a higher risk option than partial trapping in this particular case due to the lack of visual control of the distal segment of the ICA and relationship of the stent with the anterior choroidal artery. The use of intraoperative evoked potentials was key in this treatment since it allowed us to ensure that the contralateral flow through the A1 was sufficient to preserve the territory of the left anterior choroidal artery. Despite the partial trapping, the endothelialization of the stent allowed a safe subtotal thrombectomy until the mass effect was significantly reduced (see **Figure 4**).

Up front, partial trapping and revascularization would be a third-tier option after simple clipping and after complete trapping and revascularization when dealing with giant or complex aneurysms. However, when dealing with aneurysms that have been previously treated with FD or FD+C, partial trapping could be an excellent option for a safer and technically easier aneurysm occlusion and mass effect alleviation. The effect that flow redirection would have through partial trapping could be in addition to that already produced by FDs and coil treatments. Therefore in selected cases, previous endovascular treatments would play a role as an ally in choosing simpler and less risky revascularization techniques for our patients. Identifying those selected cases is key for the success of this management option. Meling et al<sup>16</sup> reported a case of partial trapping in which they finally had to perform a salvage surgical reoperation with a complete trapping for subsequent growth of the aneurysm. Those cases in which substantial flow continues to be present despite endovascular treatments or those in which the stent has not been in place for a long enough period to create an effective endothelialization should be ruled out for this procedure.

## CONCLUSION

With the increasing spread of FD treatments, the number of challenging aneurysms requiring rescue surgery may be expected to grow. Aneurysms treated with FDs represent a new scenario in which classic revascularization treatments will have to adapt and redefine their usefulness. Treatment with partial trapping plus bypass has been considered a final option in brain revascularization techniques. In the case of patients with multiple previous endovascular treatments, these revascularization treatments can be useful. Flow redirection through partial trapping can have a summing effect to previous endovascular treatments and facilitate the exclusion of the aneurysm without the need for a complete trapping. The continued report of these cases should be encouraged to create further knowledge that may allow safer management of these challenging aneurysms.

## REFERENCES

1. D'Urso PI, Karadeli HH, Kallmes DF, Cloft HJ, Lanzino G. Coiling for paraclinoid aneurysms: time to make way for flow diverters? *Am J Neuro-radiol.* 2012;33:1470-1474.
2. Mbabuie N, Shakur S, Gassie K, et al. Microsurgical management of intracranial aneurysms after failed flow diversion. *World Neurosurg.* 2019; 134:e16-e28.
3. Straus DC, da Silva HB, McGrath L, et al. Cerebral revascularization for aneurysms in the flow-diverter era. *Neurosurgery.* 2017;80:759-768.
4. Ferracci F-X, Gilard V, Cebula H, et al. Growth of giant intracranial aneurysms: an aneurysmal wall disorder? *Neurochirurgie.* 2017;63:6-12.
5. Iihara K, Murao K, Sakai N, et al. Continued growth of and increased symptoms from a thrombosed giant aneurysm of the vertebral artery after complete endovascular occlusion and trapping: the role of vasa vasorum. *Case report. J Neurosurg.* 2003;98:407-413.
6. Dengler J, Maldaner N, Bijlenga P, et al. Peri-aneurysmal edema in giant intracranial aneurysms in relation to aneurysm location, size, and partial thrombosis. *J Neurosurg.* 2015;123:446-452.
7. Nisson PL, Meybodi AT, Roussas A, et al. Surgical clipping of previously ruptured, coiled aneurysms: outcome assessment in 53 patients. *World Neurosurg.* 2018;120:e203-e211.
8. Bell RS, Bank WO, Armonda RA, Vo AH, Kerber CW. Can a self-expanding aneurysm stent be clipped? Emergency proximal control options for the vascular neurosurgeon. *Neurosurgery.* 2007; 68:1056-1062.
9. Kamide T, Tabani H, Safaei MM, Burkhardt J-K, Lawton MT. Microsurgical clipping of ophthalmic artery aneurysms: surgical results and visual outcomes with 208 aneurysms. *J Neurosurg.* 2018;129: 1511-1521.
10. Burkhardt J-K, Kamide T, Tabani H, Gandhi S, Benet A, Lawton MT. Anterior clinoidectomy and microsurgical clipping of a giant thrombotic recurrent ophthalmic artery aneurysm previously wrapped and stent coiled: 2-dimensional operative video. *Oper Neurosurg.* 2018;15:E63.
11. Mattingly T, Adel BV, Dyer E, et al. Failure of aneurysm occlusion by flow diverter: a role for surgical bypass and parent artery occlusion. *J Neurointerv Surg.* 2015;7:e13.
12. Esposito G, Fierstra J, Regli L. Partial trapping strategies for managing complex intracranial aneurysms. *Acta Neurochir Suppl.* 2016;123:73-75.
13. Nussbaum ES, Madison MT, Goddard JK, Lassig JP, Janjua TM, Nussbaum LA. Remote distal outflow occlusion: a novel treatment option for complex dissecting aneurysms of the posterior inferior cerebellar artery. *J Neurosurg.* 2009;111: 78-83.

14. Yoon WK, Jung YJ, Ahn JS, Kwun BD. Successful obliteration of unclippable large and giant middle cerebral artery aneurysms following extracranial-intracranial bypass and distal clip application. *J Kor Neurosurg.* 2010;48:259-262.
15. Hara T, Arai S, Goto Y, Takizawa T, Uchida T. Bypass surgeries in the treatment of cerebral aneurysms. *Acta Neurochir Suppl.* 2016;123:57-64.
16. Meling TR, Sorteberg W, Bakke SJ, Jacobsen EA, Lane P, Vajkoczy P. Case report: a troublesome ophthalmic artery aneurysm. *J Neurol Surg Rep.* 2014;75:e230-e235.

*Conflict of interest statement: The authors declare that the article content was composed in the absence of any commercial or financial relationships that could be construed as a potential conflict of interest.*

Received 23 May 2020; accepted 9 July 2020

Citation: *World Neurosurg.* (2020) 143:73-78.  
<https://doi.org/10.1016/j.wneu.2020.07.061>

Journal homepage: [www.journals.elsevier.com/world-neurosurgery](http://www.journals.elsevier.com/world-neurosurgery)

Available online: [www.sciencedirect.com](http://www.sciencedirect.com)

1878-8750/\$ - see front matter © 2020 Elsevier Inc. All rights reserved.