

## Cerebral venous thrombosis: Atypical presentation of COVID-19 in the young

David E. Klein, DO,\* Richard Libman, MD,\* Claudia Kirsch, MD,† and Rohan Arora, MD\*

---

*Objective:* Identify clinical and radiographic features of venous infarct as a presenting feature of COVID-19 in the young. *Background:* SARS-CoV-2 infection causes hypercoagulability and inflammation leading to venous thrombotic events (VTE). Although elderly patients with comorbidities are at higher risk, COVID-19 may also cause VTE in a broader patient population without these risks. Neurologic complications and manifestations of COVID-19, including neuropathies, seizures, strokes and encephalopathy usually occur in severe established cases of COVID-19 infection who primarily present with respiratory distress. *Case description:* Case report of a 29-year-old woman, with no significant past medical history or comorbidities, presenting with new onset seizures. Further questioning revealed a one-week history of headaches, low-grade fever, mild cough and shortness of breath, diagnosed as COVID-19. Imaging revealed a left temporoparietal hemorrhagic venous infarction with left transverse and sigmoid sinus thrombosis treated with full dose anticoagulation and antiepileptics. *Conclusion:* Although elderly patients with comorbidities are considered highest risk for COVID-19 neurologic complications, usually when systemic symptoms are severe, this case report emphasizes that young individuals are at risk for VTE with neurologic complications even when systemic symptoms are mild, likely induced by COVID-19 associated hypercoagulable state.

**Key words:** Cerebral venous thrombosis (CVT)—COVID-19—Venous thrombotic events (VTE)—Stroke in young

© 2020 Elsevier Inc. All rights reserved.

---

Cerebral venous thrombosis (CVT), although an uncommon form of stroke, usually occurs in women approximately 75% of the time, with 80% being less than 50 years of age.<sup>1,2</sup> While viral infections rarely directly cause CVT, strokes associated with viruses including COVID-19 have been reported.<sup>3</sup> Postulated mechanisms

for the direct and indirect apoplectic nature of certain viruses include systemic inflammation and endothelial injury, both known stroke risk factors. Emerging data suggest a novel highly virulent strain of a  $\beta$ -coronaviruses (CoV), coronavirus infectious disease (COVID-19), may confer a particularly high risk of stroke.<sup>4–6</sup> Severe acute respiratory syndrome coronavirus 1 (SARS-CoV-1), Middle Eastern Respiratory Syndrome coronavirus (MERS-CoV) and now severe acute respiratory syndrome coronavirus 2 (SARS-CoV-2) have been linked to para-infectious stroke.<sup>3–6</sup>

Hypercoagulability of SARS-CoV2, manifesting as increase in D-dimer, lactate dehydrogenase (LDH) and prolonged coagulation times is associated with more severe disease and can help risk stratify patients on presentation.<sup>7</sup> However, the resultant venous thrombotic events (VTEs) including deep vein thrombosis (DVT) and

---

From the \*Department of Neurology, Zucker School of Medicine at Hofstra/Northwell Health, United States; and †Department of Radiology, Zucker School of Medicine at Hofstra/Northwell Health, United States.

Received April 30, 2020; revision received May 17, 2020; accepted May 18, 2020.

Address correspondence to Rohan Arora, MD, Hofstra Northwell School of Medicine Forest Hills, United States E-mail:

[rarora@northwell.edu](mailto:rarora@northwell.edu).

1052-3057/\$ - see front matter

© 2020 Elsevier Inc. All rights reserved.

<https://doi.org/10.1016/j.jstrokecerebrovasdis.2020.104989>

pulmonary embolism (PE), are more often reported to occur later in COVID-19's disease course.<sup>8–10</sup>

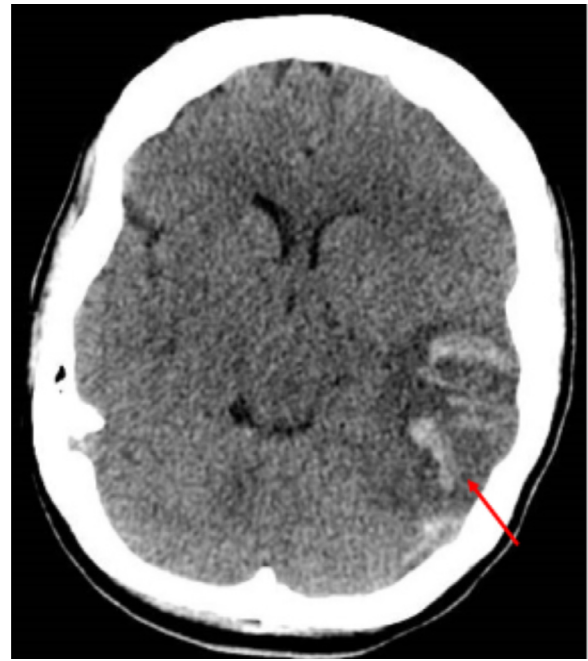In addition to fever, dry cough, shortness of breath and myalgias, neurologic signs and symptoms may occur due to COVID-19. Neurologic sequelae such as anosmia, ageusia, headache, dizziness and altered sensorium may occur due to direct viral infection or as secondary complications of SARS-CoV2.<sup>11–13</sup> This case report presents a 29-year-old woman with a Dural Venous Sinus Thrombosis (DVST) early in the course of COVID-19.

### Case description

A 29-year-old right-handed woman with no known medical history presented with new onset generalized tonic-clonic seizures with post-ictal confusion. She later reported that prior to admission, she had over a week of cough, low grade fever, mild shortness of breath and a mild headache. She took no regular medications, including no hormonal contraceptives. On initial exam, she was afebrile, mildly agitated, and complaining of neck pain. She was breathing room air with an oxygen saturation of 100% and had a body mass index of 17.4. While in the emergency department she had a third seizure, was given Lorazepam 2 mg IV, loaded with Levetiracetam 1000 mg IV and started on Levetiracetam 750 mg IV twice daily. Initial neurologic exam was notable for decreased level of arousal, global aphasia, decreased blink to threat on the right and a mild to moderate right facial palsy. There was spontaneous movement against gravity in all four limbs with slightly less movement of the right upper extremity.

Initial non-contrast head CT demonstrated left temporoparietal hemorrhagic venous infarct with edema and mass effect with 5mm rightward shift as well as venous thrombosis in distal left transverse and sigmoid sinus (Fig. 1). Nasal swab polymerase chain reaction (PCR) was positive for COVID-19. She had a notable microcytic anemia with hemoglobin of 5.5 g/dL on admission, determined to be due to iron deficiency secondary to menorrhagia, treated with two units of packed red blood cells and started on ferrous sulfate 325 mg daily. Additional laboratory findings, consistent with COVID-19 included elevated LDH, CRP, and D-dimer levels. Laboratory values, including a normal coagulation profile, are included (Table 1). Ferritin was low, likely from iron deficiency anemia. Hypercoagulable work up was notable for elevated anticardiolipin IgM serum levels and possible thalassemia trait. Post transfusion, hemoglobin levels stabilized and her DVST was initially treated with intravenous heparin. Due to poor oral intake, oral anticoagulation was avoided, and she was transitioned to enoxaparin 50 mg subcutaneously every 12 h.

MRI brain showed hyperintense DWI signal of the left temporoparietal hemorrhagic infarct with mass effect and effacement of the left lateral and third ventricle with 4mm



**Fig. 1.** Non-contrast head CT demonstrating left temporoparietal hemorrhagic venous infarct with edema and mass effect causing 5 mm rightward shift, red arrow pointing to increased attenuation and venous thrombosis in distal left transverse and sigmoid sinus

rightward shift (Fig. 2). 2D time of flight MR venography demonstrated absence of flow in the left transverse and sigmoid sinus and left internal jugular vein secondary to venous thrombosis. Additionally demonstrated flow related signal in the right transvers and sigmoid sinus extending to a patent right internal jugular vein (Fig. 3).

The day after admission, she continued to have a waxing and waning level of arousal and complained of diplopia. On exam, there were bilateral 6th nerve palsies and fundoscopy demonstrated bilateral papilledema. She was started on acetazolamide 500 mg twice daily with accompanying serial fundoscopic exams. Over the next seven days, she improved clinically in alertness and had a moderate mixed aphasia with persistent bilateral 6th nerve palsies.

### Discussion

Hypercoagulability induced by COVID-19 has been implicated in PEs, VTEs, disseminated intravascular coagulation (DIC) and recently in stroke.<sup>9,14,15</sup> Postulated mechanisms of hypercoagulability include disruptions in the renin-angiotensin (RAS) system with reduction in ACE2 and Ang-1-7 and alterations in the coagulation cascade leading to a consumptive coagulopathy and cytokine storm including IL-1, IL-6 and TNF- $\alpha$ . This is a significant consideration while evaluating stroke patients in the setting of COVID-19. In this patient's case with no past medical history, she had potential competing mechanisms of hypercoagulability, including iron deficiency anemia, a

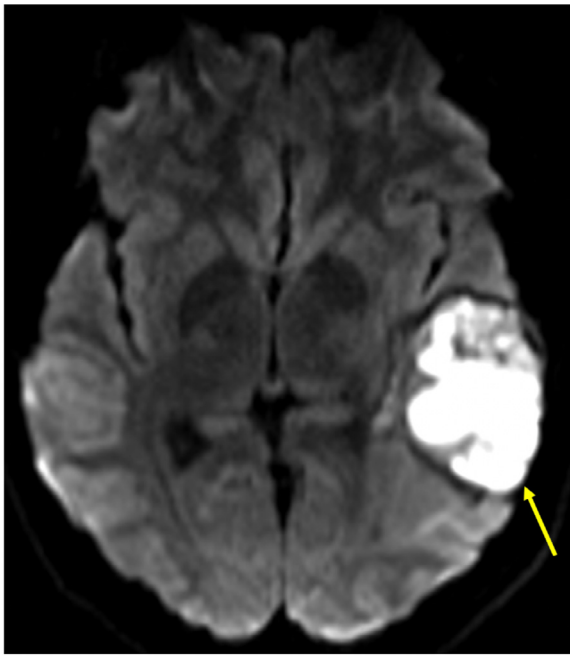
**Table 1.** Laboratory data.

Variable	Result (reference range)
Absolute lymphocyte count ( <i>per</i> $\mu\text{L}$ )	580 (1000–3300)
Absolute reticulocyte count ( <i>per</i> $\mu\text{L}$ )	70,000 (25,000–125,000)
Activated partial thromboplastin time (aPTT) (s)	28.7 (27.5–36.3)
Anisocytosis	Marked
Anticardiolipin antibody level, total	Positive (negative).
Anticardiolipin IgG, serum (GPL)	11.7 (0.0–12.5)
Anticardiolipin IgM, serum (MPL)	53.9 (0.0–12.5)
Antithrombin III assay with reflex (%)	91 (76–140)
Beta 2 glycoprotein 1 antibody screen	Negative (negative)
Cardiolipin antibody IgA (APL)	<5.0 (0.0–12.5)
C-reactive protein (mg/L)	37 (<5)
COVID-19 PCR	Detected (not detected)
CRP high sensitivity (mg/L)	111.74 (<3.0)
CT abdomen and pelvis without contrast	Pulmonary ground glass opacities consistent with known COVID 19. Enlarged fibroid uterus.
D-dimer assay, quantitative (ng/L)	2876 (<230)
Factor V assay (%)	95 (75–150)
Ferritin, serum (ng/mL)	10.40 (15–150)
Haptoglobin, serum (mg/dL)	166 (34–200)
Hematocrit (%)	22 (34.5–45.0)
Hemoglobin (g/dL)	5.8 (11.5–15.5)
Hemoglobin A (%)	93.1 (>90)
Hemoglobin A2 (%)	2.4 (2.4–3.5)
Hemoglobin electrophoresis comments	Normal HPLC pattern with low MCV, anemia and high RBC, suggestive of thalassemia trait. Hemoglobin A2 is normal with mild elevation of hemoglobin F, suggestive of delta/beta thalassemia trait.
Hemoglobin F (%)	4.5 (0–1.5)
Hypochromia	Moderate
International normalized ratio (INR)	1.10 (0.88–1.17)
Iron total, serum ( $\mu\text{g/dL}$ )	44 (30–160)
Lactate dehydrogenase (LDH), serum (U/L)	287 (135–225)
Mean corpuscular volume (MCV) (fL)	63.4 (80.0–100.0)
Microcytosis	Marked
Platelets ( <i>per</i> $\mu\text{L}$ )	335,000 (150,000–400,000)
Poikilocytosis	Moderate
Procalcitonin (ng/mL)	0.06 (0.02–0.10)
Prolactin, serum (ng/mL)	55.2 (3.4–24.1)
Prothrombin time (PT), plasma (s)	12.7(9.8–13.1)
Red blood cell distribution width (RDW) (%)	21.0 (10.3-14.5)
Reticulocyte percent (%)	1.9 (0.5–2.5)
Thrombin time assay (s)	24.9 (16.0–26.0)
Total iron binding capacity (TIBC) ( $\mu\text{g/dL}$ )	308 (140–530)
Unsaturated iron binding capacity ( $\mu\text{g/dL}$ )	263.8 (110–370)
Venous blood gas base excess (mmol/L)	1.2 (–3 to +2)
Venous blood gas $\text{HCO}_3$ (mmol/L)	25 (20–27)
Venous blood gas $\text{pCO}_2$ (mm Hg)	48 (41–51)
Venous blood gas pH	7.36 (7.32–7.43)
Venous blood gas $\text{pO}_2$ (mm Hg)	43 (35–40)
White blood cell count ( <i>per</i> $\mu\text{L}$ )	8760 (3800–10,500)

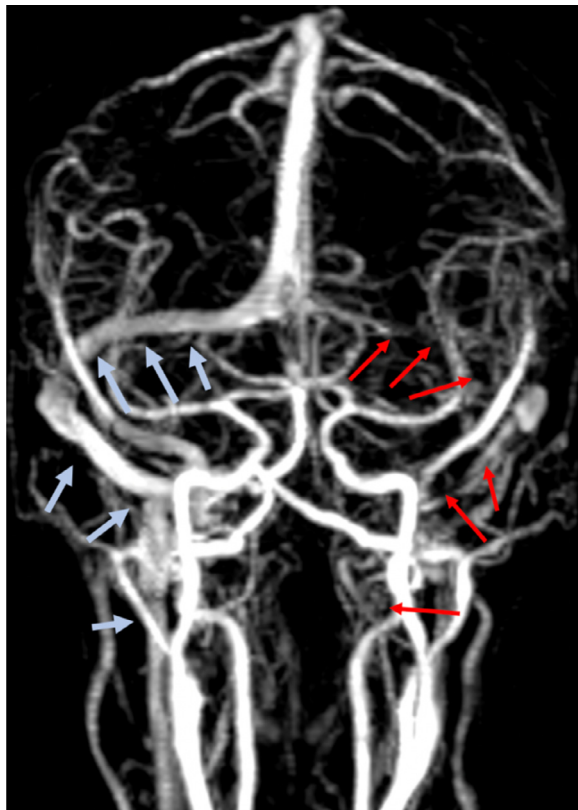
possible  $\beta$  or  $\delta$  thalassemia trait and increased anti-cardiolipin IgM serum titers. Anticardiolipin antibodies have been shown to rise in acute hypercoagulable states, certain cases of systemic viral infections and even in acute stroke.<sup>14</sup> Thus, the anticardiolipin antibody increase in our patient's case may or may not have contributed to her

DSVT, and this cannot be determined without future re-testing. This suggests advanced COVID-19 provoked hypercoagulability likely contributed to her DVST.

The neurologic manifestations of COVID-19, including stroke, are usually reported later in the disease course.<sup>4-6,10,11</sup> Though both cerebral venous infarction and



**Fig. 2.** 3T DWI MRI, yellow arrow pointing to hyperintense DWI signal of evolving left temporoparietal hemorrhagic infarct, with mass effect and effacement of the left lateral and third ventricle with 5 mm rightward shift.



**Fig. 3.** 2D time of flight MR venography with red arrows denoting absence of flow in the left transverse and sigmoid sinus and left internal jugular vein secondary to venous thrombosis. Light blue arrows denoting normal flow related signal in the right transvers and sigmoid sinus extending to a patent right internal jugular vein.

COVID-19 can occur in the young, cerebral venous thrombosis and infarction is a rare documented early presentation of COVID 19. The patient did have fever, shortness of breath and a cough, minor in severity, which were not presenting complaints on admission.

Regarding treatment, the choice of anticoagulants in COVID-19 associated VTEs is a matter of debate.<sup>16</sup> Both unfractionated heparin and low molecular weight heparins are used in acute DVST. Emerging evidence suggests that various heparins can bind to the COVID-19 spike proteins, help downregulate IL-6, and directly dampen immune activation.<sup>17</sup> Theoretically this may be of clinical benefit. Alternative treatments that interact with the ACE2 receptors are also being postulated, although clinical trials have not yet occurred.<sup>18,19</sup>

### Conclusion

Hypercoagulability is a known complication of COVID-19. Although severe cases are usually reported in older populations and in those with underlying comorbidities, this case report emphasizes that this may occur in young individuals without significant medical history. Furthermore, COVID-19 positive patients may have an atypical presentation with primary cerebrovascular syndromes such as DVST.

### Conflict of Interest

The authors declare that they have no known competing financial interests or personal relationships that could have appeared to influence the work reported in this paper.

### References

1. Silvis SM, Sousa DAD, Ferro JM, Coutinho JM. Cerebral venous thrombosis. *Nat Rev Neurol* 2017;13(9):555-565.
2. Field TS, Hill MD. Cerebral venous thrombosis. *Stroke* 2019;50(6):1598-1604.
3. Umapathi T, Kor AC, Venketasubramanian N, et al. Large artery ischaemic stroke in severe acute respiratory syndrome (SARS). *J Neurol* 2004;251(10):1227-1231.
4. Pleasure SJ, Green AJ, Josephson SA. The spectrum of neurologic disease in the severe acute respiratory syndrome coronavirus 2 pandemic infection. *JAMA Neurol* 2020. <https://doi.org/10.1001/jamaneurol.2020.1065>. Published online April 10, 2020.
5. Mao L, Wang M, Chen S, et al. Neurological manifestations of hospitalized patients with COVID-19 in Wuhan, China: a retrospective case series study. *SSRN Electron J* 2020:E1-E8.
6. Zegarra-Valdivia J, Vilca BC, Tairo T, Munive V, Lastarria C. Neurological component in coronaviruses induced disease: systematic review of SARS-CoV, MERS-CoV, AND SARS-CoV-2. 2020
7. Lippi G, Favaloro EJ. D-dimer is associated with severity of coronavirus disease 2019: a pooled analysis. *Thromb Haemost* 2020;120:876-878.
8. Xie Y, Wang X, Yang P, Zhang S. COVID-19 complicated by acute pulmonary embolism. *Radiol: Cardiothorac Imaging* 2020;2(2):1-2.

9. Yin S, Huang M, Li D, Tang N. Difference of coagulation features between severe pneumonia induced by SARS-CoV2 and non-SARS-CoV2. *J Thromb Thrombolysis* 2020. <https://doi.org/10.1007/s11239-020-02105-8>. Published online March 4, 2020.
10. Guan W-J, Ni Z-Y, Hu Y, et al. Clinical characteristics of coronavirus disease 2019 in China. *N Engl J Med* 2020;382(18):1708-1720.
11. Filatov A, Sharma P, Hindi F, Espinosa PS. Neurological complications of coronavirus disease (COVID-19): encephalopathy. *Cureus* 2020;12(3):e7352.
12. Li YC, Bai WZ, Hashikawa T. The neuroinvasive potential of SARS-CoV2 may play a role in the respiratory failure of COVID-19 patients. *J Med Virol* 2020;92(6):552-555.
13. Narra R, Mandapalli A, Kamaraju SK. Acute necrotizing encephalopathy in an adult. *J Clin Imaging Sci* 2015;5:20.
14. Zhang Y, Xiao M, Zhang S, et al. Coagulopathy and anti-phospholipid antibodies in patients with Covid-19. *N Engl J Med* 2020;382(17):e38(1)-e38(3).
15. Tan CW, Low JGH, Wong WH, Chua YY, Goh SL, Ng HJ. Critically ill COVID-19 infected patients exhibit increased clot waveform analysis parameters consistent with hypercoagulability. *Am J Hematol* 2020:1-3.
16. Ferro JM, Coutinho JM, Dentali F, et al. Safety and efficacy of dabigatran etexilate vs dose-adjusted warfarin in patients with cerebral venous thrombosis. *JAMA Neurol* 2019;76(12):1457.
17. Chen B, Lisman T, Ren D, et al. Analysis of thrombotic factors in severe acute respiratory syndrome (SARS) patients. *Thromb Haemost* 2006;96(07):100-101.
18. Kuba K, Imai Y, Rao S, et al. A crucial role of angiotensin converting enzyme 2 (ACE2) in SARS coronavirus-induced lung injury. *Nat Med* 2005;11(8):875-879.
19. Jiang T, Gao L, Lu J, Zhang Y-D. ACE2-Ang-(1-7)-Mas axis in brain: a potential target for prevention and treatment of ischemic stroke. *Curr Neuropharmacol* 2013;11(2):209-217.