



# Primary Endoscopic Management of Apoplexy in a Giant Pituitary Adenoma

Antonio Romano<sup>1</sup>, Mario Ganau<sup>2</sup>, Ismail Zaed<sup>2</sup>, Antonino Scibilia<sup>2</sup>, Gabriele Oretti<sup>1</sup>, Salvatore Chibbaro<sup>2</sup>

## Key words

- Endoscopic approach
- Giant adenoma
- Pituitary apoplexy

From the <sup>1</sup>Neurosurgery Hub&Spoke, Parma-Reggio Emilia, Parma, Italy; and <sup>2</sup>Department of Neurosurgery, University of Strasbourg, Strasbourg, France

To whom correspondence should be addressed:  
Ismail Zaed, M.D.

[E-mail: [ismailzaed1@gmail.com](mailto:ismailzaed1@gmail.com)]

▶ Supplementary digital content available online.

Citation: *World Neurosurg.* (2020) 142:312-313.

<https://doi.org/10.1016/j.wneu.2020.07.059>

Journal homepage: [www.journals.elsevier.com/world-neurosurgery](http://www.journals.elsevier.com/world-neurosurgery)

Available online: [www.sciencedirect.com](http://www.sciencedirect.com)

1878-8750/\$ - see front matter © 2020 Elsevier Inc. All rights reserved.

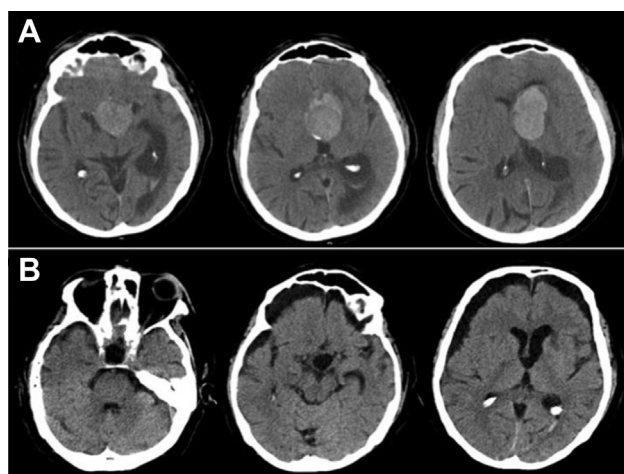
## INTRODUCTION

Sellar lesions with large suprasellar extension represent a neurosurgical challenge because of their nature and anatomic complexity. The goal of the extended transphenoidal-transtuberculum approach is enlarging the transsphenoidal route superiorly and laterally allowing for a surgical adequate exposure and offering a

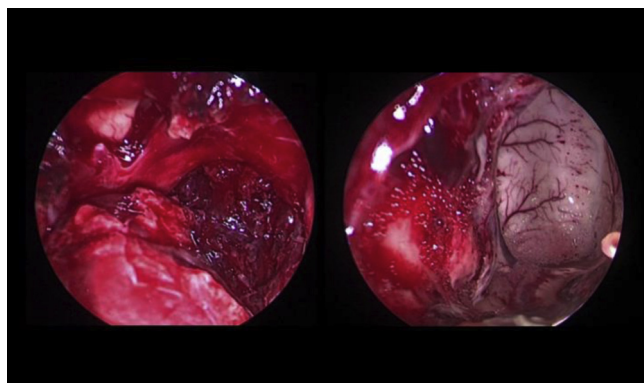
■ **BACKGROUND:** Sellar lesions with large suprasellar extension represent a neurosurgical challenge because of their nature and anatomic complexity. The goal of the extended transphenoidal-transtuberculum approach is enlarging the transsphenoidal route superiorly and laterally allowing for a surgical adequate exposure and offering a remarkable versatility in many sellar pathologies.

■ **CASE DESCRIPTION:** We present the case of a 65-year-old man who suddenly developed blindness, right hemiparesis, and decreased alertness. The initial head computed tomography scan revealed a pituitary apoplexy of a giant adenoma associated with hydrocephalus resulting from obstruction of the foramen of Monro. The video shows a complete lesion removal through the sole endoscopic approach, with opening of the dural layer of sphenoidal plane and successful decompression of the third ventricle. Visual and functional improvement occurred in the immediate postoperative course. No lumbar drain has been used.

■ **CONCLUSIONS:** This case demonstrates how the endoscopic approach can be attempted as a first and possibly stand-alone option for the surgical management of large sellar-suprasellar lesions. The endoscopic route is not associated with high rates of major complications and is safe when performed by experienced surgeons. In fact, it guarantees an enhanced control of the vascular feeders reaching the tumor from the anterior and middle fossa and results in a satisfactory manipulation of lesions invaginating into the floor of the third ventricle. A careful preoperative assessment of Knosp grade, tumor volume, hemorrhagic components, suprasellar extension, and sphenoid sinus invasion should always guide the management plan and suggest a staged or a combined (with transventricular or pterional approach) removal in particularly challenging cases.



**Figure 1.** Computed tomography scan (A) showing pituitary apoplexy of a giant adenoma associated with hydrocephalus resulting from obstruction of the foramen of Monro. Postoperative results (B).



**Figure 2.** Caption from the video showing a complete lesion removal through the sole endoscopic approach, with opening of the dural layer of sphenoidal plane and successful decompression of the third ventricle.

remarkable versatility in many sellar pathologies.<sup>1,2</sup>

### CASE DESCRIPTION

We present the case of a 65-year-old man (**Video 1**) who suddenly developed blindness, right hemiparesis, and decreased alertness. The initial head computed tomography scan (**Figure 1**) revealed a pituitary apoplexy of a giant adenoma associated with hydrocephalus resulting from obstruction of the foramen of Monro. The video shows a complete lesion removal through the sole endoscopic approach, with opening of the dural layer of sphenoidal plane and successful decompression of the third ventricle (**Figure 2**). Visual and functional

improvement occurred in the immediate postoperative course. No lumbar drain has been used.



Video available at  
[www.sciencedirect.com](http://www.sciencedirect.com)

### CONCLUSIONS

This case demonstrates how the endoscopic approach can be attempted as a first and possibly stand-alone option for the surgical management of large sellar-suprasellar lesions.

The endoscopic route is not associated with high rates of major complications and is safe when performed by experienced surgeons. In fact, it guarantees an enhanced control of the vascular feeders reaching the tumor from the anterior and middle fossa and results in a satisfactory manipulation of lesions invaginating into the floor of the third ventricle. A careful preoperative

assessment of Knosp grade, tumor volume, hemorrhagic components, suprasellar extension, and sphenoid sinus invasion should always guide the management plan and suggest a staged or a combined (with transventricular or pterional approach) removal in particularly challenging cases.<sup>3,4</sup>

### REFERENCES

1. Cavallo LM, Prevedello D, Esposito F, et al. The role of the endoscope in the transsphenoidal management of cystic lesions of the sellar region. *Neurosurg Rev.* 2008;31:55-64.
2. Cavallo LM, Prevedello DM, Solari D, et al. Extended endoscopic endonasal transsphenoidal approach for residual or recurrent craniopharyngiomas. *J Neurosurg.* 2009;111:578-589.
3. Romano A, Chibbaro S, Marsella M, et al. Combined endoscopic transsphenoidal-transventricular approach for resection of a giant pituitary macroadenoma. *World Neurosurg.* 2010;74:161-164.
4. Juraschka K, Khan OH, Godoy BL, et al. Endoscopic endonasal transsphenoidal approach to large and giant pituitary adenomas: institutional experience and predictors of extent of resection. *J Neurosurg.* 2014;121:75-83.

*Conflict of interest statement:* The authors declare that the article content was composed in the absence of any commercial or financial relationships that could be construed as a potential conflict of interest.

Received 25 April 2020; accepted 9 July 2020

Citation: *World Neurosurg.* (2020) 142:312-313.  
<https://doi.org/10.1016/j.wneu.2020.07.059>

Journal homepage: [www.journals.elsevier.com/world-neurosurgery](http://www.journals.elsevier.com/world-neurosurgery)

Available online: [www.sciencedirect.com](http://www.sciencedirect.com)

1878-8750/\$ - see front matter © 2020 Elsevier Inc. All rights reserved.