

## A Case of Aneurysm of the Vein of Galen

Ki Bum Sung, M.D., Dae Il Chang, M.D., Ju Han Kim, M.D.,  
Myung Ho Kim, M.D., Chang Kok Hahm, M.D., \*and Seok Chol Jeon, M.D. \*

*Department of Neurology and \*Radiology, College of Medicine, Hanyang University,  
Seoul, Korea*

*Aneurysm of the vein of Galen is a very rare disease. The authors present a case of secondary aneurysm of the vein of Galen which was confirmed by characteristic clinical symptoms, brain CT and angiographic findings. The patient was a 14-year-old right handed girl with intermittent headache, nausea, vomiting, dysphasia and gait disturbance. Neurologic examination revealed dysarthria, nasal voice, blurring of both margins of optic discs, truncal ataxia and dysidiadochokinesia. Sensory function was normal but right hemiparesis was seen. Roentgenogram of the skull revealed diffuse thinning of the calvarium, widening of sella turcica and erosion of clinoid processes. Computed tomogram of the brain showed dilatation of all ventricles and round hyperdense mass behind the third ventricle in the midline. The lesion was enhanced markedly and homogeneously. Left and right internal carotid angiograms showed arteriovenous malformation with drainage to the aneurysm of the vein of Galen.*

**Key Words:** *Aneurysm, vein of Galen, arteriovenous malformation, hydrocephalus, congestive heart failure.*

### INTRODUCTION

**Aneurysm** of the vein of Galen is known to be very rare. Only less than 200 cases have been reported since Steinheil first described in 1895 (Wilkins and Rengachary, 1985).

It is two times commoner in male (Rosenberg, 1955; Hoffman, 1982), and tends to present in stereotyped patterns depending upon the age of the patient (Gold et al., 1964). In 1960, Litvak et al. made a clear distinction between two characteristic types of aneurysm of the vein of Galen, primary and secondary. It is important to identify each type precisely, because surgical approaches necessary to obliterate them are different.

The prognosis of this disease has long been recognized to be poor, and depends upon the age at

onset. With onset in the neonatal period, all neonates died (Amacher, 1985). In spite of great advances in microsurgical techniques, surgical mortality has been 33% or higher in the infants and childhood group (Yasargil, 1976).

In this paper, with reviewing some of concerned literatures, we present a case of secondary type aneurysm of the vein of Galen which is associated with bilateral complex arteriovenous malformations.

### CASE REPORT

This 14-year-old right handed girl presented on January 21, 1986 with intermittent headache accompanied by nausea and vomiting, dysphasia, and gait disturbance. Her family and past history was unremarkable. Since 12 years of age, she did not so well at school. She began to suffer from difficulties in speaking, and headache frequently accompanied by nausea and vomiting, dizziness, and tinnitus. She noticed that gait disturbance and weakness of right lower extremity were getting

**Address for Correspondence:** *Ki Bum Sung, M.D., Dept. of Neurology, College of Medicine, Hanyang University, Haeng Dang-Dong 17, Seoung Dong-Ku, Seoul 133, Korea. 02) 293-3111.*

worse. Three months before admission, urinary and fecal incontinence had developed and headache and gait disturbance had been aggravated.

On admission, vital signs were within normal limit; blood pressure was 100/70 mmHg, body temperature 36.8°C, heart rate 88/min, respiratory rate 20/min. Her body weight and length were 50 Kg and 147 cm respectively. Her head circumference, 56 cm, was within 95 percentiles.

Physical examinations were unremarkable. There was no alteration of her level of consciousness. Dysarthria and nasal voice were noted. Cranial nerve examinations were normal except slight blurring of both discs' margins. Romberg test was negative. Finger to nose test was abnormal. Truncal ataxia and dysidiadochokinesia were also noted. During walking, she dragged her right foot and her right fingers, wrist, and elbow were flexed, and there was loss of associate movements of both upper extremities. Sensory function was normal. There was right hemiparesis. Muscle tone and deep tendon reflexes were increased in all four extremities. Ankle clonus was noted on both sides. Babinski sign was present on right side. Results of the routine laboratory tests including simple chest film were within normal limits.

Plain skull film revealed diffuse thinning of the calvarium, increased convolitional markings, widening of the sella turcica, and erosions of the anterior and posterior clinoid processes, but there was no widening of the sutures (Fig. 1).

An axial computed tomogram of brain showed dilated ventricles except the fourth. Round hyperdense mass, about 4.5 cm in diameter, was located behind the third ventricle in the midline, which was extended into the level of pons. After contrast enhancement, it was enhanced markedly and homogeneously. There were also smaller multiple hyperdense masses, suggesting calcifications, in both basal ganglia. And these were more numerous in the left side. There were irregular, serpiginous vessel like hyperdensities which were enhanced homogeneously around these as well. Straight sinus was enlarged slightly (Fig. 2).

Left internal carotid angiogram showed arteriovenous malformations which were fed by lenticulostriate arteries in the basal ganglia. Contrast dye was drained rapidly into an aneurysm of the vein of Galen through anomalous veins in early arterial phase. The anomalous veins formed by union of the two to three large veins were con-

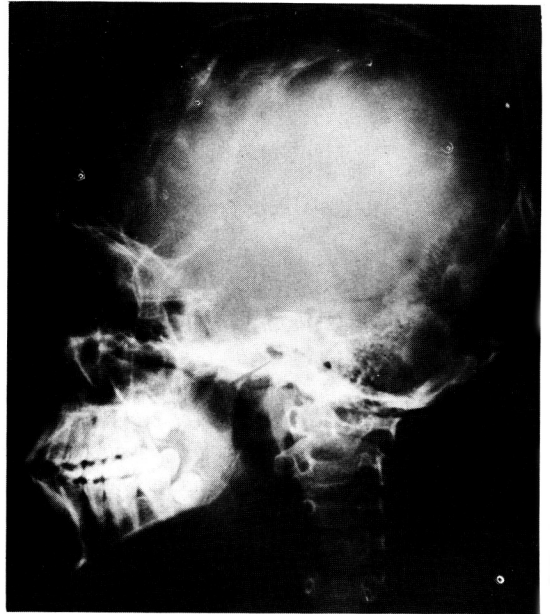


Fig. 1. The plain skull lateral view.

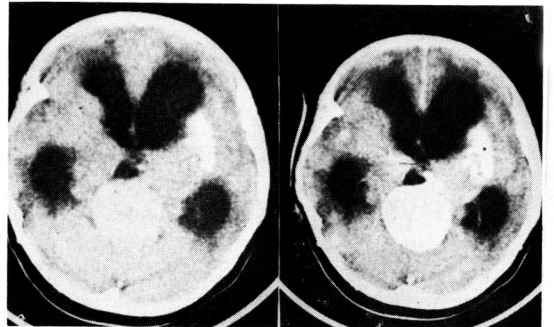


Fig. 2. The precontrast (left) and postcontrast (right) CT scan.

nected to an aneurysm of the vein of Galen in the shape of letter "Z" (Fig. 3). Right internal carotid angiogram revealed similar findings. But the size of arteriovenous malformations, feeding arteries, and draining veins was smaller than that of the left side. On vertebral angiography, posterior choroidal and thalamoperforating arteries were also feeding the arteriovenous malformations. Straight sinus was enlarged slightly (Fig. 4).

## DISCUSSION

The older Europeans classified intracranial vas

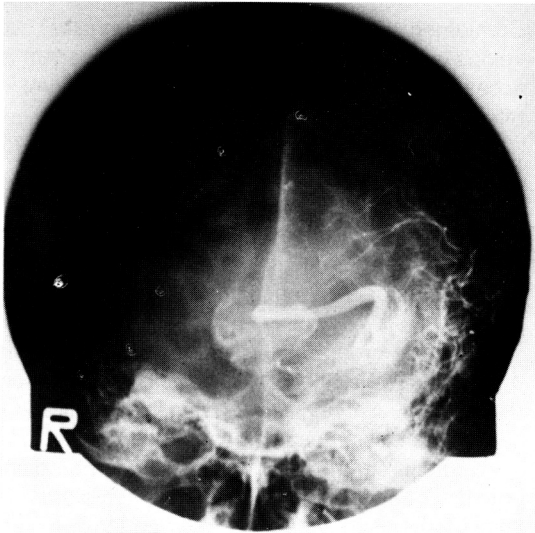


Fig. 3. The left internal carotid angiogram, anteroposterior view.

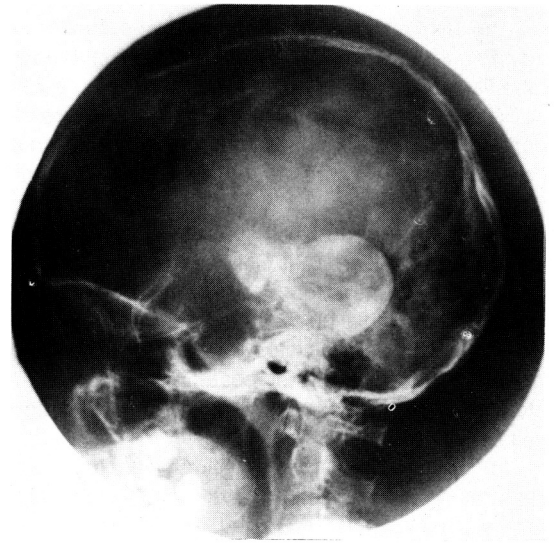


Fig. 4. The left vertebral angiogram, lateral view.

cular malformations into four major categories: angioma cavernosum, angioma racemosum, angioreticuloma, and angioliopoma. The arteriovenous malformations belonged to the first group, angioma cavernosum (Bergstrand et al., 1936; French and Chou, 1969). In the mean time McCormic (1966) proposed the more clinically based classification into five pathological types: telangiectasia, varix, cavernous angioma, arteriovenous malformation, venous angioma.

The arteriovenous malformation, most common intracranial vascular malformation only second to the aneurysm, refers to a congenital maldevelopment of blood vessels. It consists of one or more persisting primitive direct communication between arterial inflow and venous outflow without an intervening capillary beds. According to Krayenbuhl and Yasargil (1958), it was apparently recognized by the Egyptians as early as 1500 B.C..

The vein of Galen is located in the sagittal plane just within and behind the transverse cerebral fissure. It is formed by union of the internal cerebral veins and the basal vein just above the pineal body. After an upward transverse of 10 mm or so, it penetrates the junction of the falx and the tentorium, uniting with the inferior sagittal sinus, drains into the straight sinus. In general, Galenic system undertakes the venous drainage from the medial deep nuclei, the medial temporal and occipital lobes, and the superior surface of the cerebellum.

Although it was Steinheil (1895) who made an initial reference to an aneurysm of the vein of Galen, Jaeger et al. (1937) were credited with the first comprehensive descriptors of this condition and its treatment.

Litvak et al. (1960) made a clear distinction between primary and secondary types. While the clinical syndrome produced by primary and secondary type aneurysm of the vein of Galen may be identical, the surgical treatment is different for each type. So they put the great stress on the precise identification of types.

In primary type, the arteries feed directly into the aneurysm. The arterial feeders are usually large. But, in some cases, there are numerous small arterial feeders. This type belongs to "straight-line" AVM (type III) of Parkinson and Bachers (1980). Occlusion of all arterial feeders will obliterate the shunt and allows for collapse of an aneurysm. So it is unnecessary to excise the aneurysm.

In secondary type, the dilated vein of Galen serves as the venous drainage from an adjacent angioma. It is equal to "multi-unit" AVM (type I) of Parkinson and Bachers (1980). Usually the angioma is situated in the medial posterior hemisphere, the superior cerebellum, the brainstem, or the deep ganglionic structures. The sagittal and straight sinus are frequently dilated in secondary type. And angioma excision is the principle of therapy.

The explanation mentioned above is supported by Padget's theory. According to Padget (1956), the fistulas that give rise to an aneurysm of the vein of Galen occur between vessels of the choroidal origin including branches of the anterior, middle, and posterior cerebral and superior cerebellar arteries.

Our case belonged to secondary type in which an aneurysm of the vein of Galen served as the venous outflow from arteriovenous malformations located in the medial deep nuclei bilaterally. The arterial feeders consisted of lenticulostriate, thalamoperforating, and posterior choroidal arteries. And there was a slight dilatation of straight sinus, too.

In 1947, Oscherwitz and Davidoff were the first to approach an aneurysm of the vein of Galen intracranially. Two years later, Boldrey and Miller used the clipping of posterior cerebral artery to deal with an aneurysm of the vein of Galen. In 1959, Silverman *et al.* first noticed that congestive heart failure could be resulted from an aneurysm of the vein of Galen in a neonate.

In 1964, Gold *et al.* reported that clinical features are different depending upon the age of patient. The characteristics of clinical features corresponding to the age of the patient at presentation are as follows:

**1) Neonatal group:** Almost universally, they present at or shortly after birth congestive heart failure with concomitant cyanosis, rapid growth of head circumference, and continuous cranial bruit. Almost all of them are fatal in spite of intensive cardiac care. According to Amacher and Schillito (1973), all died within 7.5 weeks after birth.

In 1974, Norman and Becker described the post-mortem findings of brain in seven neonates with this lesion; Five cases had periventricular leukomalacia, Two had antenatal cerebral infarction, And three had recent hemorrhagic infarction. In 1963, Gomez *et al.* suggested that these brain damages could be caused by steal phenomenon, cerebral ischemia due to congestive heart failure, hemorrhagic infarction caused by thrombosis within an aneurysm of the vein of Galen, and atrophy due to compression of adjacent tissue by dilated aneurysm itself. Norman and Becker proposed changes of cerebral blood flow caused by surgery as a fifth factor of brain damage.

**2) Infantile group:** Congestive heart failure may either exist or not. But it is rather mild and can be resolved with treatment or spontaneously.

Craniomegaly resulted from hydrocephalus develops with occasional bruits. It is very important to access the cardiac state before surgery. Shunt is often necessary.

**3) Childhood group:** Most cases discovered, have come to light during the investigation of craniomegaly, in some cases, of subarachnoid hemorrhage. There may be cardiomegaly as well. And cranial bruits are usually associated. In this group, prognosis depends upon the degrees of hydrocephalus.

**4) Mature group:** In this group, the aneurysms present in a variety of ways; subarachnoid hemorrhage, a pineal area mass and ring like calcification, syncopal attacks, headache, and hydrocephalus.

An aneurysm of the vein of Galen can be diagnosed by above mentioned clinical symptoms. In addition, high jugular venous oxygen tension, cardiomegaly in simple chest film, ring like calcification near the pineal gland in simple skull film (Amacher, 1973), and characteristic axial computed tomographic and angiographic findings make it very easy to diagnose this condition without difficulties. In 1974, Lazer reported that the aneurysm may not fill at angiography in case of complete thrombosis. According to Smith and Donat (1981), it may show angiographic "target sign" when the periphery of sac is thrombosed.

In 1982, Hoffman *et al.* reviewed the angiographic findings in 29 patients with an aneurysm of the vein of Galen. And they found four characteristic patterns: In the neonates, feeding vessels entered the aneurysm at its anterior and superior border. It consisted usually of both anterior cerebral arteries, the lenticulostriate arteries, the thalamoperforating arteries, and both anterior and posterior choroidal arteries. Sometimes superior cerebellar arteries were also involved. Predominantly in infants, entrance of feeding vessels was situated inferiorly and laterally. And one posterior choroidal artery was usual feeder. In infants and older children, the feeding vessels, one or both posterior choroidal arteries, and one or both anterior cerebral arteries, were situated anteriorly and superiorly. In older children, the feeding vessels were usually composed of angiomatous networks arising mainly from the posterior choroidal arteries and thalamoperforating arteries. The aneurysms were drained into the well visualized straight sinus and transverse sinuses. In our case, the angiographic findings were similar to that of older children.

Most previous literatures have printed rather

gloomy pictures about the prognosis of this disease. And they have been a therapeutic enigma. There are, nevertheless, some reasons for optimism. And modern investigation and management allows for satisfactory treatment in some cases.

As mentioned before, the surgeries for primary and secondary types are different. And the overall outcome depends upon the age at onset. In general, the younger the patient, the poorer the outcome. To achieve a good result, cardiac hemodynamics, hydrocephalus, blood loss during operation, and aftercare must be taken into a consideration before surgery.

## REFERENCES

- Amacher AL, Shillito J Jr.: *The syndromes and surgical treatment of aneurysms of the great vein of Galen. J Neurosurg 39: 89-98, 1973.*
- Bergstrand H, Olivercrona H, Tönnis W: *Gefäßmissbildungen und Gefäßgeschwülste des Gehirns. Georg Thieme Verlag, Leipzig, p181, 1936.*
- Boldrey E, Miller ER: *Arteriovenous fistula (aneurysm) of the great cerebral vein (of Galen) and circle of Willis; Report on two patients treated by ligation. Arch Neurol Psychiat 62: 778-783, 1949.*
- French LA, Chou SN: *Conventional methods of treating intracranial arteriovenous malformations. Prog Neurol Surg 3: 274-318, 1969.*
- Gold AP, Ransohoff JR, Carter S: *Vein of Galen malformation. Act Neurol Scand 40 (Suppl): 5-31, 1964.*
- Gomez MR, Whitten CF, Nolke A, Bernstein J, Meyer JS: *Aneurysmal malformation of the great vein of Galen causing heart failure in early infancy; Report of five cases. Pediatrics 31: 400-411, 1963.*
- Hoffman HJ, Chuang S, Hendrick EB, Humphreys RP: *Aneurysms of the vein of Galen. J Neurosurg 57: 316-322, 1982.*
- Jaeger JR, Forbes RP, Dandy WE: *Bilateral congenital cerebral arteriovenous communication aneurysm. Trans Am Neurol Assoc. 63: 173-176, 1973.*
- Krayenbuhl H, Yasargil MG: *Das Hirnaneurysma. Basel JR, Geirgy, p141, 1958.*
- Lazar ML: *Vein of Galen aneurysm: Successful excision of a completely thrombosed aneurysm in an infant. Surg Neurol 2: 22-24, 1974.*
- Litvak J, Yahr MD, Ransohoff J: *Aneurysm of the great vein of Galen and midline cerebral arteriovenous anomalies. J Neurosurg 17: 945-954, 1960.*
- McCormic WF: *The pathology of vascular (arteriovenous) malformations. J Neurosurg 24: 807-816, 1966.*
- Norman MG, Becker LE: *Cerebral damage in neonates resulting from arteriovenous malformations of the vein of Galen. J Neurol Neurosurg and Psychiat 37: 252-258, 1974.*
- Oscherwitz D, Davidoff LM: *Midline calcified intracranial aneurysm between occipital lobes; report of a case. J Neurosurg 4: 539-541, 1947.*
- Padgett DH: *The cranial venous system in man in reference to development, adult configuration, and relation to the arteries. Am J Anatomy 98: 307-355, 1956.*
- Parkinson D, Bachers G: *Arteriovenous malformations; Summary of 100 consecutive supratentorial cases. J Neurosurg 53: 285-299, 1980.*
- Rosenberg AW: *A vascular malformation drained by the great vein of Galen; Report of a case. Bull Los Angeles Neurol Soc 20: 196-199, 1955.*
- Silverman BK, Breckx T, Craig J et al.: *Congestive heart failure in the new born caused by cerebral A-V fistula. AM J Dis Child 89: 539-543, 1955.*
- Smith DR, Donat JF: *Giant arteriovenous malformation of the vein of Galen; Total surgical removal. Neurosurgery 8: 378-381, 1981.*
- Steinheil SO: *Ueber einen Fall von Varix aneurysmaticus im Bereit der Gehirngefoesse. Inaugural dissertation, Wurzburg, 1985, cited by Dandy WE: Arteriovenous aneurysm of the brain. Arch Surg 17: 190-243, 1928.*
- Wilkins RH, Rengachary SS: *Neurosurgery, vol. II, McGraw-Hill, New York, pp 1459-1465, 1985.*
- Yasargil MG, Antic J, Laciga r, Jain KK, Boone SC: *Arteriovenous malformations of vein of Galen; Microsurgical treatment. Surg Neurol 6: 195-200, 1976.*