

[ CASE REPORT ]

## Isolated Cerebral Vasculitis in the Unilateral Middle Cerebral Artery in a Case with SLE

Sho Takeshita, Toshiyasu Ogata, Jun Tsugawa and Yoshio Tsuboi

### Abstract:

A 47-year-old woman, who was diagnosed to have systemic lupus erythematosus (SLE), was admitted because she suffered a severe ischemic stroke three weeks after experiencing a transient attack of aphasia. Diffusion-weighted MRI revealed high intensity at the borderzone of the middle cerebral artery (MCA), while the proximal portion of the left MCA was occluded with its vascular wall enhanced by gadolinium. Intravenous methylprednisolone and heparin were administered without any symptomatic benefit. She developed severe right hemiparesis with aphasia. Isolated cerebral vasculitis in the large vessel has been rarely reported in SLE patients. The presence of an enhanced vascular wall in the MRI with gadolinium could support the diagnosis.

**Key words:** systemic lupus erythematosus, SLE, vasculitis, cerebral large artery, acute cerebral infarction

(Intern Med 59: 3225-3227, 2020)

(DOI: 10.2169/internalmedicine.4958-20)

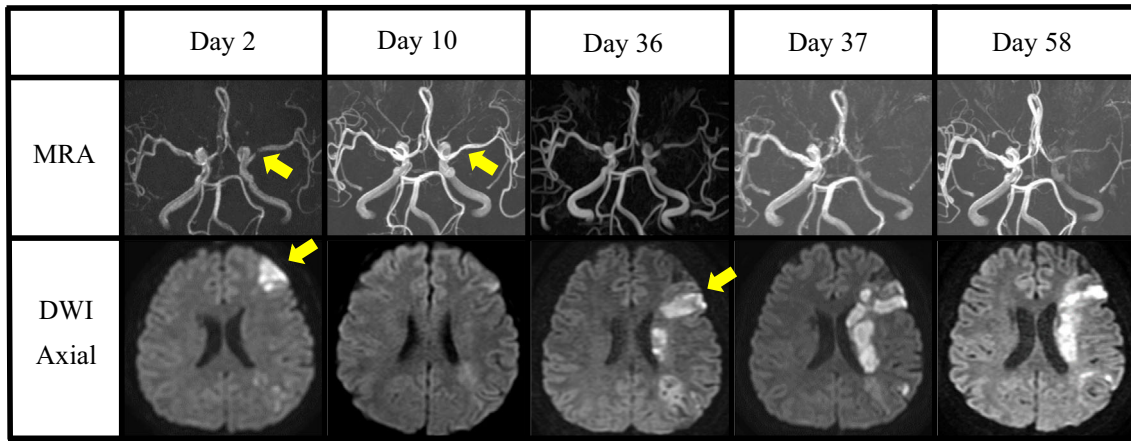
### Introduction

Systemic lupus erythematosus (SLE) is an autoimmune disease involving multiple organs, including the central nervous system (CNS). Neurological complications in patients with SLE are known as neuropsychiatric SLE (NPSLE). Brain ischemia due to CNS vasculitis has also occurred in such patients (1). Although vasculitis of the cerebral small-vessels is well known, such an occurrence in large-vessels has rarely been reported in SLE patients (2-5). We herein report a patient with SLE presenting with a progressive ischemic stroke due to vasculitis isolated in the unilateral middle cerebral artery (MCA).

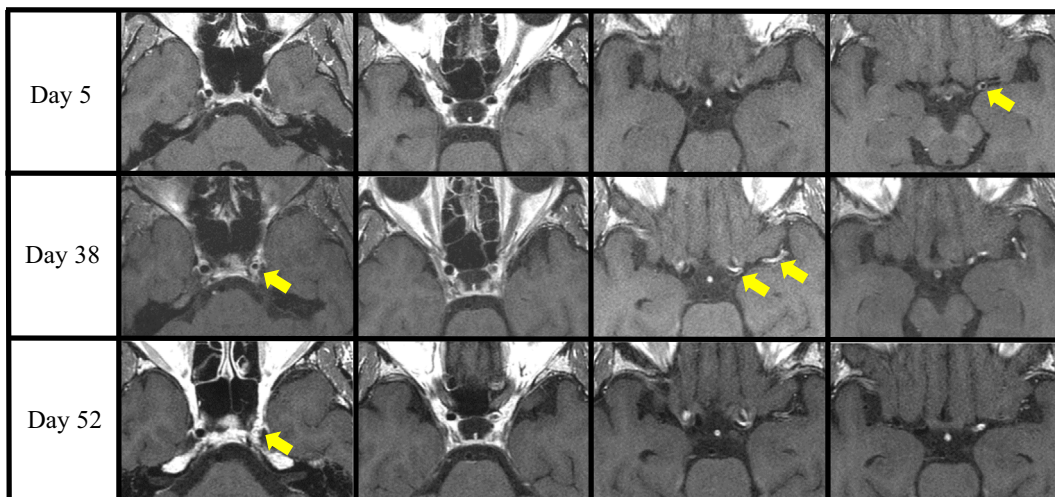
### Case Report

A 47-year-old woman was admitted to our emergency room because of sudden development of aphasia. She presented with photosensitivity, arthritis, anemia and proteinuria at 27 years of age and was diagnosed to have lupus nephritis [World Health Organization (WHO) type III] based on a renal biopsy, leading to the administration of intravenous methylprednisolone and subsequent oral glucocorticoid and

cyclosporine. Recently, she was administered 5 mg per day of oral prednisolone and here symptoms were well controlled. She had no family history of neurological disorders and no history of smoking nor any medical history of hypertension, diabetes mellitus, or dyslipidemia. A neurological examination on admission revealed non-fluent aphasia and mild weakness in the right arm, which was estimated as a score of 2 on the National Institute of Health Stroke Scale (NIHSS). MRI with diffusion-weighted imaging (DWI) identified high signal intensity at the border around the left MCA (Fig. 1). Magnetic resonance angiography (MRA) revealed stenosis in her left MCA (Fig. 1). A brain infarction was confirmed and oral cilostazol was initiated. The vascular wall of the left MCA was clearly enhanced on gadolinium-enhanced MRI, thus suggesting vascular wall inflammation, which thus led to a high suspicion of vasculitis. SLE-related inflammatory reactions such as fever, discoid rash, or cheek and lymph-node swelling were absent. Laboratory studies showed elevated white blood cell of  $14.2 \times 10^3/\mu\text{L}$ , C-reactive protein level of 4.09 mg/dL and erythrocyte sedimentation rate of 58 mm/hour with decrease level of hemoglobin of 9.6 g/dL. Platelet count of  $316 \times 10^3/\mu\text{L}$  were within the normal limits. An immunological test showed a positive finding for antinuclear antibodies of 26.6 by ELISA and double-



**Figure 1.** Time course of the MRI findings 2, 10, 36, 37, and 58 days after the first admission. Upper: Time-of-flight magnetic resonance angiography (TOF-MRA) of the cerebral arteries. Severe narrowing was observed in the proximal portion of the left middle cerebral artery (MCA) on day 2, which was improved on day 10 (arrow). On day 36 and thereafter, severe narrowing recurred with the distal arteries observed to be attenuated. Lower: Axial findings via diffusion weighted imaging (DWI). A small high intensity area (HIA) was found in her left frontal lobe on day 2 (arrow). On day 36, other HIAs were detected in her frontal lobe (arrow) in addition to her corona radiata and parietal lobe, indicating the recurrence of a brain infarction.



**Figure 2.** The time course of contrast-enhanced T1-CUBE findings 5, 38, 52 after the first admission. Day 5: The proximal portion of her left MCA exhibited vascular wall thickness with enhancement (arrow). Day 38: The vascular wall thickness and enhancement extended from the cervical portion of her internal carotid artery (ICA) to the horizontal portion of MCA (arrows). Day 52: Her left ICA had strong enhancement with obvious wall thickening (arrow). MCA: middle cerebral artery

stranded DNA antibodies of 23.8 IU/mL. Anti SS-A/SS-B antibodies, anti-neutrophil cytoplasmic antibody, anti-cardiolipin antibody test and a lupus anticoagulant test were negative. The levels of serum complements including CH50 (58 U/mL; normal 32-58 U/mL), C3 (110 mg/dL; normal 73-138 mg/dL), and C4 (26 mg/dL; normal 11-31 mg/dL) were normal. The stenosis of the left MCA exhibited an improvement on day 10 and her neurological deficit disappeared. She was discharged from the hospital on day 17.

Three weeks later, she was again admitted due to transient motor aphasia and right facial palsy. DWI indicated an addi-

tional acute ischemic stroke around her left MCA (Fig. 1). MRA indicated that the left MCA was nearly completely occluded and gadolinium-enhanced MRI revealed thickening of the vascular wall from the cervical portion of the internal carotid artery (ICA) to the horizontal portion of the MCA (Fig. 2), indicating a progression of vasculitis leading to the left MCA occlusion. An examination revealed normal cerebrospinal fluid (CSF) without any oligoclonal bands, however, the interleukin-6 (IL-6) level of the cerebrospinal fluid was elevated (24.9 pg/mL; normal 0-4 pg/mL). The intravenous administration of methylprednisolone (1,000 mg/day, 3

days) with heparinization was initiated. However, her non-fluent aphasia and right hemiparesis worsened after two days, and her NIHSS score rose to 10. A re-examination via DWI revealed significant enlargement of the ischemic lesion in her left corona radiata. Therefore, treatment with a high dose of oral steroids and cyclophosphamide was initiated, and a follow-up study of CSF indicated the IL-6 level to have decreased to 2.9 pg/mL. However, her neurological deficits did not improve. She had severe motor aphasia and right hemiparesis and an NIHSS score of 15 on day 41. The imaging findings were unchanged, and she was transferred to another hospital for rehabilitation on day 62.

## Discussion

According to the American College of Rheumatology classification criteria, our case is classified as having cerebrovascular disease. It is reported that, among NPSLE patients, 30-40% are complicated with ischemic stroke. In addition, the three subtypes of vasculopathy are classified by neuroimaging analyses, including inflammatory-like lesions, small-vessel disease (SVD), and large-vessel disease (LVD). Among these, the most common type is SVD, which accounts for 60% of cases with NPSLE (2). SVD is an intrinsic disorder of the brain-perforating arteries, characterized by white matter and subcortical lesions of the brain. In contrast, LVD in cases with NPSLE is relatively rare. According to a previous article, 13% of cases with NPSLE have been classified to the LVD type (2). The cause of LVD in SLE cases may vary, including circulating lupus-anticoagulant, Libman-Sacks endocarditis, sepsis, atherosclerotic disease or vasculitis. Previously, MRA or cerebral angiography was performed for the evaluation of LVD vasculitis (3-5). On the other hand, contrast-enhanced MRI with the T1-CUBE sequence, which we used in this case, can clearly exhibit the thickening of the vessel wall with enhancement. These findings may provide evidence of inflammation in the vessel wall, thus indicating a diagnosis of cerebral vasculitis (6). In such cases of cerebral vasculitis, we believe the possible etiologies to include infection, giant-cell arteritis, granulomatosis with polyangiitis, Behçet disease, Sjögren syndrome and drug-induced arteritis. However, all of these etiologies were ruled out based on her clinical features and laboratory findings. Therefore, we concluded that the patient suffered from large vessel vasculitis in the central nervous system related to SLE when making the diagnosis (7).

Patients with LVD vasculitis related to SLE should undergo strong immunotherapy as early as possible, however, no useful biomarkers have been established for the early diagnosis or treatment efficacy. Although the effectiveness of rituximab therapy has been reported for the refractory neuropsychiatric lupus (8), there is little evidence that it would have any beneficial effect on the LVD vasculitis caused by

SLE. An increased level of IL-6 in cerebrospinal fluid could be a biomarker for the activity of NPSLE. It has been recognized that the IL-6 level has a strong association with a diagnosis of NPSLE, the activity of SLE vasculitis, clinical deterioration, and treatment response (9). In our case, an increased IL-6 level was obvious at the second hospitalization, thus indicating the activity of SLE vasculitis. Stroke could also have caused an elevation of IL-6 in our case (10). However, because there is no evidence of a disruption of the blood-brain barrier, such as increase of protein or albumin in the CSF, the elevation of IL-6 in our case most likely reflects the activity of SLE vasculitis. Our case suggests that increased CSF IL6 levels associated with vascular wall thickening and enhancement on contrast-enhanced MRI may suggest a possible diagnosis of SLE-associated LVD.

## Conclusion

We experienced a case of ischemic stroke with an occluded MCA due to SLE vasculitis. This case was an atypical NPSLE in that the patient demonstrated vasculitis of a large cerebral artery. The IL-6 levels in the CSF and gadolinium-enhanced MRI might play an important role in predicting the clinical course and treatment response.

**The authors state that they have no Conflict of Interest (COI).**

## References

1. Futrell N, Millikan C. Frequency, etiology, and prevention of stroke in patients with systemic lupus erythematosus. *Stroke* **20**: 583-591, 1989.
2. Sarbu N, Alobeidi F, Toledano P, et al. Brain abnormalities in newly diagnosed neuropsychiatric lupus: systematic MRI approach and correlation with clinical and laboratory data in a large multicenter cohort. *Autoimmun Rev* **14**: 153-159, 2015.
3. Bockle BC, Jara D, Aichhorn K, et al. Cerebral large vessel vasculitis in systemic lupus erythematosus. *Lupus* **23**: 1417-1421, 2014.
4. Weiner DK, Allen NB. Large vessel vasculitis of central nervous system in systemic lupus erythematosus: report and review of the literature. *J Rheumatol* **18**: 748-751, 1991.
5. Scharre D, Petri M, Engman E, et al. Large intracranial arteritis with giant cells in systemic lupus erythematosus. *Ann Intern Med* **104**: 661-662, 1986.
6. Kuker W. Cerebral vasculitis: imaging signs revisited. *Neuroradiology* **49**: 471-479, 2007.
7. Rodrigues M, Galego O, Costa C, et al. Central nervous system vasculitis in systemic lupus erythematosus: a case series report in a tertiary referral centre. *Lupus* **26**: 1440-1447, 2017.
8. Narváez J, Ríos-Rodríguez V, de la Fuente D, et al. Rituximab therapy in refractory neuropsychiatric lupus: Current clinical evidence. *Semin Arthritis Rheum* **41**: 364-372, 2011.
9. Hirohata S, Kanai Y, Mitsuo A, Tokano Y, Hashimoto H, Subcommittee NR. Accuracy of cerebrospinal fluid IL-6 testing for diagnosis of lupus psychosis. A multicenter retrospective study. *Clin Rheumatol* **28**: 1319-1323, 2009.
10. Beridze M, Sanikidze T, Shakarishvili R, et al. Selected acute phase CSF factors in ischemic stroke: findings and prognostic value. *BMC Neurol* **30**: 11-41, 2011.

The Internal Medicine is an Open Access journal distributed under the Creative Commons Attribution-NonCommercial-NoDerivatives 4.0 International License. To view the details of this license, please visit (<https://creativecommons.org/licenses/by-nc-nd/4.0/>).