



Diffuse Cerebral Vasospasm After Removal of a Posterior Fossa Hemangioblastoma in a 62-Year-Old Woman

Yusuke Kinoshita, Kenichi Sato, Tamio Ito, Hirohiko Nakamura

Key words

- Angiography
- Brain tumor
- Cerebrovascular stenosis
- Complications
- Cyst
- Postoperative

Abbreviations and Acronyms

CT: Computed tomography

MRA: Magnetic resonance angiography

Department of Neurosurgery, Nakamura Memorial Hospital, Sapporo, Japan

To whom correspondence should be addressed:

Yusuke Kinoshita, M.D.

[E-mail: kinoshita@e-mail.ne.jp]

Citation: *World Neurosurg.* (2020) 143:97-101.

<https://doi.org/10.1016/j.wneu.2020.07.137>

Journal homepage: www.journals.elsevier.com/world-neurosurgery

Available online: www.sciencedirect.com

1878-8750/\$ - see front matter © 2020 Elsevier Inc. All rights reserved.

INTRODUCTION

There are a variety of surgical complications that can occur in neurosurgery, depending on the surgical area being operated on and the surgical method used. These complications include neurologic deterioration because of brain ischemia, brain hemorrhage, contusion, and cranial nerve injury. Vasospasm is a common complication after subarachnoid hemorrhage,¹ but is extremely rare after tumor removal, especially in the posterior fossa. Most publications on this topic are case reports.²⁻¹⁴ Herein, we report a case of vasospasm that occurred after the removal of a posterior fossa hemangioblastoma.

CASE DESCRIPTION

A 62-year-old Asian woman visited our hospital complaining of dizziness and nausea for 1 month. Her medical history was only significant for hypertension. Neurologic findings showed that she was alert, with no paresis, and a mild left-sided

■ **BACKGROUND:** The development of diffuse cerebral vasospasm after the removal of a brain tumor is extremely rare. We report a case of cerebral vasospasm after the removal of a posterior fossa hemangioblastoma.

■ **CASE DESCRIPTION:** A 62-year-old woman presented with a 1-month history of vertigo and nausea. Neurologic examination revealed that she was alert, with no paresis, and a mild left-sided cerebellar ataxia. Contrast-enhanced magnetic resonance imaging showed a cystic lesion with a strongly enhancing nodule, measuring 20 × 26 mm in diameter, in the cerebellar dorsal vermis. Angiography revealed that the lesion had feeding arteries from the left posterior inferior cerebellar artery. A diagnosis of hemangioblastoma was suspected and surgery was performed. On the first postoperative day, paresis of the right-sided extremities occurred. Diffusion-weighted imaging showed a high-intensity area in the medial side of the left frontal lobe. Magnetic resonance angiography indicated diffuse cerebrovascular stenosis. Considering these findings to be caused by vasospasm, we started the treatment used for vasospasm secondary to aneurysmal subarachnoid hemorrhage. Magnetic resonance angiography on the 13th postoperative day revealed an improvement in the cerebrovascular stenosis. In this case, it appears that the cause of vasospasm was intraoperative spillage of the contents of the cyst.

■ **CONCLUSIONS:** Although the occurrence of diffuse cerebral vasospasm after the removal of brain tumors in the posterior fossa is rare, this complication should be noted as a potential postoperative complication after tumor removal; this should lead to earlier diagnosis and treatment and a potentially better prognosis.

cerebellar ataxia. Contrast-enhanced magnetic resonance imaging showed a cystic lesion with a strongly enhancing nodule, measuring 20 × 26 mm in diameter, in the cerebellar dorsal vermis (Figure 1A and B). Angiography revealed a lesion with feeding arteries from the left posterior inferior cerebellar artery (Figure 1C and D). A posterior fossa hemangioblastoma was suspected to be the most likely diagnosis. Whole body examinations were performed that revealed no hemangioblastoma in any other areas, including the spine, retina, kidney, or pancreas. The patient was not diagnosed with von Hippel-Lindau syndrome, but was rather thought to have a sporadic hemangioblastoma, and she proceeded to surgery a week after admission.

Surgery

The patient was placed in the prone position under general anesthesia. A straight midline skin incision was performed from a point 2 cm cranial to theinion down to the C4 level. A suboccipital craniotomy was performed with an opening of the foramen magnum. After opening the dura, a cyst was identified between the cerebellar vermis and tonsils. The cyst was initially opened, revealing cystic fluid that was colorless and transparent (Figure 2A). There was a red nodule buried in the medial side of the cerebellar hemisphere (Figure 2B). A plane was created between the nodule and the cerebellar parenchyma, and the coagulation of feeding vessels was performed meticulously. Total removal

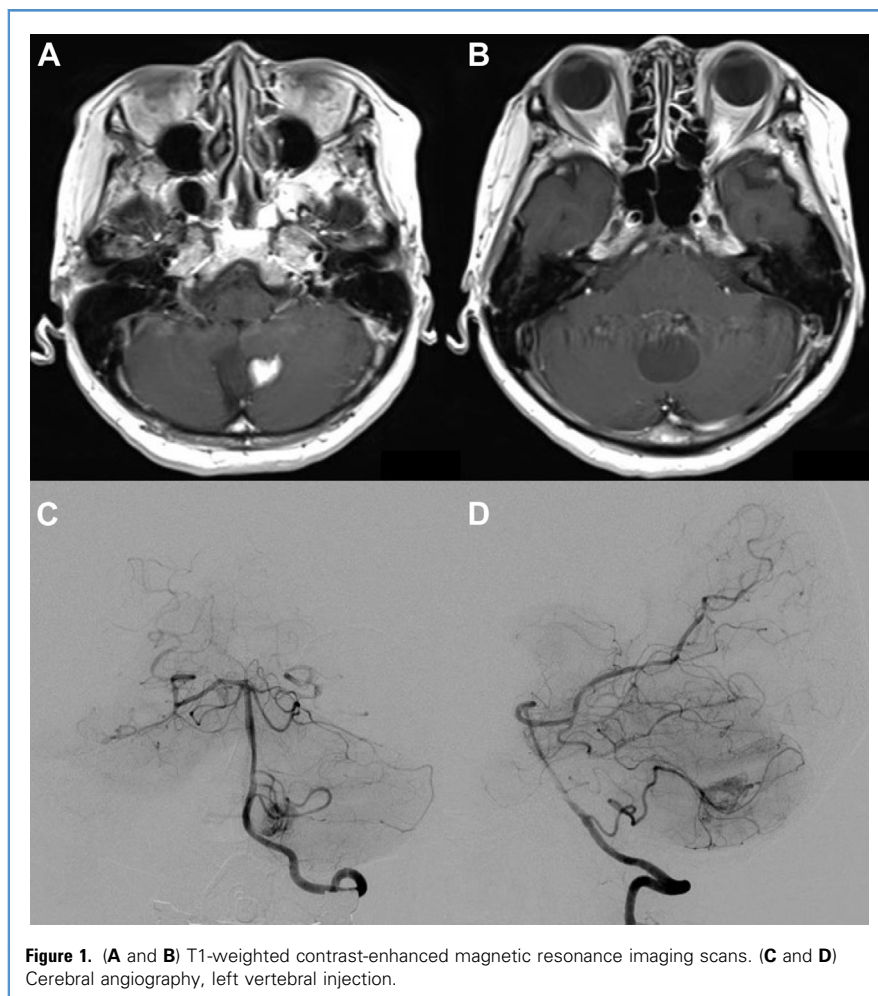


Figure 1. (A and B) T1-weighted contrast-enhanced magnetic resonance imaging scans. (C and D) Cerebral angiography, left vertebral injection.

was confirmed using indocyanine green video angiography (Figure 2C). Blood in the surgical field was washed out as much as possible. It was confirmed that there was no significant bleeding after extraction. Postoperative computed tomography (CT) scan revealed no hemorrhage (Figure 3). Pathology confirmed that the lesion was a hemangioblastoma (Figure 4).

Postoperative Course

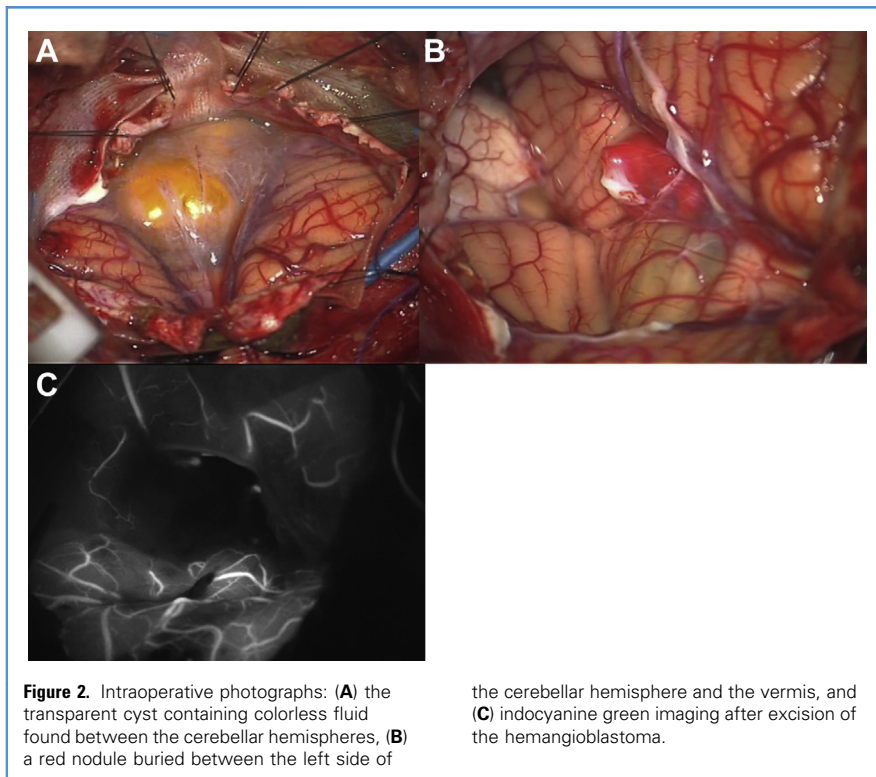
The patient developed hemiparesis in the right-sided extremities on the first postoperative day. Diffusion-weighted imaging showed a high-intensity lesion in the left side of the motor area of the brain (Figure 5B). Magnetic resonance angiography (MRA) revealed diffuse stenosis in the bilateral anterior cerebral and middle cerebral arteries, when

compared with the preoperative MRA (Figure 5A and C). We presumed that these findings were caused by an artifact resulting from intracranial air. Intravenous heparin was administered because we suspected the patient had suffered a cardiac embolism; however, cardiac examination could not identify an embolic source. Meningitis was unlikely because of the patient's normal body temperature, stable white blood cell and C-reactive protein levels, and normal cerebrospinal fluid findings. The patient's left-sided hearing deteriorated on the fourth postoperative day. She was diagnosed with vasospasm based on the MRA findings (Figure 5D). We commenced administration of fasudil hydrochloride hydrate 90 mg/day and low molecular weight dextran 500 cm³/day, and kept electrolytes and blood pressure within

normal ranges. In addition, we treated the patient with normovolemic, hemodilution therapy, which is our standard treatment protocol for aneurysmal subarachnoid hemorrhage. On the sixth postoperative day, a repeat MRA scan demonstrated slight improvements in the appearances of the vasospasm (Figure 5E), and CT perfusion imaging suggested only slight prolongation of the mean transit time in the left centrum semiovale (Figure 6). The vasospasm subsided on the 13th postoperative day (Figure 5F). Although the left-sided hearing loss persisted, she was discharged on the 30th postoperative day with no paresis in her extremities.

DISCUSSION

To our knowledge, this is the first report of diffuse vasospasm after the removal of a



hemangioblastoma in the posterior fossa. Bejjani et al.¹⁵ reported that vasospasm after skull base surgery occurred in 9 of 470 cases (1.9%). The average age of patients was 41 years. Most vasospasms occurred within 7 days, which was similar to the time frame of vasospasm seen in aneurysmal subarachnoid hemorrhage. There were many patients with tumors in the parasellar region, and a few patients with tumors in the posterior fossa. The possible causes of vasospasm include the direct stimulation of vessels, the influence on the

hypothalamus, and blood in the basal cisterns.

Alotaibi and Lanzino¹⁶ reported a systematic review of 40 cases. The mean time to develop clinical vasospasm was 8 days (range, 0–30 days). Seven out of the 40 patients (17.5%) had tumors in the posterior fossa. Full recovery was achieved in only 27.5% of the patients. Preoperative risk factors for vasospasm included the following: a tumor located in the sella turcica extending to the suprasellar region or in the middle fossa but not in the posterior fossa, and vessel

encasement or narrowing. Intraoperative risk factors were the following: pituitary tumor surgery, vessel manipulation, abnormal vascular reactivity (increased reactivity to norepinephrine, serotonin, and prostaglandins), and pathology and content spillage (dermoid cyst and craniopharyngioma). Postoperative risk factors included the following: blood in the subarachnoid space, hypothalamic dysfunction, electrolyte disturbance, and the development of meningitis.

Qi et al.¹⁷ evaluated vasospasm after the removal of acoustic neuromas, using transcranial Doppler ultrasonography. Vasospasm was detected in 43 out of 80 patients. The risk factors for the development of vasospasm were younger patient age, larger tumor size, and firmer tumor consistency. The authors emphasized that traction on brain structures should be minimized, and half of the patients showed vasospasm after the resection of acoustic neuromas.

Taking everything together, the risk factors of vasospasm after the removal of brain tumors appear to be the following: younger age, pathology, larger size, tumor location, the presence of encasement and

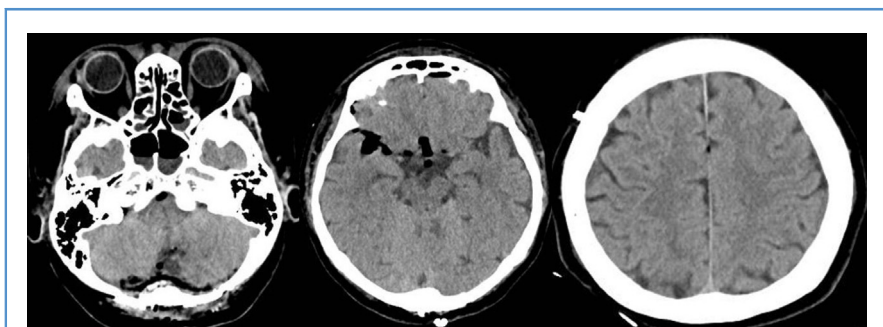


Figure 3. Postoperative computed tomography scan showed air but no blood in the basal cisterns.

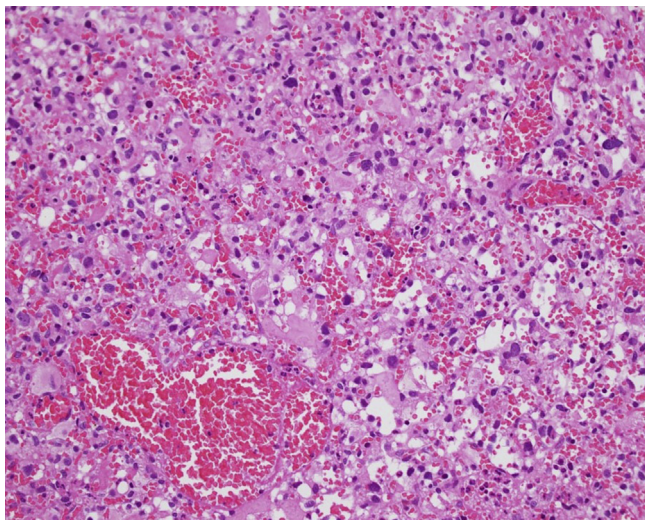


Figure 4. Histopathologic analysis (hematoxylin and eosin stain, $\times 200$ magnification) revealed proliferation of capillaries and stromal cells, with clear foamy cytoplasm and fine vacuoles.

displacement of vessels, and blood in the subarachnoid space. The treatment for vasospasm is the same as that of aneurysmal subarachnoid hemorrhage, including hyperdynamic therapy and the administration of calcium antagonists. In the present case, most of the blood left in the surgical field after the removal of the tumor was washed out. The postoperative

CT scan showed air but not blood in the basal cisterns. No direct manipulation of the supratentorial vessels was confirmed. Although there was no specific evidence to support the cause of vasospasm in the present case, we suspect that it was caused by spillage of the contents of the tumor cyst. In addition, there was possibility of a reflux of the internal solution because the

surgical field in the present case was close to the cisterna magna. Special attention must be given to ensure a complete washing with artificial cerebrospinal fluid or inflow of content fluid into the surgical field when operating on lesions with cystic components.

The main limitation of this report is the lack of a method to investigate the cause of the vasospasm. Hence, the generalizability of our findings is limited. Nevertheless, our report provides useful advice for the management of patients who develop vasospasm after the removal of brain tumors.

CONCLUSIONS

We describe a case of vasospasm after the removal of a hemangioblastoma in the posterior fossa. This is an extremely rare occurrence but should be noted as a potential postoperative complication. Knowledge of the possibility of vasospasm occurrence after tumor removal is important and will lead to earlier diagnosis and treatment, and potentially better prognosis.

ACKNOWLEDGMENTS

The authors thank Editage for their assistance with English language editing.

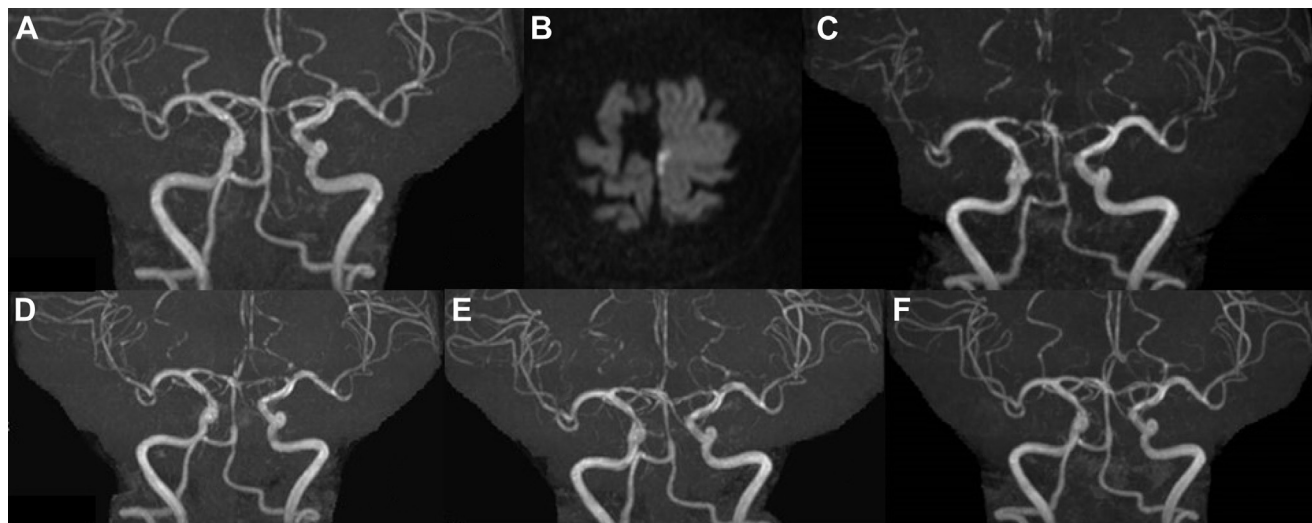

Figure 5. (A) Preoperative magnetic resonance angiography (MRA). (B) Diffusion-weighted imaging performed on the first postoperative day. (C) MRA on the first postoperative day. (D) MRA on the fourth postoperative day. (E) MRA on the sixth postoperative day. (F) MRA on the 13th postoperative day.

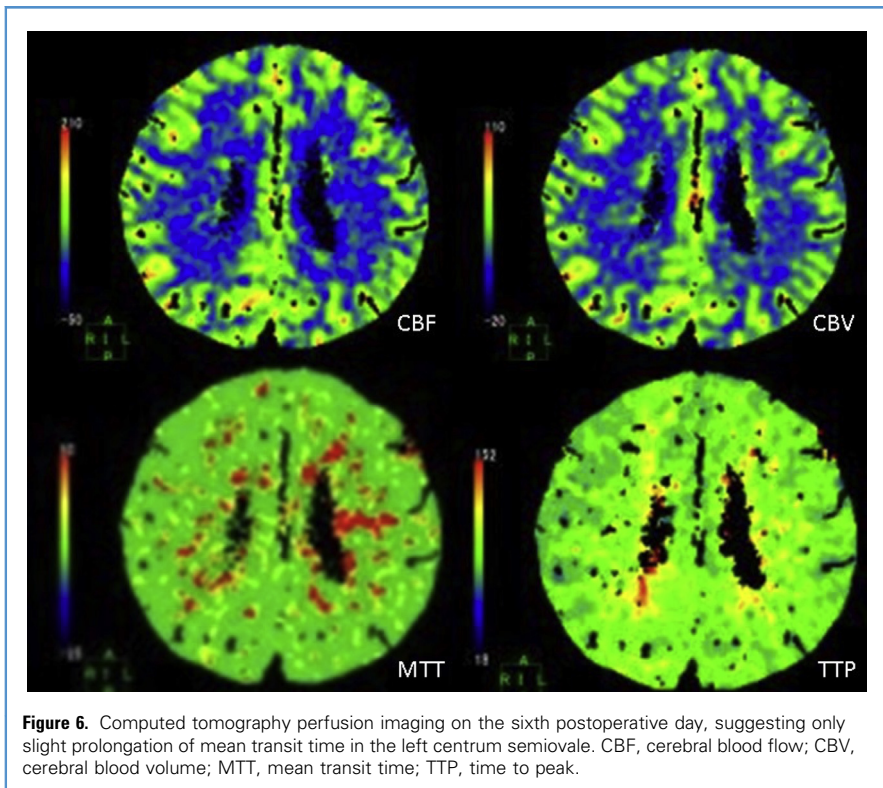


Figure 6. Computed tomography perfusion imaging on the sixth postoperative day, suggesting only slight prolongation of mean transit time in the left centrum semiovale. CBF, cerebral blood flow; CBV, cerebral blood volume; MTT, mean transit time; TTP, time to peak.

REFERENCES

1. Fisher CM, Roberson GH, Ojemann RG. Cerebral vasospasm with ruptured saccular aneurysm—the clinical manifestations. *Neurosurgery*. 1977;1: 245-248.
2. Ju C, Wright CH, Wright J, Duan Y, Bambakidis NC. Subarachnoid hemorrhage associated with intratumoral aneurysm rupture within a posterior fossa hemangioblastoma: the importance of continued surveillance for cerebral vasospasm. *Cureus*. 2017;9:e1606.
3. Qi J, Zhang L, Jia W, Zhang J, Wu Z. Diffuse cerebral vasospasm after resection of schwannoma: a case report. *Neuropsychiatr Dis Treat*. 2015;11: 317-320.
4. Prontera A, Puzzolante A, Carpeggiani P, Pavesi G. Symptomatic anterior cerebral artery vasospasm after brainstem hemangioblastoma resection. A case report. *Neuroradiol J*. 2014;27: 186-190.
5. Taussky P, Kalra R, Couldwell WT. Delayed vasospasm after removal of a skull base meningioma. *J Neurol Surg A Cent Eur Neurosurg*. 2012;73: 249-252.
6. Jacob JT, Hunt CH, Wijdicks EF, Rabinstein AA, Cloft H, Link MJ. Diffuse cerebral vasospasm after resection of a posterior fossa ependymoma. *Neurocrit Care*. 2011;14:86-90.
7. Aw D, Aldwaik MA, Taylor TR, Gaynor C. Intracranial vasospasm with delayed ischaemic deficit following epidermoid cyst resection. *Br J Radiol*. 2010;83:e135-e137.
8. Almubaslat M, Africk C. Cerebral vasospasm after resection of an esthesioneuroblastoma: case report and literature review. *Surg Neurol*. 2007;68: 322-328.
9. Bejjani GK, Duong DH, Kalamirides M, Ziyal I, Sullivan BJ. Cerebral vasospasm after tumor resection. A case report. *Neurochirurgie*. 1997;43: 164-168.
10. Kusunose M, Fukuda O, Saito T, Takaku A, Endo S. Diffuse cerebral artery vasospasm following total resection of posterior fossa meningioma: a case report [Japanese]. *No Shinkei Geka*. 1997;25:953-957.
11. LeRoux PD, Haglund MM, Mayberg MR, Winn HR. Symptomatic cerebral vasospasm following tumor resection: report of two cases. *Surg Neurol*. 1991;36:25-31.
12. de Almeida GM, Bianco E, Souza AS. Vasospasm after acoustic neuroma removal. *Surg Neurol*. 1985; 23:38-40.
13. Aoki N, Origiano TC, Al-Mefty O. Vasospasm after resection of skull base tumors. *Acta Neurochir (Wien)*. 1995;132:53-58.
14. Cervoni L, Salvati M, Santoro A. Vasospasm following tumor removal: report of 5 cases. *Ital J Neurol Sci*. 1996;17:291-294.
15. Bejjani GK, Sekhar LN, Yost AM, Bank WO, Wright DC. Vasospasm after cranial base tumor resection: pathogenesis, diagnosis, and therapy. *Surg Neurol*. 1999;52:577-583.
16. Alotaibi NM, Lanzino G. Cerebral vasospasm following tumor resection. *J Neurointerv Surg*. 2013; 5:413-418.
17. Qi J, Jia W, Zhang L, Zhang J, Wu Z. Risk factors for postoperative cerebral vasospasm after surgical resection of acoustic neuroma. *World Neurosurg*. 2015;84:1686-1690.

Conflict of interest statement: The authors declare that the article content was composed in the absence of any commercial or financial relationships that could be construed as a potential conflict of interest.

Received 10 June 2020; accepted 21 July 2020

Citation: *World Neurosurg*. (2020) 143:97-101.
<https://doi.org/10.1016/j.wneu.2020.07.137>

Journal homepage: www.journals.elsevier.com/world-neurosurgery

Available online: www.sciencedirect.com

1878-8750/\$ - see front matter © 2020 Elsevier Inc. All rights reserved.