



Pediatric Middle Cerebral Artery Occlusion with Dissection Following a Trampoline Trauma

Nimer Adeeb, Christopher Storey, Alexis J. Vega, Asala Aslan, Bharat Guthikonda, Hugo Cuellar-Saenz

Key words

- Aspirin
- Dissection
- Heparin
- Middle cerebral artery
- Pediatric
- Stroke
- Thrombectomy

Abbreviations and Acronyms

AIS: Acute ischemic stroke
CT: Computed tomography
ICA: Internal carotid artery
MCA: Middle cerebral artery
TICI: Thrombolysis in Cerebral Infarction

Department of Neurosurgery, Ochsner-Louisiana State University, Shreveport, Louisiana, USA

To whom correspondence should be addressed:
 Nimer Adeeb, M.D.

[E-mail: Nimer_adeeb@hotmail.com]

Citation: *World Neurosurg.* (2020) 143:428-433.
<https://doi.org/10.1016/j.wneu.2020.07.175>

Journal homepage: www.journals.elsevier.com/world-neurosurgery

Available online: www.sciencedirect.com

1878-8750/\$ - see front matter © 2020 Elsevier Inc. All rights reserved.

INTRODUCTION

The incidence of childhood stroke ranges from 1.3 to 13 per 100,000, with a mortality of approximately 3%–6% and up to 70% of survivors debilitated with significant deficits.¹ Because of this low incidence, there is a lack of evidence on the safety and efficacy of various initial therapies for acute ischemic stroke (AIS) in the pediatric population.² Mechanical thrombectomy, which has become a standard of care for large-vessel occlusion in adults, has not been included in guidelines for treating pediatric stroke owing to the lack of level 1 evidence.³ This has led to long-term management based on recommendations and expert opinion, which are typically based on treatment of the adult population. However, recent retrospective studies and multiple case reports have shown

■ **BACKGROUND:** Owing to the rarity of acute ischemic stroke in the pediatric population, evidence supporting the efficacy in children of the various treatments used in adults is scanty. This included mechanical thrombectomy for acute ischemic stroke.

■ **CASE DESCRIPTION:** we present the case of an 11-year-old female with acute left hemiparesis, numbness, and left facial droop occurring after tumbling on a trampoline. Computed tomography angiography revealed an 11-mm non-filling defect in the right middle cerebral artery. She underwent thrombectomy approximately 8.5 hours after the onset of symptoms, and a Thrombolysis in Cerebral Infarction (TICI) scale score of 2b was achieved. She had an uneventful postoperative recovery.

■ **CONCLUSION:** Pediatric patients likely have more reserve and collateral flow and benefit from a longer therapeutic window following acute ischemic stroke.

favorable outcomes with high recanalization rates in the pediatric population.^{2,4,5} Those previous studies evaluated different types of mechanical thrombectomy, including stent retrievers and aspiration.

Here we report a patient who underwent thrombectomy of the right middle cerebral artery (MCA) as a result of arterial dissection occurring after jumping on a trampoline, which was treated with a stent retriever.

CASE PRESENTATION

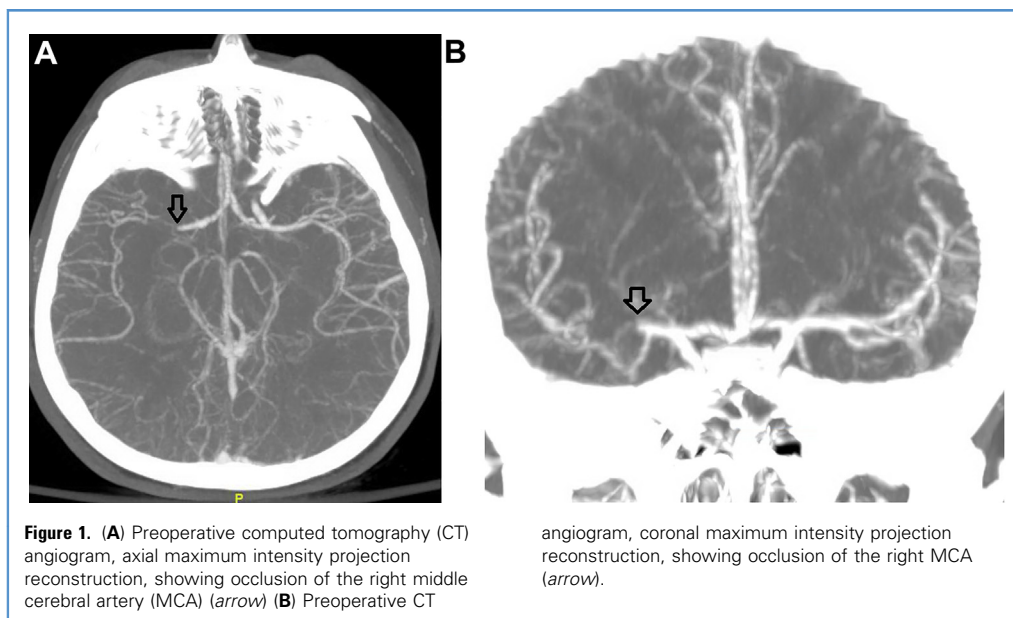
Diagnosis

The patient is a 11-year-old female who was jumping on a trampoline performing her usual tumbles when she felt she could no longer support herself with her left leg. She was carried inside for a bath and began experiencing left hemiparesis and numbness with left facial droop. She developed slurred speech and complained of right frontal headache. She was then brought to a hospital.

A computed tomography (CT) scan of the head done approximately 90 minutes after the onset of symptoms did not show any fracture or intracranial bleeding. The patient was emergently transferred to our center, where neurosurgery was consulted for possible spinal cord injury. The left facial droop noted on examination ruled out spinal cord injury. Out of concern for developing ischemic stroke, CT angiography was performed and showed an ~11-mm nonfilling defect of the M1-M2 segment of the right MCA (**Figure 1**). Because of her age, the patient was not a candidate for tissue plasminogen activator therapy; therefore, after discussion with her family, she was taken for thrombectomy.

Management

A 6 Fr sheath was placed, and a 6 Fr guide catheter was used to access the right internal carotid artery. The CT angiogram showed a delayed arterial phase indicating retrograde flow through collateral vessels and a string sign through the occlusion, suggesting a dissection with large-vessel occlusion (**Figure 2A and B**). The MCA territory



was receiving flow from leptomeningeal branches of the anterior cerebral artery. The superior M₃ MCA branch was cannulated with a microwire, and the true lumen was verified on injection. Using a stent retriever (Trevo; Stryker, Kalamazoo, MI), we were able to achieve a Thrombolysis In Cerebral Infarction (TICI) 2b revascularization at 8.5 hours after the onset of symptoms, but there appeared to be some remaining clot along the MCA (Figure 2C). Thus, 8 mg of tissue plasminogen activator was pushed intra-arterially, which revealed an intimal flap, narrowed lumen, and stagnation of contrast within the false lumen of the dissection (Figure 2D). No extracranial dissection was noted that could have propagated. An immediate postoperative CT showed an ASPECTS score of 9 with hypodensity in the right lenticular nucleus and no signs of hemorrhage.

The patient was started on a heparin drip with a target partial thromboplastin time of 40–60. The patient remained left hemiplegic immediately after thrombectomy. At ~5 hours after thrombectomy, she remained plegic in the left upper extremity, but had regained strength in left lower extremity to 4/5. On postoperative

day 2, she returned to 4/5 in her left upper extremity and 5/5 in her left lower extremity. Magnetic resonance angiography revealed no stenosis to the right MCA (Figure 3A). Magnetic resonance imaging showed a small temporal infarct (Figure 3B) and an infarct with some hemorrhagic conversion of the right corpus striatum. On postoperative day 3, the heparin drip was stopped, and she was started on enoxaparin. She was discharged home on postoperative day 5 on enoxaparin with a target anti-Xa value of 0.5–1 for 3 months.

Prognosis and Outcomes

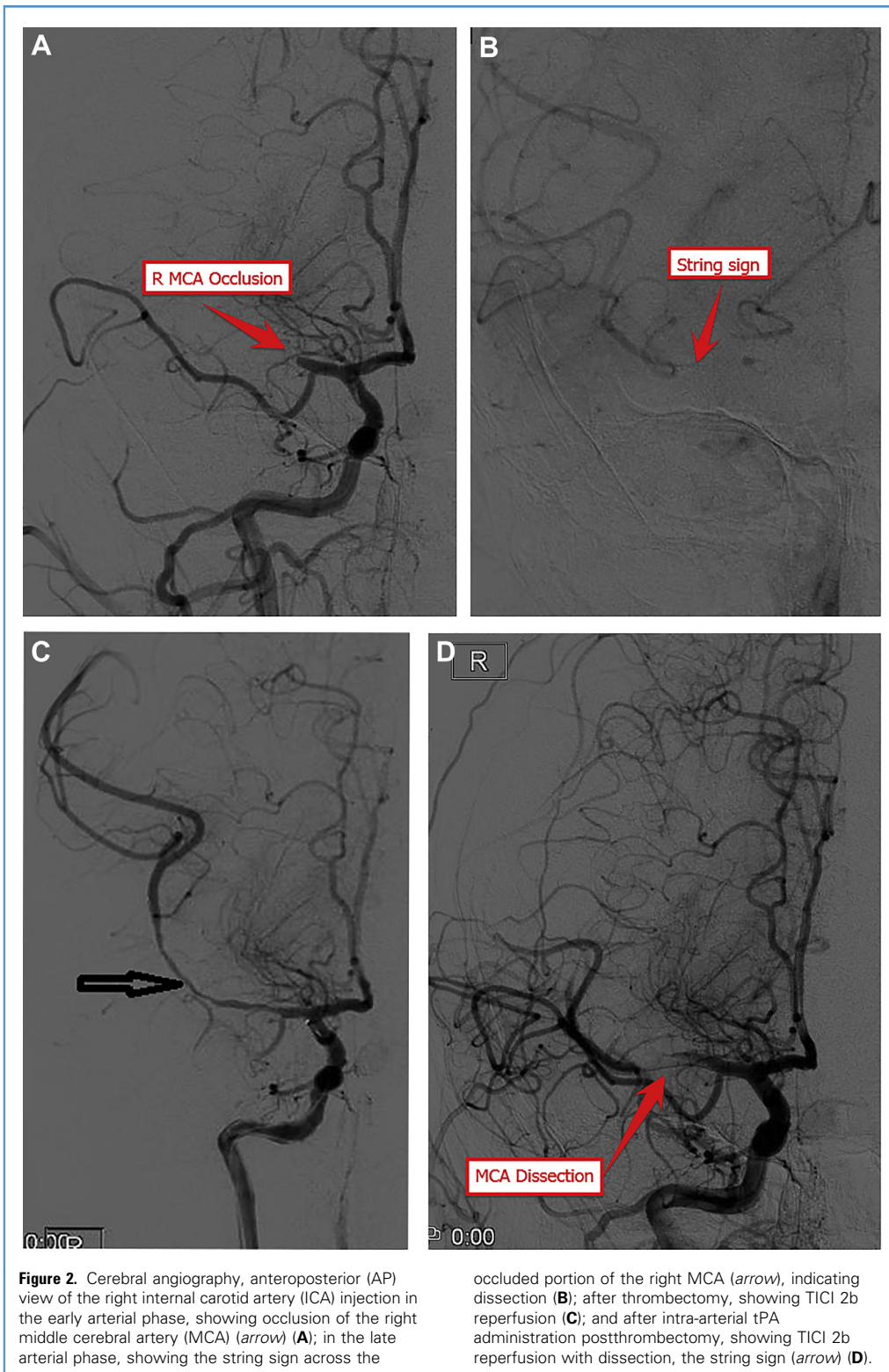
The patient did well, progressing with outpatient physical therapy, but due to problems with compliance with enoxaparin, she was switched to aspirin 325 mg after her coagulopathy workup was negative on postoperative day 15. Magnetic resonance angiography performed at 3 months and 1 year showed no signs of stenosis or dissection of the right MCA (Figure 3C). Magnetic resonance imaging revealed stable old initial infarcts without new hemorrhage or edema. Connective tissue disease was ruled out clinically as a possible etiology, given no family history and no other signs on physical examination. She initially had some

trouble returning to schoolwork, which improved with time. At 14 months, she was changed to aspirin 81 mg in stable condition with minimal left-sided deficits.

DISCUSSION

Here we present the case of an 11-year-old female who sustained an AIS. This was a unique presentation of an MCA dissection with large vessel occlusion occurring after trampoline jumping. Using a stent retriever, we were able to achieve a TICI score of 2b at 8.5 hours after the onset of symptoms. For an adult patient, treatment would have included a self-expanding stent across the dissection to prevent propagation of the intimal flap. However, in pediatric patients, the required antiplatelet regimen would have sentenced them to a lifelong risk of stroke due to lack of compliance. Instead, we chose to administer an immediate heparin drip followed by a short course of enoxaparin followed by aspirin. On follow-up imaging, the flap had resolved, and the patient has had no further ischemic events.

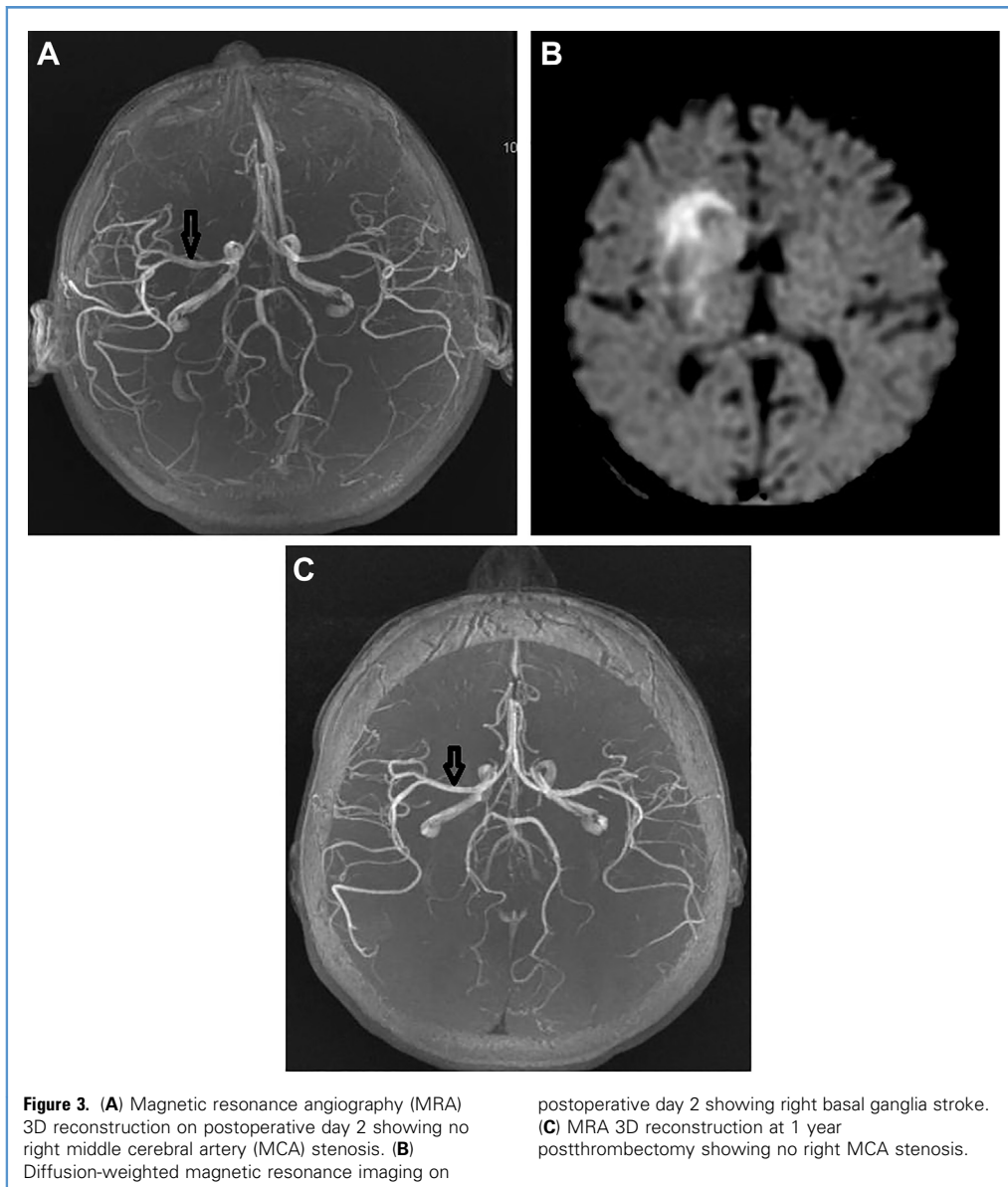
A review of the literature identified 20 case reports of pediatric patients with AIS in the anterior circulation who underwent



thrombectomy with a stent retriever (Table 1).⁶⁻²² Only initial revascularization attempts were analyzed. Overall, the

median time from symptom onset to revascularization was 5 hours; 6 out of 16 patients (37.5%) had recanalization

beyond 6 hours due to delayed diagnosis. The mean time of reperfusion for TIC1 2b or better was 5 hours. Six of the 14



patients (42.9%) who achieved a TIC1 of 2b or better were outside of the 6-hour window suggested for mechanical thrombectomy and without direct complications, likely due to better collateral flow in the pediatric population. Similarly, our patient had an impressive outcome after achieving TIC1 2b at 8.5 hours. Hemiplegia resolving to a pronator drift overnight validated her good collateral flow. Resolution of the drift and affect changes demonstrates the remarkable plasticity of pediatric patients in healing after stroke.

The risk of hemorrhagic conversion after thrombectomy is widely reported in the literature, with concerns that it might increase with increasing time between stroke onset and reperfusion; however, a recent study by Boisseau et al²³ showed no significant correlation.

The current literature suggests that mechanical thrombectomy may be considered for AIS due to large vessel occlusion (internal carotid artery terminus, M1, basilar artery) in patients age 1–18 years (level C evidence; class IIb recommendation).⁵

With continued research and more evidence, mechanical thrombectomy may one day become a standard of care.

CONCLUSIONS

As shown in this case, dissection in pediatric patients due to trauma may be safely treated with enoxaparin and aspirin after mechanical thrombectomy. Mechanical thrombectomy has been shown to be beneficial in the adult AIS population with an extended window. Pediatric patients

Table 1. Reports of Pediatric Large Vessel Occlusion Thrombectomy Using Stent Retrievers

Study	Age (years)	NIHSS Score	Vessels	Etiology	Device	TICI Scale	Medications	Time from Symptom Onset to Intervention (hours)
Alnaami et al., 2013 ⁶	8	>9~	MCA	Cardiac	Solitaire	3	Heparin	1.5
Sainz de la Maza et al., 2014 ⁷	12	18	ICA	Dissection	Solitaire	2b	NA	8
Hu et al., 2014 ⁸	9	16	MCA, ICA	Cardiac	Solitaire*	2a	NA	NA
Hu et al., 2014 ⁸	7	17	MCA, ICA	Infection	Solitaire*†	2a	NA	NA
Stidd et al., 2014 ⁹	2	mRS 4‡	MCA	Cardiac, hematologic	Trevo	2b	Heparin, warfarin	7
Bodey et al., 2014 ¹⁰	15	21	MCA	Unknown	Solitaire	NA	Heparin, aspirin	6
Rhee et al., 2014 ¹¹	9	6	ICA, MCA, ACA	Cardiac	Solitaire	3	Aspirin, dipyridamole, heparin	7
Van den Wijngaard et al., 2014 ¹²	14	21	MCA	Cardiac	Solitaire	2b	NA	5
Vega et al., 2015 ¹³	11	16	MCA	Cardiac	Trevo*	3	Aspirin	3
Mittal et al., 2015 ¹⁴	17	12	MCA	Cardiac	Solitaire	2a	NA	NA
Chung et al., 2016 ¹⁵	4	16	MCA	Cardiac	Solitaire	3	NA	5
Buompadre et al., 2017 ¹⁶	8	7	ACA/MCA	NA	Trevo	2b	Heparin dipyridamole	5
Kulhari et al., 2017 ¹⁷	9	7	MCA	Cardiac	Trevo	3	Dabigatran	8.5
Stowe et al., 2018 ¹⁸	9	23	MCA	Cardiac	Trevo	2b	Heparin, warfarin	4.5
Kim et al., 2018 ¹⁹	14	2	ICA, MCA	Intracranial arteriopathy	Trevo	NA	NA	8.4
Bhagal et al., 2018 ²⁰	17	9	ICA	NA	pRESET/Lite	2b	NA	7.4
Bhagal et al., 2018 ²⁰	11	2	MCA	NA	Prowler/Solitaire	3	Heparin, aspirin	5.9
Bhagal et al., 2018 ²⁰	16	15	MCA	NA	ReFlex/Solitaire	2b	Aspirin	4
Souto Silva et al., 2019 ²¹	4	14	MCA	Cardiac	Trevo	2b	Warfarin	3.5/4
Gervais et al., 2020 ²²	16	13	ICA, MCA, ACA	Cardiac	Solitaire	NA	Aspirin, heparin	NA

NIHSS, National Institutes of Health Stroke Scale; TICI, Thrombolysis in Cerebral Infarction; MCA, middle cerebral artery; ICA, internal carotid artery; NA, not applicable; ACA, anterior cerebral artery.
 *Penumbra-assisted.
 †Balloon angioplasty performed.
 ‡Modified Rankin Scale score.

should be directly incorporated into the expanded window not only because of their better collateral flow and fewer comorbidities, but also because of their likely delayed diagnosis. In addition, because pediatric patients have better neuroplasticity and collateral flow, they can achieve dramatic improvements from a TICI 2b reperfusion. The plasticity of the pediatric brain must also be considered for thrombectomy treatment, where a larger core infarct may be a candidate.

REFERENCES

- Gumer LB, Del Vecchio M, Aronoff S. Strokes in children: a systematic review. *Pediatr Emerg Care.* 2014;30:660-664.
- Satti S, Chen J, Sivapatham T, Jayaraman M, Orbach D. Mechanical thrombectomy for pediatric acute ischemic stroke: review of the literature. *J Neurointerv Surg.* 2017;9:732-737.
- Goeggel Simonetti B, Cavelti A, Arnold M, et al. Long-term outcome after arterial ischemic stroke in children and young adults. *Neurology.* 2015;84:1941-1947.
- Sporns PB, Kemmling A, Hanning U, et al. Thrombectomy in childhood stroke. *J Am Heart Assoc.* 2019;8:e011335.
- Bhatia K, Kortman H, Blair C, et al. Mechanical thrombectomy in pediatric stroke: systematic review, individual patient data meta-analysis, and case series [e-pub ahead of print]. *J Neurosurg Pediatr* <https://doi.org/10.3171/2019.5.PEDS19126>, accessed September 1, 2020.
- Alnaami I, Buchholz H, Ashforth R, et al. Successful use of Solitaire FR for stroke in a pediatric ventricular assist device patient. *Ann Thorac Surg.* 2013;96:e65-e67.

7. Sainz de la Maza S, De Felipe A, Matute MC, et al. Acute ischemic stroke in a 12-year-old successfully treated with mechanical thrombectomy. *J Child Neurol.* 2014;29:269-273.
8. Hu YC, Chugh C, Jeevan D, Gillick JL, Marks S, Stiefel MF. Modern endovascular treatments of occlusive pediatric acute ischemic strokes: case series and review of the literature. *Childs Nerv Syst.* 2014;30:937-943.
9. Stidd DA, Lopes DK. Successful mechanical thrombectomy in a 2-year-old male through a 4-French guide catheter. *Neurointervention.* 2014;9:94-100.
10. Bodey C, Goddard T, Patankar T, et al. Experience of mechanical thrombectomy for paediatric arterial ischaemic stroke. *Eur J Paediatr Neurol.* 2014;18:730-735.
11. Rhee E, Hurst R, Pukenas B, et al. Mechanical embolectomy for ischemic stroke in a pediatric ventricular assist device patient. *Pediatr Transplant.* 2014;18:E88-E92.
12. van den Wijngaard I, Wermer M, van Walderveen M, Wiendels N, Peeters-Scholte C, Lycklama à Nijeholt G. Intra-arterial treatment in a child with embolic stroke due to atrial myxoma. *Interv Neuroradiol.* 2014;20:345-351.
13. Vega RA, Chan JL, Anene-Maidoh TI, Grimes MM, Reavey-Cantwell JF. Mechanical thrombectomy for pediatric stroke arising from an atrial myxoma: case report. *J Neurosurg Pediatr.* 2015;15:301-305.
14. Mittal SO, ThatiGanganna S, Kuhns B, Strbian D, Sundararajan S. Acute ischemic stroke in pediatric patients. *Stroke.* 2015;46:e32-e34.
15. Chung YS, Lee WJ, Hong J, Byun JS, Kim JK, Chae SA. Mechanical thrombectomy in cardiac myxoma stroke: a case report and review of the literature. *Acta Neurochir (Wien).* 2016;158:1083-1088.
16. Buompadre MC, Andres K, Slater LA, et al. Thrombectomy for acute stroke in childhood: a case report, literature review, and recommendations. *Pediatr Neurol.* 2017;66:21-27.
17. Kulhari A, Dorn E, Pace J, et al. Acute ischemic pediatric stroke management: an extended window for mechanical thrombectomy? *Front Neurol.* 2017;8:634.
18. Stowe RC, Kan P, Breen DB, Agarwal S. Mechanical thrombectomy for pediatric acute stroke and ventricular assist device. *Brain Dev.* 2018;40:81-84.
19. Kim ES, Mason EK, Koons A, Quinn SM, Williams RL. Successful utilization of mechanical thrombectomy in a presentation of pediatric acute ischemic stroke. *Case Rep Pediatr.* 2018;2018:5378247.
20. Bhogal P, Hellstern V, AlMatter M, et al. Mechanical thrombectomy in children and adolescents: report of five cases and literature review. *Stroke Vasc Neurol.* 2018;3:245-252.
21. Souto Silva R, Rodrigues R, Reis Monteiro D, et al. Acute ischemic stroke in a child successfully treated with thrombolytic therapy and mechanical thrombectomy. *Case Rep Neurol.* 2019;11:47-52.
22. Gervelis WL, Golomb MR. Mechanical thrombectomy in pediatric stroke: report of three new cases. *J Stroke Cerebrovasc Dis.* 2020;29:104551.
23. Boisseau W, Fahed R, Lapergue B, et al. Predictors of parenchymal hematoma after mechanical thrombectomy: a multicenter study. *Stroke.* 2019;50:2364-2370.

Conflict of interest statement: The authors declare that the article content was composed in the absence of any commercial or financial relationships that could be construed as a potential conflict of interest.

Received 2 July 2020; accepted 26 July 2020

*Citation: World Neurosurg. (2020) 143:428-433.
https://doi.org/10.1016/j.wneu.2020.07.175*

Journal homepage: www.journals.elsevier.com/world-neurosurgery

Available online: www.sciencedirect.com

1878-8750/\$ - see front matter © 2020 Elsevier Inc. All rights reserved.