

[ CASE REPORT ]

## Cerebral Infarction and Myalgia in a 75-year-old Man with Eosinophilic Granulomatosis with Polyangiitis

Yuki Ueta<sup>1</sup>, Yuki Akiba<sup>1</sup>, Jun Yamazaki<sup>1</sup>, Yoshihiko Okubo<sup>2</sup>, Takeshi Taguchi<sup>1</sup>, Hiroo Terashi<sup>2</sup>, Yukiko K. Hayashi<sup>3</sup> and Hitoshi Aizawa<sup>2</sup>

### Abstract:

Eosinophilic granulomatosis with polyangiitis (EGPA) is a rare condition of systemic vasculitis of small to medium-sized blood vessels. We herein report the case of a 75-year-old man who presented with hemiplegia on his right side due to cerebral infarction following myalgia and a high fever. He had no history of asthma or allergic rhinitis. He was diagnosed with EGPA based on the presence of eosinophilia, sinusitis suggested by magnetic resonance imaging, and muscle pathology. His hemiplegia improved rapidly after corticosteroid therapy. This case suggests that EGPA should be a differential diagnosis of cerebral infarction with myalgia and eosinophilia.

**Key words:** eosinophilic granulomatosis with polyangiitis (EGPA), Churg-Strauss syndrome, cerebral infarction, myalgia, muscle biopsy, corticosteroid therapy

(Intern Med 59: 3089-3092, 2020)

(DOI: 10.2169/internalmedicine.5099-20)

### Introduction

Eosinophilic granulomatosis with polyangiitis (EGPA, also known as Churg-Strauss syndrome) is a systemic necrotizing vasculitis of small- to medium-sized vessels with extravascular eosinophilic infiltration (1, 2). EGPA is clinically characterized by asthma, a history of allergy, neuropathy, pulmonary infiltrates, and abnormalities of paranasal sinuses (2). Remission induction therapy for EGPA includes corticosteroids with immunosuppressant drugs, such as cyclophosphamide and rituximab (3, 4). However, without the characteristic features, a diagnosis of EGPA is difficult.

We herein report a patient with cerebral infarction following myalgia and a high fever due to EGPA, which was suggested by a muscle biopsy. His clinical symptoms improved rapidly after corticosteroid therapy.

### Case Report

A 75-year-old man who was undergoing treatment for hyperlipidemia and hypertension complained of a high-grade

fever and myalgia in the limb girdle muscles for the past 10 days. He had a history of esophageal and colon cancer. There was no history of asthma or allergic rhinitis. He was admitted four days after his first visit to our hospital.

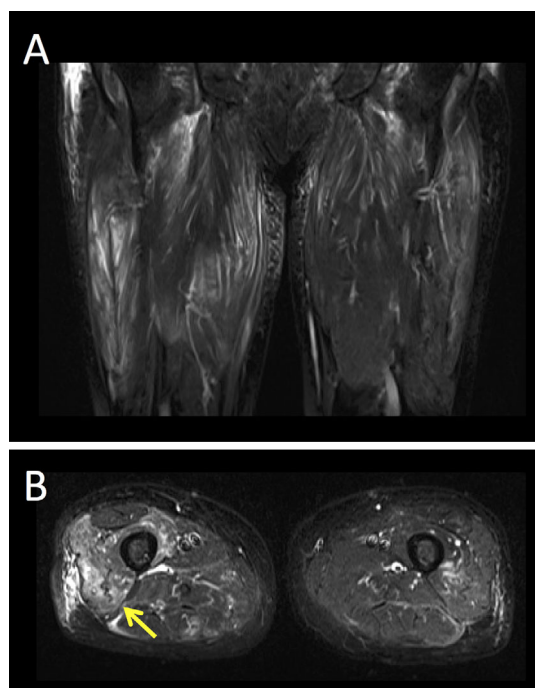
An initial physical examination revealed the following: his blood pressure was 112/74 mmHg, pulse rate 108 beats per minute, and body temperature 38.4°C. He had no skin rashes or enlargement of cervical lymph nodes. A neurological examination revealed muscle weakness of Medical Research Council (MRC) Muscle scale grade 4 in the bilateral deltoid and iliopsoas muscles with myalgia. There were no additional physical or neurological abnormalities.

The level of serum creatine kinase was 632 IU/L. The peripheral blood leukocyte count was 20,100/μL with eosinophilia (8,744/μL; 43.5% leukocytes). The serum levels of C-reactive protein (CRP) and IgE were 7.35 mg/dL and 2,240 IU/L, respectively. The electrolyte levels and renal function were within the normal ranges. The plasma level of D-dimer was 0.87 μg/mL. The patient was negative for perinuclear anti-neutrophil cytoplasmic antibodies, and no hematological malignancies were suggested from the bone marrow or cytogenetic testing. Cytogenetic testing excluded the presence of

<sup>1</sup>Department of Neurology, Tokyo Medical University Hachioji Medical Center, Japan, <sup>2</sup>Department of Neurology, Tokyo Medical University, Japan and <sup>3</sup>Department of Pathophysiology, Tokyo Medical University, Japan

Received: April 16, 2020; Accepted: June 21, 2020; Advance Publication by J-STAGE: August 4, 2020

Correspondence to Dr. Yuki Ueta, yukiueta@tokyo-med.ac.jp

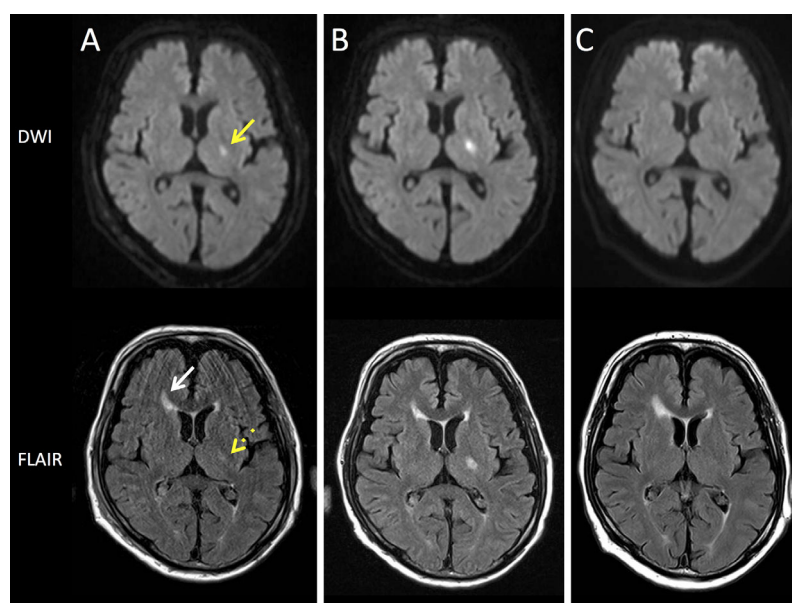


**Figure 1.** Short-tau inversion recovery magnetic resonance imaging of the bilateral thigh muscles. A) A coronal image reveals high-signal lesions scattered in the bilateral thigh muscles. B) An axial image reveals high-signal lesions in the right vastus lateralis (arrow).

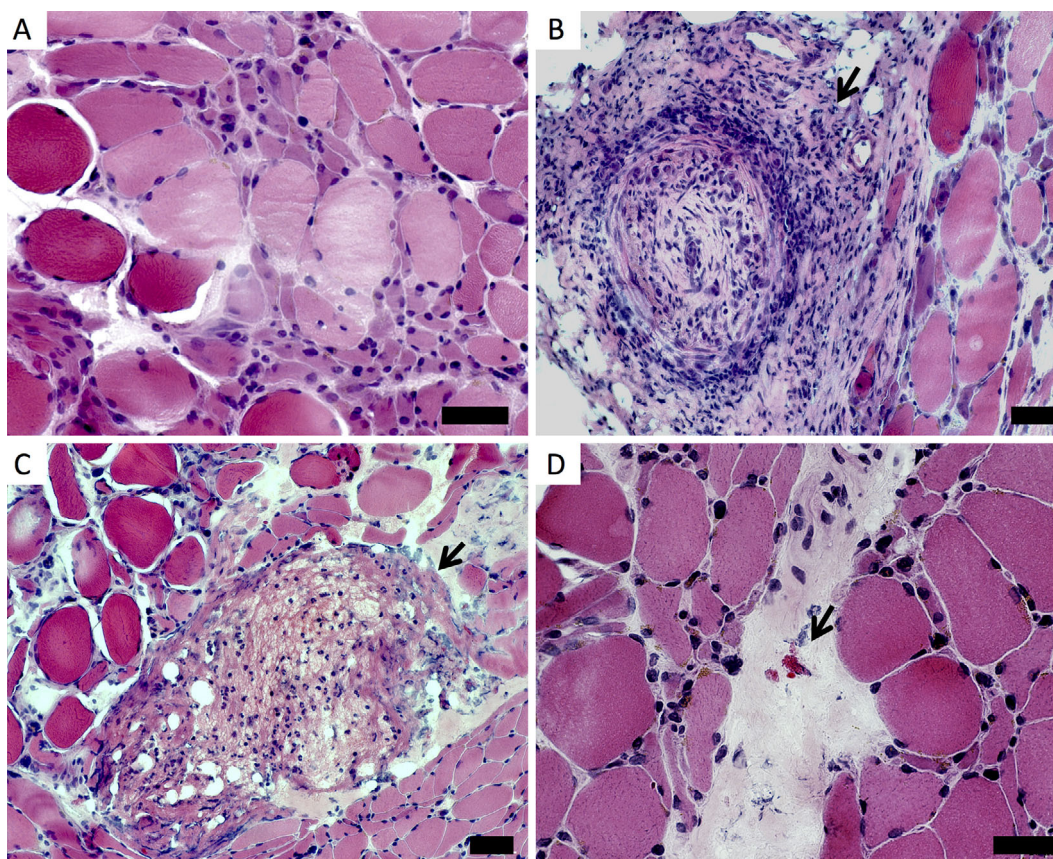
deletions in the chromosome 4q12 region and translocations involving the *PDGFRA* or *FGFR1* genes, both of which have been reported in patients with myeloid or lymphoid neoplasms with eosinophilia.

Computed tomography showed no sign of pulmonary infiltration. Short-tau inversion recovery (STIR) magnetic resonance imaging (MRI) revealed high signal lesions scattered in the bilateral thigh muscles (Fig. 1A), including the right vastus lateralis (Fig. 1B). Nerve conduction studies were normal for the right median, ulnar, fibular, tibial, and sural nerves. Electromyography of the left iliopsoas muscle revealed low-amplitude motor unit potentials with normal recruitment and no spontaneous activity.

Four days after admission, hemiplegia appeared suddenly on the patient's right side. His muscle strength was grade 2 in the right arm and grade 1 in the right leg based on the MRC scale. His tendon reflexes slightly increased in the right extremities, with indifferent plantar reflexes in the bilateral feet. Laboratory tests revealed elevated CRP (11.3 mg/dL) and D-dimer (3.05  $\mu\text{g/mL}$ ) levels. Brain diffusion-weighted imaging (DWI)-MRI revealed a fresh infarction in the left posterior limb of the internal capsule (Fig. 2A) with a decreased apparent diffusion coefficient (ADC) value. Fluid-attenuated inversion recovery (FLAIR) MRI revealed a hyperintense lesion in the left posterior limb of the internal



**Figure 2.** Changes in magnetic resonance imaging (MRI) of the brain. The upper and lower panels show diffusion-weighted imaging (DWI) and fluid-attenuated inversion recovery (FLAIR) MRI, respectively. A) On day 4 after hospital admission, DWI reveals a fresh infarct in the left posterior limb of the internal capsule (yellow arrow). FLAIR MRI reveals a high-signal lesion in the left posterior limb of the internal capsule and the white matter around the anterior horn of the right lateral ventricle (white arrow). The signal intensity of the lesion in the left posterior limb of the internal capsule on the FLAIR MRI is weak (yellow dotted arrow). B) Six days after starting oral corticosteroid therapy, DWI and FLAIR MRI show that the high-signal lesion in the left posterior limb of the internal capsule is clearer than on the first MRI scan. C) Ten months after starting oral corticosteroid therapy, the originally high-signal lesion in the left posterior limb of the internal capsule is barely detectable.



**Figure 3.** Frozen tissue sections from the muscle biopsy of the right vastus lateralis stained with Hematoxylin and Eosin staining. **A)** Many degenerating fibers and grouped small fibers are observed. **B)** Inflammation and obstruction of a blood vessel in the muscle specimen (arrow). **C)** One extravascular granuloma is observed (arrow). **D)** Eosinophils are scattered within fibrous tissues (arrow). Bar: 50  $\mu$ m

capsule and the white matter around the anterior horn of the right lateral ventricle (Fig. 2A). In addition, T2-weighted MRI revealed mucosal thickening in the ethmoid and bilateral maxillary sinuses, which suggested the presence of sinusitis. No stenoses or occlusions were observed in the cervicocephalic arteries using magnetic resonance angiography or carotid ultrasound. Electrocardiography and transthoracic echocardiography findings were normal. The patient was treated with aspirin (100 mg/day), cilostazol (200 mg/day), and edaravone (60 mg/day); however, the patient's right hemiplegia worsened.

On day 6 after admission, oral corticosteroid therapy (prednisone at 1 mg/kg/day) was begun, resulting in a dramatic improvement of right hemiplegia, muscle weakness, and myalgia within a few days. Six days after starting oral corticosteroid therapy, DWI and FLAIR MRI of the brain revealed a subacute lesion in the left posterior limb of the internal capsule (Fig. 2B) with a normal ADC value. T2-weighted MRI revealed an improvement of the mucosal thickening in the paranasal sinuses. STIR MRI on day 15 revealed that the lesions scattered in the bilateral thigh muscles still showed a high signal.

A muscle biopsy from the patient's right vastus lateralis was performed on day 30 (Fig. 3). Frozen sections that were

stained with Hematoxylin and Eosin showed many degenerating, pale-colored fibers and grouped smaller-sized fibers (Fig. 3A). Multiple mononuclear cell infiltrates were observed around and inside small-sized blood vessels, but not around the non-necrotic fibers (Fig. 3B). There was one extravascular granuloma (Fig. 3C), and eosinophils were scattered within interstitial fibrous tissues (Fig. 3D). There was no cellular infiltration within the fascia. These results were consistent with EGPA.

The patient's muscle weakness improved to grade 5 in his left side and grade 4 in his right side based on the MRC scale 5 days after starting corticosteroid therapy. The leukocytosis with eosinophilia and elevated CRP and D-dimer levels were also improved. The patient was prescribed prednisone at 0.4 mg/kg/day and discharged on day 49. On DWI and FLAIR MRI at 10 months after starting oral corticosteroid therapy, the previously observed high-signal lesion in the left posterior limb of the internal capsule was barely detectable (Fig. 2C).

## Discussion

EGPA is a rare form of vasculitis, and its prevalence in Japan is 17.8 per million adults. The median age at the on-

set is 59.7 (range, 49.8-70.4) years old, and more than 64% of the patients are women (5). We reported a 75-year-old man who presented with myalgia and cerebral infarction due to EGPA, which was suggested by a muscle biopsy. His clinical symptoms improved rapidly after corticosteroid therapy.

Neurological complications are common in EGPA, but cerebral infarction is much less frequent than neuropathy, being observed in 3-10% of patients with EGPA (6-8). The mechanism underlying cerebral infarction due to EGPA is uncertain; however, an autopsy case of EGPA reported that cerebral infarction was due to cerebral vasculitis with infiltration of eosinophils and embolism from a cardiac thrombus (9). Granule proteins, such as eosinophilic cationic protein, major basic protein, or eosinophil-derived neurotoxin, can lead to hypercoagulability and damaged cells (10-12). Although our patient's D-dimer level was elevated at the onset of cerebral infarction, the rapidly improved hemiplegia observed after corticosteroid therapy suggested the presence of cerebral vasculitis. Our patient presented with cerebral infarction without peripheral neuropathy. Some previous case reports have described ischemic stroke without peripheral neuropathy in patients with EGPA (13, 14). However, the difference in the mechanisms of vasculitis between the central nervous system and peripheral nerve in EGPA is uncertain.

Of note, the patient reported here had presented with a high fever, myalgia with weakness of proximal limb muscles, and eosinophilia when he visited our clinic, all of which are common symptoms of EGPA (7, 15). EGPA was also suggested from a muscle biopsy that revealed necrotizing vasculitis, scattered eosinophils, and extravascular granuloma. A previous report stated that a muscle biopsy demonstrated definite and probable vasculitis in 18% and 35% of patients with systemic vasculitic neuropathy, respectively (16). As the early diagnosis of EGPA is important but difficult, a muscle biopsy may be helpful for patients who present with some of the major clinical manifestations of EGPA together with myalgia or muscle weakness.

In conclusion, EGPA should be considered in the differential diagnosis of cerebral infarction in patients with myalgia and eosinophilia. A muscle biopsy may aid in the diagnosis in such patients. An early diagnosis and prompt administration of corticosteroids or other immunosuppressant drugs may improve the prognosis of cerebral infarction in EGPA.

Written informed consent was obtained from the patient for the publication of the case history and the accompanying images.

**The authors state that they have no Conflict of Interest (COI).**

#### Financial Support

Dr. Hayashi was supported by the grant for Research on

Measures for Intractable Diseases from the Ministry of Health Labour and Welfare and by an Intramural Research Grant (29-4) for Neurological and Psychiatric Disorders of National Center of Neurology and Psychiatry.

#### References

- Jennette JC, Falk RJ, Bacon PA, et al. 2012 revised International Chapel Hill Consensus Conference Nomenclature of Vasculitides. *Arthritis Rheum* **65**: 1-11, 2012.
- Masi AT, Hunder GG, Lie JT, et al. The American College of Rheumatology 1990 criteria for the classification of Churg-Strauss syndrome (allergic granulomatosis and angiitis). *Arthritis Rheum* **33**: 1094-1100, 1990.
- Ntatsaki E, Carruthers D, Chakravarty K, et al. BSR and BHPR guideline for the management of adults with ANCA-associated vasculitis. *Rheumatology (Oxford)* **53**: 2309-2306, 2014.
- Yates M, Watts RA, Bajema IM, et al. EULAR/ERA-EDTA recommendations for the management of ANCA-associated vasculitis. *Ann Rheum Dis* **75**: 1583-1594, 2016.
- Saku A, Furuta S, Hiraguri M, et al. Longterm outcomes of 188 Japanese patients with eosinophilic granulomatosis with polyangiitis. *J Rheumatol* **45**: 1159-1166, 2018.
- Sehgal M, Swanson JW, DeRemee RA, Colby TV. Neurologic manifestations of Churg-Strauss syndrome. *Mayo Clin Proc* **70**: 337-341, 1995.
- Guillevin L, Cohen P, Gayraud M, Lhote F, Jarrousse B, Casassus P. Churg-Strauss syndrome. Clinical study and long-term follow-up of 96 patients. *Medicine (Baltimore)* **78**: 26-37, 1999.
- Wolf J, Bergner R, Mutallib S, Buggle F, Grau AJ. Neurologic complications of Churg-Strauss syndrome-a prospective monocentric study. *Eur J Neurol* **17**: 582-588, 2010.
- Hira K, Shimura H, Kamata R, et al. Multiple cerebral infarction diagnosed as eosinophilic granulomatosis with polyangiitis by autopsy. *BMC Neurol* **19**: 288, 2019.
- Fattahi P, Sheriff F, Narayanan NS, Greer DM, Schindler J. Thrombolysis for acute stroke in patients with vasculitis: case report and literature discussion. *Clin Neurol Neurosurg* **115**: 351-353, 2013.
- Gleich GJ, Frigas E, Loegering DA, Wassom DL, Steinmuller D. Cytotoxic properties of the eosinophil major basic protein. *J Immunol* **123**: 2925-2927, 1979.
- Durack DT, Sumi SM, Klebanoff SJ. Neurotoxicity of human eosinophils. *Proc Natl Acad Sci USA* **76**: 1443-1447, 1979.
- Kang DW, Kim DE, Yoon BW, Seo JW, Roh JK. Delayed diagnosis: recurrent cerebral infarction associated with Churg-Strauss syndrome. *Cerebrovasc Dis* **12**: 280-281, 2001.
- Cheng MJ, Huang PH, Liao PW, Chen JT, Chiang TR. Multiple cerebral and cerebellar infarcts as the first clinical manifestation in a patient with Churg-Strauss syndrome: case report and literature review. *Acta Neurol Taiwan* **21**: 169-175, 2012.
- Lanham JG, Elkon KB, Pusey CD, Hughes GR. Systemic vasculitis with asthma and eosinophilia: a clinical approach to the Churg-Strauss syndrome. *Medicine (Baltimore)* **63**: 65-81, 1984.
- Bennett DLH, Groves M, Blake J, et al. The use of nerve and muscle biopsy in the diagnosis of vasculitis: a 5 year retrospective study. *J Neurol Neurosurg Psychiatry* **79**: 1376-1381, 2008.

The Internal Medicine is an Open Access journal distributed under the Creative Commons Attribution-NonCommercial-NoDerivatives 4.0 International License. To view the details of this license, please visit (<https://creativecommons.org/licenses/by-nc-nd/4.0/>).