

Case Report

Dabigatran Reversal With Idarucizumab Preceding Thrombolysis in an Octogenarian Patient with Chronic Kidney Disease and Acute Stroke: A Case Report



Lina C. Laxamana, MD^a; Christian Oliver C. Co, MD^a; Jeryl Ritzi T. Yu, MD^a; Christianne V. Mojica, MD^a; Maria Adelaida M. Iboleon-Dy, MD^b; Alyssa Mae C. Domingo, RN^a; Karen Czarina S. Ilano, RN^a; and Ma Cristina Z. Macrohon-Valdez, MD^a

^aInstitute for Neurosciences, St. Luke's Medical Center- Global City, Manila, Philippines; and

^bHeart Institute, St. Luke's Medical Center- Global City, Manila, Philippines

ABSTRACT

Background and Purpose: Reversing the effect of dabigatran among patients with atrial fibrillation is important to normalize coagulation profile among patients who develop serious hemorrhage from any source. However, such intervention always has the potential to cause a prothrombotic state. Among patients suspected of ischemic stroke, Idarucizumab, may be administered preceding thrombolysis. This is a considerable option when given during the critical phase of revascularization.

Methods: We report the case of an 84-year old, male, banker, known hypertensive with chronic renal disease. He has non valvular atrial fibrillation receiving Dabigatran at 75 mg twice daily and presented with symptoms of right-sided weakness, right hemisensory loss, facial asymmetry, and slurring of speech equating to National Institute of Health Stroke Scale (NIHSS) of 5. After coming into the hospital for a suspected stroke, 3 hours and 25 minutes after symptoms, complete reversal of Dabigatran with Idarucizumab was administered and intravenous thrombolysis was initiated 271 minutes post ictus. There was immediate improvement of the right upper extremity weakness and dysarthria 30 minutes post infusion. At 13 days post ictus, the patient was discharged with minimal right central facial palsy and right arm drift (NIHSS 2). Brain CT scan post revascularization did not reveal any hemorrhage and anticoagulant Apixaban 2.5 mg

twice daily was started and maintained thereafter. Brain Magnetic Resonance Angiogram (MRA) showed complete recanalization of the left proximal MCA after 52 days.

Conclusion: Our case showed the effectiveness and safety of giving Idarucizumab followed by thrombolysis in Dabigatran-treated atrial fibrillation with ischemic stroke. Based on this case, the procedure can be performed in an elderly population with chronic kidney disease when administered close to the limit of threshold for thrombolysis. (*Clin Ther.* 2020;42:1840–1845) © 2020 Elsevier Inc.

Key words: dabigatran reversal, elderly, idarucizumab, stroke, thrombolysis.

INTRODUCTION

Patients with atrial fibrillation have been shown to benefit from non-vitamin K antagonists in several clinical trials of treatment and secondary prevention of stroke, venous thromboembolism, and systemic embolism. More importantly, compared with warfarin, non-vitamin K antagonists (also called novel or new oral anticoagulants) have shown similar efficacy and safety

Accepted for publication July 11, 2020

<https://doi.org/10.1016/j.clinthera.2020.07.006>

0149-2918/\$ - see front matter

© 2020 Elsevier Inc.

in atrial fibrillation and valvular heart disease,¹ with a lower risk of ischemic stroke, systemic embolism, major bleeding, and mortality among Asian subjects with nonvalvular atrial fibrillation.²

Dabigatran* is the first novel oral anticoagulant introduced in the market in 2010, and idarucizumab has been approved since 2015 to reverse dabigatran's effect in terms of life-threatening hemorrhage and in those promptly needing surgical interventions. Idarucizumab is a humanized monoclonal antibody fragment that noncompetitively binds 350 times more for dabigatran than Factor IIa.³ It has no effect on prothrombin-activating ability, platelet aggregation, or endogenous thrombin generation, and thus it has been believed to have no influence on coagulation cascade.^{4,5}

Considering the risk of ischemic vascular event because of inadequate anticoagulation, the specific and rapid effect of idarucizumab as an antidote for dabigatran, with no effect on coagulation cascade, may therefore allow the reversal of dabigatran activity in patients with hyperacute stroke for which intravenous thrombolysis can be performed.⁶ Although idarucizumab and recombinant tissue plasminogen activator (rtPA) have been universally utilized for dabigatran reversal and treatment of acute ischemic stroke, respectively, the combined process has not been considered a part of stroke guidelines. The effect of treatment (especially when approaching the upper limit of the window period for thrombolysis) has not been fully elucidated. Although there have been some claims regarding its safety in the elderly, reports are scarce.⁷ Moreover, this procedure has not been reported in patients with chronic kidney disease.

Management of blood pressure is a significant issue in acute ischemic events, whether in the early phase of the attack or following medical management, as it dictates the adequacy of cerebral blood flow in a hypoperfused region in the brain. If perfusion of the ischemic penumbra is not restored, injury becomes irreversible, leading to complete infarction.⁸ Therefore, cautious maintenance of hemodynamic stability must be made at all times by avoiding medications that will further lower blood pressure while ensuring recanalization within the

recommended period of rtPA administration of 3–4.5 h. Studies have shown the benefit of preventing the dreaded hemorrhagic complication from thrombolysis if rtPA is administered within 4.5 h. Among octogenarian patients, there was no significant difference in 90-day mortality, 30-day functional outcome, or rate of symptomatic intracerebral hemorrhage compared with non-octogenarian patients treated with intravenous TPA, and therefore it is a safe procedure.⁹ However, there are only rare reports regarding dabigatran reversal preceding intravenous thrombolysis among this population. The safety profile is still in question and, currently, there have been few discussions on this topic.

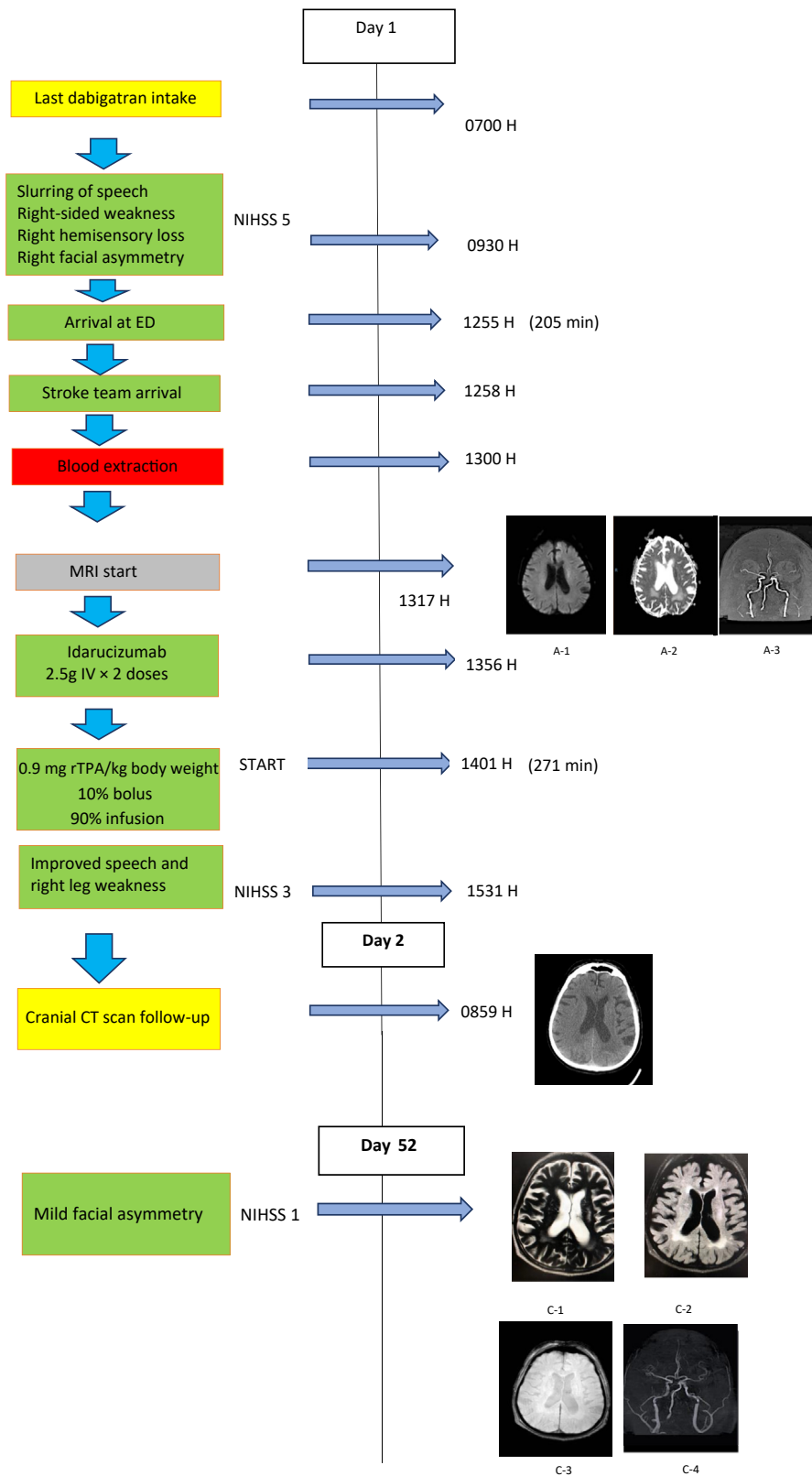
We report a case of a patient under treatment with dabigatran for nonvalvular atrial fibrillation presenting with acute ischemic stroke symptoms who received intravenous thrombolysis after idarucizumab administration. The history of rapid-acting antihypertensive medication intake before door time did not preclude the use of intravenous thrombolysis.

CASE REPORT

An 84-year-old man, who was a banker, very functional, and actively engaged in the job, came in to our institution with slurring of speech, right-sided weakness, and numbness with right facial asymmetry. He was hypertensive and had chronic renal disease, with a creatinine level of 2.6 mg/dL and a creatinine clearance of 19.38 mL/min. He also had macular degeneration and nonvalvular atrial fibrillation, and was compliant with dabigatran at 75 mg BID with last intake at 0700 H. The patient was doing well at work when he started to have right-sided facial asymmetry followed by slurring of speech, and then weakness and numbness of the right upper and lower extremities at 0930H. He was brought to the office clinic with recorded blood pressure of 140/100 mm Hg and was given sublingual clonidine 75 µg. There was neither improvement nor deterioration of his symptoms at that time. Subsequent blood pressure reading after 10 min was 150/100 mm Hg, for which he received another dose of clonidine 75 µg. Family urged him further until he finally agreed to go to the hospital, arriving at the emergency department at 1255 H.

On arrival, the patient's blood pressure was 150/90 mm Hg, and atrial fibrillation was noted on the cardiograph. The Brain Attack Team was activated immediately, and he was seen by the team at 1257H.

* Trademark: Pradaxa[®] (Boehringer Ingelheim, Ridgefield, Connecticut).



Neurologic examination showed right facial paralysis, right-sided weakness with moderate sensory loss, and moderate dysarthria (National Institutes of Health Stroke Scale [NIHSS] = 5 points). Intravenous hydration was started, and blood samples were collected. Noncontrast brain magnetic resonance imaging (MRI) with magnetic resonance angiography performed at 1317 H revealed hyperacute infarct on the left corona radiata with cutoff on the left M1 segment of the middle cerebral artery. The use of MRI was crucial in this case to ascertain the extent of ischemia given that the patient took multiple antihypertensive agents after developing symptoms. Absence of exclusion criteria was ascertained on further history. There was no history of severe head trauma or prior ischemic stroke within the past 3 months, no history of previous intracranial hemorrhage, no gastrointestinal malignancy or recent gastrointestinal bleed within 21 days, no previous treatment of low-molecular-weight heparin within the previous 24 h, and no symptoms consistent with infective endocarditis or intra-axial intracranial neoplasm. Coagulation assays were normal with a prothrombin time of 12.9 s, an international normalized ratio of 1.1, and a partial thromboplastin time of 38.4 s.

With the last administered dose of dabigatran already at 7 h since the onset of symptoms, we opted for thrombolysis given the patient's radiologic and clinical findings. At 1355 H, two succeeding doses of idarucizumab 2.5 g were given via intravenous bolus to reverse the effect of dabigatran. None of the most commonly encountered adverse reactions to idarucizumab such as headache, hypokalemia, delirium, and constipation¹³ was noted. Idarucizumab infusion was immediately followed by intravenous thrombolysis of 58 mg of rtPA, equating to 0.9 mg rtPA/kg body weight administered ~271 min' postictus. Thirty minutes' postinfusion, the

patient's speech and right leg weakness improved. In 6 days, the patient improved from NIHSS 5 to 2, with noted complete resolution of weakness and sensory deficit. Due to persistently elevated blood pressure recordings, a nicardipine drip was started and titrated accordingly to maintain systolic blood pressure <180 mm Hg and diastolic blood pressure <105 mm Hg, which is recommended for acute ischemic stroke patients who were given intravenous thrombolysis during the first 24 h. A brain computed tomography scan was performed 19 h after the intravenous rtPA (earlier than the required 24 h following needle time) that excluded hemorrhagic transformation. Apixaban 2.5 mg BID was then started for secondary stroke prevention on day 2. The patient underwent physical therapy and was discharged in 2 weeks with mild facial paralysis and mild dysarthria (NIHSS = 2). His home medications were apixaban 2.5 mg BID, amlodipine 10 mg once daily, and nebivolol 5 mg once daily.

Upon follow-up 1 month from ictus, the patient had only subtle right facial asymmetry (NIHSS = 1). Noncontrast brain MRI with magnetic resonance angiography in 52 days showed T2 and flair hyperintensities on the left corona radiata with complete recanalization of the left proximal M1 segment of the middle cerebral artery. The Fig. shows the complete timeline of events.

DISCUSSION

Idarucizumab is approved as an effective and safe reversal agent of dabigatran to date. In our institution, this case is the first in which idarucizumab was used as a reversal agent in a patient taking dabigatran before administration of intravenous alteplase. The standard dose of this drug is 5 g given intravenously within <15 min¹¹ or as 2 consecutive doses of a 2.5 g infusion.¹³ In the stroke

Figure. Timeline of events. Initial imaging of magnetic resonance imaging with magnetic resonance angiography (MRI/MRA), plain. Diffusion-weighted imaging (A-1) showed hyperintense signal in the left corona radiata with corresponding signal drop on apparent diffusion coefficient (A-2). MRA time of flight (A-3) demonstrated signal cutoff on proximal left M1. Follow-up computed tomography (CT) scan 19 h' postthrombolysis (B-1) showed no hemorrhage. Repeat imaging study done on day 52 by C-MRI/MRA showed T2 (C-1) and flair sequence (C-2) hyperintense signals on the area of the left corona radiata without hemosiderin deposits on gradient echo sequence (C-3). MRA time of flight (C-4) revealed complete recanalization of the previously occluded left M1. ED = emergency department; NIHSS = National Institutes of Health Stroke Scale; rtPA = recombinant tissue plasminogen activator.

thrombolysis consensus guide for anticoagulated patients from Japan, specifically for dabigatran, IV thrombolysis is not recommended if the last dose was within 4 h regardless of the level of activated partial thromboplastin time (aPTT). This method is recommended given that the plasma concentration of dabigatran reaches the maximum level in 2–4 h after dosing, and aPTT is often within normal ranges immediately after dosing.¹⁰ However, coagulation studies are not entirely accurate in measuring the efficacy of dabigatran levels. There are reports that a normal coagulation study is not directly proportional to dabigatran levels. A normal coagulation study in a patient was reported to have a dabigatran serum concentration of 90 ng/mL, which is much higher than the therapeutic blood level of dabigatran >50 ng/mL.¹¹ Hence, the risk of bleeding cannot be adequately measured by a normal aPTT alone. This therefore indicates the importance of dabigatran reversal before administration of IV thrombolysis. Our patient's coagulation profile was normal, and the last dabigatran intake was 7 h before thrombolysis.

Patients with renal impairment may have an increased risk of developing bleeding complications due to impaired clearance of dabigatran. Conversely, idarucizumab seems to be safe in renal disease, and dose adjustment is not necessary. Idarucizumab is a human monoclonal antibody approved by the US Food and Drug Administration in 2015 as a rapid reversal agent of dabigatran, which may pave the way for earlier thrombolysis for patients with ischemic stroke. Its adverse effects were not connected with respect to age, dose, and degree of renal impairment, as discussed elsewhere.¹³ This case adds to other published data on combined dabigatran reversal and thrombolysis with special consideration given to the elderly population with chronic renal disease.⁷ The decision to perform thrombolysis in this patient was due to immediate method for recanalization in the setting of a stroke with NIHSS of 5. We wanted to prioritize what was readily available and proceed with thrombectomy in the event that the patient's condition deteriorated further despite thrombolysis.

This case establishes that idarucizumab infusion may be given before thrombolysis among patients taking dabigatran. Notably, in the number of published case reports with successful outcome, NIHSS improvement reportedly occurred between

patients with 1 and 17 points among a wide age range of patients aged 58–90 years. We were concerned with bleeding in our patient as a serious complication when his blood pressure started rising, especially given his age and chronic renal disease. A brain computed tomography scan taken after 19 h excluded an intracranial hemorrhage. Cautious blood pressure control and constant reassurance played a vital role in management. Predictably, antidepressant use supported the patient's recovery over time in the hospital and during rehabilitation. In the series of 80 cases in Germany, no bleeding complication was reported.¹² To date, our reported case is the second successful instance of intravenous TPA given preceding idarucizumab in an elderly patient beyond 270 min, which is the upper limit of threshold for thrombolysis, and, to our knowledge, the patient is the first to receive such a combination in the setting of chronic renal disease.

The delay in door time has led to a domino effect to needle time. We chose to start the patient on apixaban, similar to published reports that showed a lesser degree of renal excretion (27%) compared with dabigatran (80%), making it the more favorable choice for patients with chronic renal disease.¹⁴ We believed this was the safest new oral anticoagulant considering the patient's age and his related comorbidities (save for the lower incidence of hemorrhagic complication). Repeat magnetic resonance angiography after 52 days showed recanalization of the previously blocked proximal M1 on the left.

The combined effect clinically and radiographically in this case proved the importance of thrombolysis in a difficult setting in which rapid decisions must be made. Because of this latest innovation in medical care in stroke, strong recommendations to formalize a protocol serving as a guideline must be in place.

CONCLUSIONS

This case showed the safe and successful dabigatran reversal with idarucizumab preceding intravenous thrombolysis administered at the threshold time window for thrombolysis in an elderly individual with atrial fibrillation and chronic kidney disease. Based on this report, we recommend formalizing a protocol with guidelines on idarucizumab infusion to be applied to clinical scenarios, including those that may be nonstandard, given the heterogeneity of

patients eligible for thrombolysis and the timeline during which patients are assessed.

DISCLOSURES

The authors have indicated that they have no conflicts of interest regarding the content of this article.

ACKNOWLEDGMENTS

None.

REFERENCES

- de Souza Lima Bitar Y, Neto MG, Filho JAL, et al. Comparison of the new oral anticoagulants and warfarin in patients with atrial fibrillation and valvular heart disease: systematic review and meta-analysis. *Drugs R D*. 2019;19: 117–126.
- Chan Y, See L, Tu H, et al. Efficacy and safety of apixaban, dabigatran, rivaroxaban, and warfarin in Asians with nonvalvular atrial fibrillation. *J Am Heart Assoc*. 2018;7.
- Shaw JR, Siegal DM. Pharmacological reversal of the direct oral anticoagulants—a comprehensive review of the literature. *Res Pract Thromb Haemost*. 2018;2:251–265.
- Schiele F, van Ryn J, Canada K, et al. A specific antidote for dabigatran: functional and structural characterization. *Blood*. 2013;121:3554–3562.
- Schmohl M, Glund S, Harada A, et al. Idarucizumab does not have procoagulant effects: assessment of thrombosis biomarkers in healthy volunteers. *Thromb Haemost*. 2017;117:269–276.
- Toyoda K, Yamagami H, Koga M. Consensus guides on stroke thrombolysis for anticoagulated patients from Japan: application to other populations. *J Stroke*. 2018;20: 321–331.
- Turine G, Peeters A, Hermans C, Eeckhoudt S, Duprez T. Intravenous thrombolysis after reversal of dabigatran by idarucizumab: a moment to be a pioneer. *Acta Neurol Belg*. 2017;117:753–755.
- Khatri R, McKinney AM, Swenson B, Janardhan V. Blood-brain barrier, reperfusion injury, and hemorrhagic transformation in acute ischemic stroke. *Neurology*. 2012;79:S52–S57.
- Mateen FJ, Buchan AM, Hill MD. Outcomes of thrombolysis for acute ischemic stroke in octogenarians versus nonagenarians. *Stroke*. 2010;41:1833–1835.
- Xian Y, Federspiel JJ, Hernandez AF, et al. Use of intravenous recombinant tissue plasminogen activator in patients with acute ischemic stroke who take non-vitamin K antagonist oral anticoagulants before stroke. *Circulation*. 2017;135:1024–1035.
- Pikija S, Sztrihai LK, Sebastian Mutzenbach J, Golaszewski SM, Sellner J. Idarucizumab in dabigatran-treated patients with acute ischemic stroke receiving alteplase: a systematic review of the available evidence. *CNS drugs*. 2017;31:747–757.
- Kermer P, Eschenfelder CC, Diener H-C, et al. Antagonizing dabigatran by idarucizumab in cases of ischemic stroke or intracranial hemorrhage in Germany—updated series of 120 cases. *Int J Stroke*. 2020, 174749301989565.
- Hutcherson TC, Cieri-Hutcherson NE, Bhatt R. Evidence for idarucizumab (Praxbind) in the reversal of the direct thrombin inhibitor dabigatran: review following the REVERSE AD full cohort analysis. *P T*. 2017;42:692–698.
- Zhou L-Y, Yang S-F, Zhang Z, et al. A renal function based trade-off analysis of non-vitamin K antagonist oral anticoagulants in nonvalvular atrial fibrillation. *Front Physiol*. 2018;9.

Address correspondence to: Christian Oliver C. Co, MD, Institute of Neurosciences, St. Luke's Medical Center—Global City, 5th Ave, Taguig, 1634, Manila, Philippines. E-mail: cochristianoliver@gmail.com