

Hyperthyroidism as a Precipitant Factor for Cerebral Venous Thrombosis: A Case Report

Journal of Investigative Medicine High Impact Case Reports
Volume 8: 1–4
© 2020 American Federation for Medical Research
DOI: 10.1177/2324709620949309
journals.sagepub.com/home/hic
 SAGE

Ahmed Elkhailifa Elawad Elhassan, MBBS¹ , Mohammed Omer Khalil Ali, MBBS² , Amina Bougaila, MD², Mohammed Abdelhady, MBBCH, EDiR², and Hassan Abuzaid, MBBS, MD, FRCP(Edin), MSc²

Abstract

Cerebral venous sinus thrombosis (CVT) is an uncommon yet serious condition. While CVT has many known precipitants and etiologies, hyperthyroidism as a precipitant of CVT is not well understood. This study reported a case of a 41-year-old male with a 4-year history of hyperthyroidism presented with seizure. Consequently, a diagnosis of superior sagittal sinus thrombosis was confirmed by computed tomography and magnetic resonance (MR) venograms. Extensive investigations yielded no apparent underlying cause, but laboratory findings were consistent with uncontrolled hyperthyroidism. The patient improved rapidly following anticoagulation. Follow-up MR and MRV scans 2 months after treatment revealed full recanalization of the superior sagittal sinus. This case report highlighted hyperthyroidism, as a procoagulant condition, resulting specifically in superior sagittal sinus thrombosis.

Keywords

cerebral venous sinus thrombosis, CVT, superior sagittal sinus thrombosis, hyperthyroidism, hypercoagulable state

Introduction

Cerebral venous thrombosis (CVT) is an uncommon condition with an incidence ranging between 0.22 and 1.57 per 100 000 annually.¹ The major risk factors of CVT in adults are prothrombotic conditions, oral contraceptives, pregnancy and puerperium, malignancy, infections, and head injury along with genetic thrombophilia including antithrombin deficiency, protein C or protein S deficiency, factor V Leiden mutation, and hyperhomocysteinemia.^{2,3}

Coagulation disturbances are reported in patients with hyperthyroidism.⁴ However, the link between hyperthyroidism and CVT is not clearly understood despite an emerging number of case reports linking both conditions. We report a case of a young male, without clear acquired or genetic thrombotic risk factors, who was diagnosed with superior sagittal sinus thrombosis (SSST) and concomitantly had uncontrolled hyperthyroidism. This case report highlighted hyperthyroidism as a precipitant factor of CVT (SSST specifically).

Case Presentation

A 41-year-old gentleman with a 4-year history of hyperthyroidism presented to the emergency department with an episode of generalized tonic clonic seizure, self-terminated within 5 minutes. The patient denied history of previous seizures. There was no fever, headache, or weakness. No history of recent infection or trauma. Regarding his hyperthyroidism,

he was started on carbimazole on diagnosis. However, during the last 3 years, the patient discontinued his medication, and he was lost to follow-up. He had no past medical history of coagulation or bleeding abnormalities. He does not smoke or consume alcohol.

On physical examination, he was afebrile, tachycardic (100–110 beats per minute), alert, and oriented. No focal neurological deficit was detected. Neck examination revealed a mild goiter, but no audible bruit. Electrocardiography showed sinus tachycardia. Laboratory studies revealed normal white blood cell count and C-reactive protein, and normal basic electrolytes. Lactic acid was 1.6 mmol/L (0.5–2.2 mmol/L). Thyroid function test showed thyroid-stimulating hormone <0.01 mIU/L (0.30–4.20 mIU/L), FT4 73 mIU/L (11.6–21.9 mIU/L), and FT3 29 mIU/L (3.7–6.4 mIU/L). Antithyroid peroxidase level was 293 IU/mL (0–35 IU/mL). Neck ultrasound showed mildly enlarged thyroid gland with diffuse heterogeneous echotexture suggestive of chronic thyroiditis. Head noncontrast computed tomography (CT) scan

¹University of Khartoum, Khartoum, Sudan

²Hamad Medical Corporation, Doha, Qatar

Received June 24, 2020. Revised July 17, 2020. Accepted July 18, 2020.

Corresponding Author:

Ahmed Elkhailifa Elawad Elhassan, University of Khartoum, Al Qasr Street, Khartoum 11111, Sudan.

Email: ahmed-khalifa@live.com



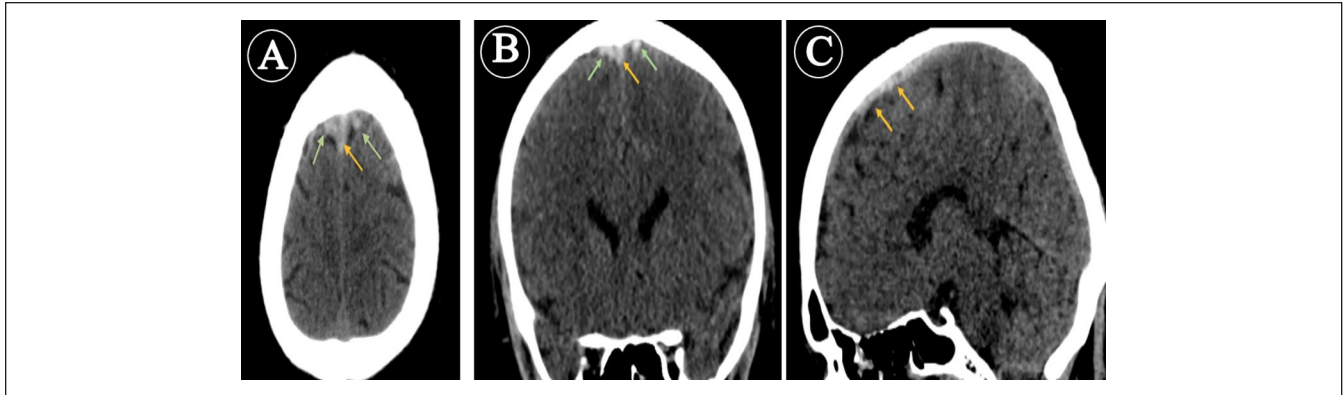


Figure 1. Noncontrast computed tomography (CT) scan axial (A), coronal (B) and sagittal (C) planes displaying increased attenuation along the anterosuperior aspect of the superior sagittal sinus (orange arrows) and adjacent cortical veins bilaterally (green arrows) suggesting focal superior sagittal sinus and adjacent cortical veins thrombosis.

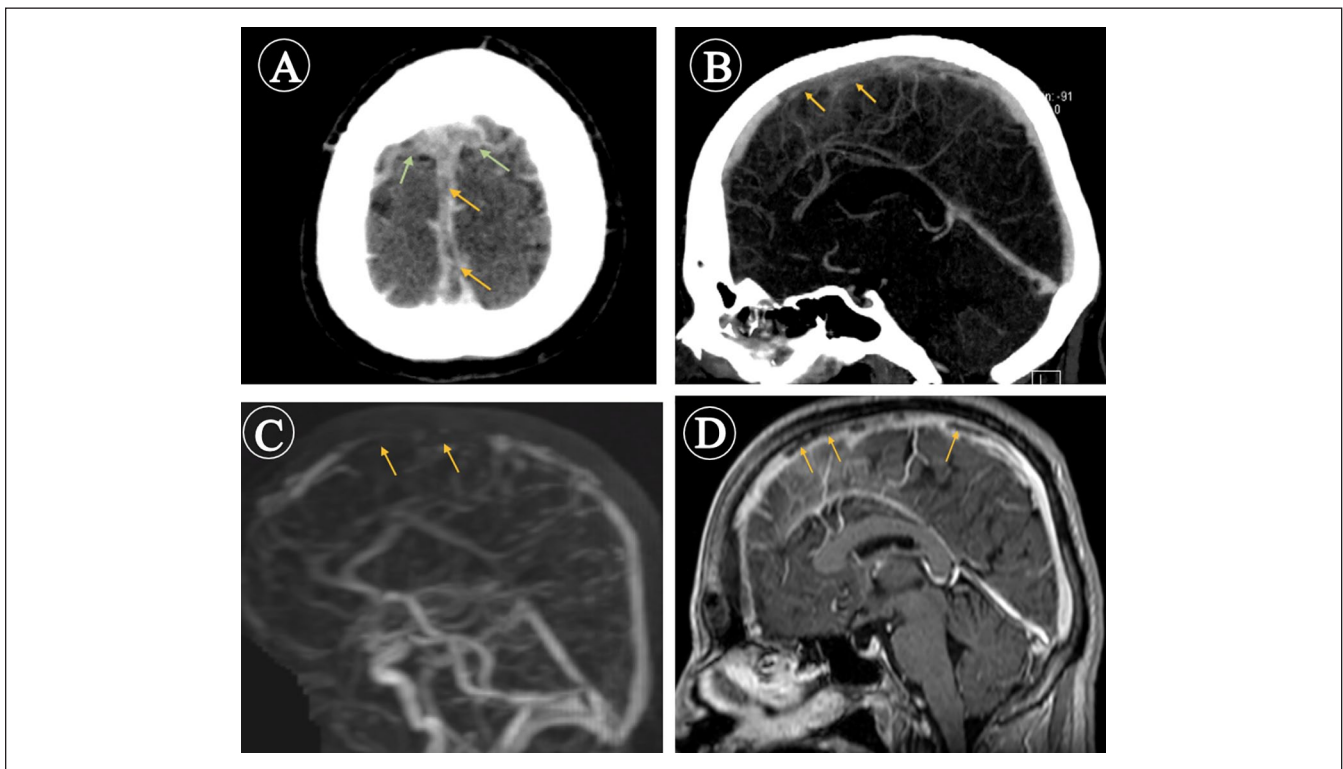


Figure 2. Computed tomography (CT) and magnetic resonance (MR) venogram scans. CT venogram axial (A) and sagittal (B) planes showing nonopacification of the anterosuperior aspect of the superior sagittal sinus (orange arrows) and adjacent cortical veins (green arrows) confirming their thrombosis. MR venogram (C) and MR sagittal (D) T1W-Fat sat postcontrast demonstrate filling defects within the anterosuperior aspect of the superior sagittal sinus (orange arrows).

displayed increased attenuation along the anterosuperior aspect of the superior sagittal sinus and adjacent cortical veins bilaterally (Figure 1) suggesting focal superior sagittal sinus and adjacent cortical veins thrombosis. This was confirmed by CT and magnetic resonance (MR) venograms (Figure 2). Coagulation profile showed normal PT/PTT/INR (prothrombin time/partial thromboplastin time/international

normalized ratio) and elevated D-dimer. IgM (immunoglobulin M) and IgG anticardiolipin antibodies and lupus anticoagulant were negative. Prothrombin c.*97G>A variant and 161G>A mutation for Factor V Leiden were not detected. Antithrombin activity was normal (80%). Protein C and protein S were normal. Homocysteine level was 12 $\mu\text{mol/L}$ (0-12 $\mu\text{mol/L}$). He had low vitamin B₁₂ level, 124 pmol/L

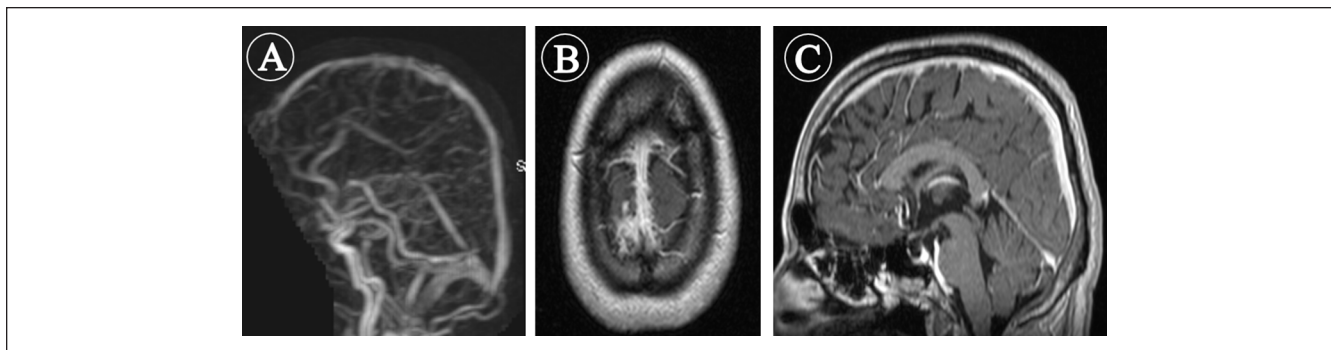


Figure 3. Follow-up magnetic resonance (MR) venogram (A) MR axial (B) and sagittal (C) T1W-Fat sat postcontrast images demonstrate recanalization of the superior sagittal sinus and the adjacent cortical veins with no sizeable filling defects.

(145-596 pmol/L). He was started on therapeutic dose of enoxaparin and carbimazole, 15 mg BID (twice daily). He was discharged on dabigatran 150 mg BID and vitamin B₁₂ replacement.

Two months later, follow-up MR and MRV demonstrated evidence of recanalization of the previously noted thrombosed portion of the superior sagittal sinus and adjacent cortical veins (Figure 3). Moreover, a follow-up thyroid function test turned out to be normal.

Discussion

CVT is an uncommon multifactorial condition with up to 25% of cases being considered as idiopathic.⁵ Thyrotoxicosis as a cause of CVT was first described by Kaliebe⁶ in 1913. Since then, an emerging number of reports have linked CVT with hyperthyroidism.⁷⁻¹² To the best of our knowledge, this is the first report in the Middle East demonstrating the association between CVT and hyperthyroidism. On a thorough literature review, we have noticed, as in our case, that the superior sagittal sinus was the most common site of hyperthyroidism-related CVT. A systemic review done by Bensalah et al⁸ in 2011 showed that SSST was involved in 18 out of 26 cases (69%) of hyperthyroidism-related CVT. Imai et al¹⁰ and Yokoyama et al¹¹ also reported hyperthyroidism-related SSST in 2018 and 2019, respectively.

As in any thrombosis, CVT development is related to Virchow's triad of hypercoagulability, vessel wall injury, and venous stasis.¹³ Hypercoagulable and hypofibrinolytic states are reported in hyperthyroidism; in a meta-analysis of 51 studies assessing the effect of high thyroid hormone levels (exogenous or endogenous) on coagulation system, high thyroid hormone levels were associated with a rise in factors VIII, IX, Von Willebrand factor, and fibrinogen.⁴ Additionally, hyperthyroidism has been reported to cause an increase in factor X.¹⁴ On the other hand, hypofibrinolysis in hyperthyroidism is suggested to be caused by a reduction of plasmin and plasmin activator, as well as an elevation of plasminogen activator inhibitor-1, 2-antiplasmin, and thrombin activatable fibrinolysis inhibitor.^{4,14} There is evidence suggesting

that the procoagulant effect seen in hyperthyroidism is mediated through the thyroid hormone receptor beta gene (THRB), as, in contrast to patients with hyperthyroidism, patients with resistance to thyroid hormone, who have defective THRB, did not show an increased risk of hypercoagulability despite having high levels of thyroid hormone.¹⁵ As Graves' disease is the most common cause of hyperthyroidism,¹⁶ this could raise an assumption that attributes hypercoagulability and hypofibrinolysis to inflammatory or autoimmune mechanisms. However, administering exogenous doses of levothyroxine in healthy volunteers was also found to cause hypercoagulable and hypofibrinolytic states.¹⁷

In our case, we investigated the possibility of known risk factors causing CVT, all of which were negative. Notably, the homocysteine level in our patient was in the upper normal range (12 μ mol/L). There is evidence that suggests high homocysteine levels as a risk factor for thrombosis¹⁸; Gowda et al¹⁹ and Kanaya et al²⁰ have reported CVT in patients with high homocysteine levels (>50 μ mol and 90 nmol, respectively) in the absence of other risk factors. However, this is unlikely in our patient as the homocysteine level was still within the normal range. Regarding the possibility of venous stasis, it has been reported that large goiters may contribute to cerebral venous stasis.²¹ However, the neck ultrasound of our case showed a mild goiter. Moreover, there was no evidence of vessel wall injury as a cause of thrombosis.

Conclusion

We suggest that hyperthyroidism may precipitate CVT by causing hypercoagulability. Therefore, we recommend considering CVT in any patient with hyperthyroidism presenting with neurological symptoms. Likewise, important is considering thyroid function testing in CVT patients with no clear causes.

Declaration of Conflicting Interests

The author(s) declared no potential conflicts of interest with respect to the research, authorship, and/or publication of this article.

Funding

The author(s) received no financial support for the research, authorship, and/or publication of this article.

Ethics Approval

Our institution does not require ethical approval for reporting individual cases or case series.

Informed Consent

Verbal informed consent was obtained from the patient for his anonymized information to be published in this article.

ORCID iDs

Ahmed Elkhailifa Elawad Elhassan  <https://orcid.org/0000-0002-3651-4885>

Mohammed Omer Khalil Ali  <https://orcid.org/0000-0002-5815-9466>

References

- Coutinho JM, Zuurbier SM, Aramideh M, Stam J. The incidence of cerebral venous thrombosis: a cross-sectional study. *Stroke*. 2012;43:3375-3377.
- Ferro JM, Correia M, Pontes C, Baptista MV, Pita F; Cerebral Venous Thrombosis Portuguese Collaborative Study Group (Venoport). Cerebral vein and dural sinus thrombosis in Portugal: 1980-1998. *Cerebrovasc Dis*. 2001;11:177-182.
- Coutinho JM, Ferro JM, Canhão P, et al. Cerebral venous and sinus thrombosis in women. *Stroke*. 2009;40:2356-2361.
- Stuijver DJF, van Zaane B, Romualdi E, Brandjes DPM, Gerdes VEA, Squizzato A. The effect of hyperthyroidism on procoagulant, anticoagulant and fibrinolytic factors: a systematic review and meta-analysis. *Thromb Haemost*. 2012;108:1077-1088.
- Stam J. Cerebral venous and sinus thrombosis: incidence and causes. *Adv Neurol*. 2003;92:225-232.
- Kaliebe H. Autochthone sinusthrombose bei einem fälle von morbus basedow und tabes. *Med Klin*. 1913;9:1929-1932.
- Squizzato A, Gerdes VEA, Brandjes DPM, Buller HR, Stam J. Thyroid diseases and cerebrovascular disease. *Stroke*. 2005;36:2302-2310.
- Bensalah M, Squizzato A, Kablia SO, Menia H, Kemali Z. Cerebral vein and sinus thrombosis and hyperthyroidism: a case report and a systematic review of the literature. *Thromb Res*. 2011;128:98-100.
- Madan S, Chaudhuri Z. Cerebral venous thrombosis with auto-immune hyperthyroidism. *Indian J Ophthalmol*. 2018;66:1649-1651. doi:10.4103/ijo.IJO_23_18
- Imai T, Ohsima J, Hasegawa Y. Diagnosis of Graves' disease by cerebral venous thrombosis: a case report. *Clin Neurol*. 2018;58:696-699.
- Yokoyama M, Yamashita R, Furuya M, Yamazaki M, Koyama K, Tanaka F. A case of cerebral venous thrombosis and deep venous thrombosis due to hyperthyroidism with increased factor VIII activity. *J Stroke Cerebrovasc Dis*. 2019;28:104364. doi:10.1016/j.jstrokecerebrovasdis.2019.104364
- Son HM. Massive cerebral venous sinus thrombosis secondary to Graves' disease. *Yeungnam Univ J Med*. 2019;36:273-280. doi:10.12701/yujm.2019.00339
- Saposnik G, Barinagarrementeria F, Brown RD Jr, et al; American Heart Association Stroke Council and the Council on Epidemiology and Prevention. Diagnosis and management of cerebral venous thrombosis: a statement for healthcare professionals from the American Heart Association/American Stroke Association. *Stroke*. 2011;42:1158-1192.
- Ordookhani A, Burman KD. Hemostasis in overt and subclinical hyperthyroidism. *Int J Endocrinol Metab*. 2017;15:e44157.
- Elbers LPB, Moran C, Ea Gerdes V, et al. The hypercoagulable state in hyperthyroidism is mediated via the thyroid hormone receptor pathway. *Eur J Endocrinol*. 2016;174:755-762.
- Brent GA. Graves' disease. *N Engl J Med*. 2008;358:2594-2605.
- Van Zaane B, Squizzato A, Debeij J, et al. Alterations in coagulation and fibrinolysis after levothyroxine exposure in healthy volunteers: a controlled randomized crossover study. *J Thromb Haemost*. 2011;9:1816-1824.
- Wald DS, Law M, Morris JK. Homocysteine and cardiovascular disease: evidence on causality from a meta-analysis. *BMJ*. 2002;325:1202-1206.
- Gowda VK, Nanjundappa RC, Pendharkar H, Benakappa N. Homocystinuria with cerebral venous sinus thrombosis: Excellent recovery with intravenous recombinant tissue plasminogen activator. *Iran J Child Neurol*. 2017;11:48-52.
- Kanaya Y, Neshige S, Takemaru M, Shiga Y, Takeshima S, Kuriyama M. Cerebral venous sinus thrombosis associated with hyperhomocysteinemia due to combined deficiencies of folate and vitamin B₁₂ [in Japanese]. *Clin Neurol*. 2016;56:116-119.
- Hodgson KJ, Lazarus JH, Wheeler MH, et al. Duplex scan-derived thyroid blood flow in euthyroid and hyperthyroid patients. *World J Surg*. 1988;12:470-475.