



Contents lists available at ScienceDirect

## American Journal of Emergency Medicine

journal homepage: [www.elsevier.com/locate/ajem](http://www.elsevier.com/locate/ajem)

## Acute necrotizing encephalopathy: A case report

Evan L. Jackson<sup>a,\*</sup>, Wesley Eilbert<sup>a</sup>, Amber M. Hathcock<sup>b</sup><sup>a</sup> Department of Emergency Medicine, University of Illinois, College of Medicine, 1819 West Polk St. Room 469, Chicago, IL 60612, United States of America<sup>b</sup> Department of Pediatric Emergency Medicine, University of Illinois, College of Medicine, 1819 West Polk St. Room 469, Chicago, IL 60612, United States of America

## ARTICLE INFO

## Article history:

Received 29 June 2020

Received in revised form 29 July 2020

Accepted 9 August 2020

Available online xxxx

## Keywords:

Necrotizing encephalopathy

Acute necrotizing encephalopathy

Viral encephalopathy

Post-infectious encephalopathy

## ABSTRACT

Acute necrotizing encephalopathy (ANE) is a recently identified, uncommon encephalopathy affecting children. ANE is characterized by a preceding viral illness followed by seizures and rapid progressive neurologic deterioration. The diagnosis of ANE is made based on clinical presentation and characteristic multifocal brain lesions seen on computed tomography (CT). We report a previously healthy two-year-old boy who presented to our emergency department (ED) after a seizure in the setting of fever and diarrhea. He was ultimately diagnosed with ANE and treated with steroids and IVIG. Early identification of this high morbidity condition by its typical clinical picture and characteristic radiologic findings is key to allow for optimal treatment.

© 2020 Elsevier Inc. All rights reserved.

## 1. Introduction

Acute necrotizing encephalopathy (ANE) is a recently identified, uncommon encephalopathy affecting children. ANE is characterized by a preceding virus-associated illness followed by seizures and rapid, progressive neurologic deterioration. The diagnostic cornerstone of ANE is the identification of symmetric, multifocal brain lesions involving bilateral thalami and possibly the cerebral white matter, brainstem, or cerebellum as seen on computed tomography (CT) [1,2].

## 2. Case report

A previously healthy two-year-old boy presented to the emergency department (ED) after a 20-min “shaking episode” witnessed by his mother at home. After a brief period of decreased responsiveness, the child returned to his baseline after the event. His mother reported he had experienced fever and diarrheal stools during the preceding day.

On initial physical examination, he was febrile with a temperature of 41.4 °C. He was alert and interacted with his mother and the emergency physician in an age-appropriate manner. He appeared well-hydrated and had no apparent neurologic deficits. The remainder of his physical examination revealed no obvious source of the fever. Shortly after arrival to the ED, he was noted to have decreasing alertness followed by a brief tonic clonic seizure that resolved after the administration of 0.1 mg/kg of intravenous (IV) lorazepam. His mental status did not return to the baseline after the seizure and continued to deteriorate over the next several hours.

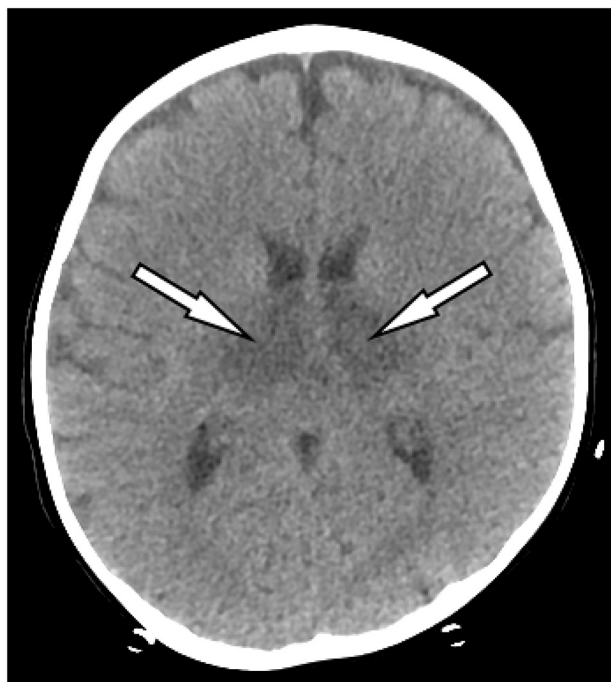
Laboratory testing performed in the ED found a serum white blood cell count of 6200/mm<sup>3</sup>. Significant elevations in the hepatic transaminases were noted, with an aspartate transaminase level of 16,963 IU/L (<38 IU/L) and alanine transaminase level of 8356 IU/dL (<64 IU/L). The serum ammonia level was 55 mg/dL, which is in the range of normal for children. The international normalized ratio (INR) was elevated at 2.7, which precluded the performance of a lumbar puncture in the ED. A head CT without contrast demonstrated symmetric hypodensities in the thalami and posterior paramedian pons suggestive of ANE (Figs. 1 and 2).

The patient was treated for presumed meningitis, and he was admitted to the intensive care unit (ICU). On arrival to the ICU he was noted to be nonverbal with no eye opening, though had localizing withdrawal of his extremities to pain. He was intubated two days after admission because of deteriorating mental status and transiently required peritoneal dialysis because of renal failure. A lumbar puncture performed three days after admission found no white blood cells and a mildly elevated cerebrospinal fluid protein level of 45 mg/dL. Blood and cerebrospinal fluid cultures ultimately yielded no growth, and viral polymerase chain reaction testing was positive for parainfluenza type 1 and rhinovirus/enterovirus. The patient was treated with IV immunoglobulin and methylprednisolone. His neurologic condition began to slowly improve after one week. He was discharged after one month of hospitalization to a rehabilitation facility. At the time of discharge he remained nonverbal, though was interactive with his mother.

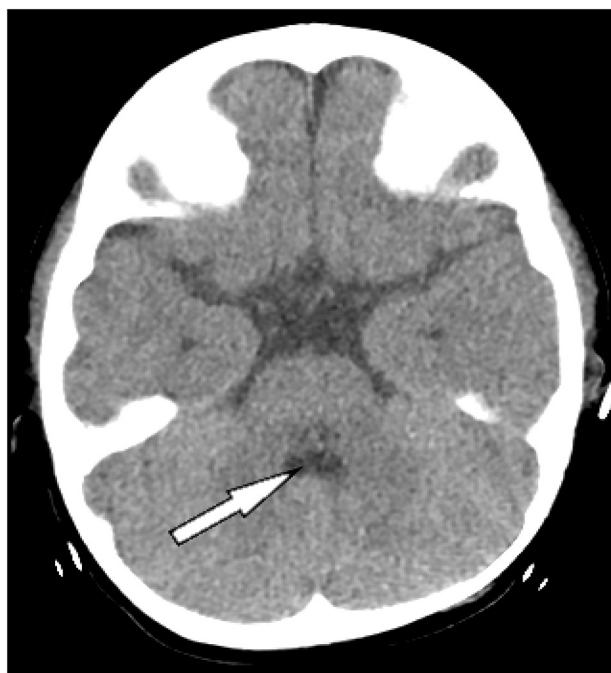
## 3. Discussion

First described in 1995, ANE is a rare disorder characterized by fever, seizures, and rapid progression to coma within days after the onset of a

\* Corresponding author.  
E-mail address: [evanleighjackson@gmail.com](mailto:evanleighjackson@gmail.com) (E.L. Jackson).



**Fig. 1.** Computed tomography image showing symmetric hypodensities in the thalami (arrows) suggestive of acute necrotizing encephalopathy.



**Fig. 2.** Computed tomography image showing hypodensities in the posterior paramedian region of the pons (arrow) suggestive of acute necrotizing encephalopathy.

viral infection [1]. It predominately afflicts children under five years of age. The global incidence of ANE is unknown, although fewer than 300 cases have been reported in the medical literature. The vast majority

**Table 1**

Diagnostic criteria of acute necrotizing encephalopathy.

1. Acute encephalopathy following viral disease, with seizure and deterioration of consciousness.
2. Absence of cerebrospinal fluid pleocytosis. Cerebrospinal fluid protein is commonly increased.
3. Neuroimaging findings of symmetric, multifocal brain lesions involving the bilateral thalami, upper brain stem tegmentum, periventricular white matter, internal capsule, putamen, and cerebellum.
4. Elevation of hepatic transaminase levels to a variable degree. No increase in serum ammonia level.
5. Exclusion of resembling diseases.
  - A. Diseases that clinically resemble acute necrotizing encephalopathy: toxic shock syndrome, hemolytic uremic syndrome, Reye's syndrome, hemorrhagic shock and encephalopathy syndrome, and heatstroke.
  - B. Diseases that radiologically or pathologically resemble acute necrotizing encephalopathy: Leigh encephalopathy, glutaric acidemia, methyl malonic aciduria, infantile bilateral strial necrosis, Wernicke encephalopathy, carbon monoxide poisoning, acute disseminated encephalomyelitis, acute hemorrhagic leukoencephalitis, arterial or venous infarct, and hypoxic injury.

of cases initially reported were in East Asian countries; however, more recent reports indicate a worldwide distribution [3].

Diagnostic criteria for ANE have been proposed (Table 1) [2,4,5]. Over 90% of children with ANE will have a preceding febrile illness, often with symptoms of upper respiratory infection [2]. Several viral illnesses have been associated with ANE, with influenza being the most commonly reported [6]. Neurologic dysfunction, most commonly seizure, typically occurs within three days of the illness onset, followed by rapid decline in mental status with coma ensuing within 24 h [2]. In most cases, the diagnosis of ANE can be made on the basis of the combination of a typical clinical profile and characteristic radiologic findings.

Imaging findings are the hallmark of ANE, with symmetric, multifocal brain lesions seen on CT. Bilateral thalamic involvement is present in virtually all cases. The majority of patients with ANE will have some elevation of hepatic transaminases and elevated cerebrospinal fluid protein, and a minority will have laboratory studies consistent with disseminated intravascular coagulation (DIC) and acute renal failure [2].

The exact pathogenesis of ANE is unknown. The most prevalent hypothesis is that ANE is the result of an exaggerated immune response to a viral infection, with resultant elevated pro-inflammatory cytokines [4]. This "cytokine storm" leads to liver dysfunction, acute renal failure, and DIC. In the central nervous system, it results in alteration of vessel wall permeability and brain injury.

While several parainfectious encephalopathies can result in a clinical picture similar to ANE, the two that most closely resemble it are acute disseminated encephalomyelitis and Reye's syndrome (Table 2) [2,7,8]. No specific treatments for ANE exist, although some case reports and small case series have suggested that administration of corticosteroids, IV immunoglobulin, and induced hypothermia may improve clinical outcomes [9–11]. The overall prognosis of ANE is poor, with over 90% of survivors left with permanent neurologic sequelae (5). Mortality rates for ANE approach 30% (1,2).

#### 4. Why should an emergency physician be aware of this?

ANE is a recently identified parainfectious encephalopathy afflicting young children. This high-morbidity condition presents with characteristic history and physical examination findings and quickly progresses

**Table 2**

Characteristics of acute necrotizing encephalopathy, acute disseminated encephalomyelitis, and Reye's syndrome

Characteristic	Acute necrotizing encephalopathy	Acute disseminated encephalomyelitis	Reye's syndrome
Age preponderance	Under 5 years	Over 5 years	Over 5 years
Seizures	Frequent	Occasional	Occasional
Hepatic dysfunction	Frequent	None	Frequent
Coagulation disorder	Occasional	None	Frequent
Lactic acidemia	Occasional	None	Frequent
Hyperammonemia	Rare	None	Frequent
Hypoglycemia	Rare	None	Frequent
Increased cerebrospinal fluid protein	Frequent	Frequent	Rare
Cerebrospinal fluid pleocytosis	Rare	Frequent	None
Radiologic findings	Symmetric brain lesions of the bilateral thalami and possibly the cerebral white matter, brain stem, or cerebellum	Asymmetric areas of inflammation and demyelination of the cerebral white matter, basal ganglia, brain stem, and spinal cord	Diffuse cerebral edema

with rapid neurologic deterioration. Identification of ANE by its clinical characteristics and distinctive radiologic findings is key to allow for optimal treatment.

### Source of support

None.

This article has not previously been presented.

### References

- [1] Mizuguchi M, Abe J, Mikkaichi K, Noma S, Yoshida K, Yamanaka T, et al. Acute necrotizing encephalopathy of childhood: a new syndrome presenting with multifocal, symmetric brain lesions. *J Neurol Neurosurg Psychiatry*. 1995;58(5):555–61.
- [2] Mizuguchi M. Acute necrotizing encephalopathy of childhood: a novel form of acute encephalopathy prevalent in Japan and Taiwan. *Brain Dev*. 1997;19(2):81–92.
- [3] Lee YJ, Hwang SK, Kwon S. Acute necrotizing encephalopathy in children: A long way to go. *J Korean Med Sci*. 2019;34(19):e143.
- [4] Wu X, Wu W, Pan W, Wu L, Liu K, Zhang HL. Acute necrotizing encephalopathy: An unrecognized clinicoradiologic disorder. *Mediators Inflamm*. 2015;2015:79257.
- [5] Kim JH, Kim IO, Lim MK, Park MS, Choi CG, Kim HW, et al. Acute necrotizing encephalopathy in Korean infants and children: Imaging findings and diverse clinical outcome. *Korean J Radiol*. 2004;5(3):171–7.
- [6] Hoshino A, Saitoh M, Oka A, Okumura A, Kubota M, Saito Y, et al. Epidemiology of acute encephalopathy in Japan, with emphasis on the association of viruses and syndromes. *Brain Dev*. 2012;34(5):337–43.
- [7] Cole J, Evans E, Mwangi M, Mar S. Acute disseminated encephalomyelitis in children: An updated review based on current diagnostic criteria. *Pediatr Neurol*. 2019;100:26–34.
- [8] Maheady DC. Reye's syndrome: Review and update. *J Pediatr Health Care*. 1989;3(5):246–50.
- [9] Manara R, Franzoi M, Cogo P, Battistella PA. Acute necrotizing encephalopathy: Combined therapy and favorable outcome in a new case. *Childs Nerv Syst*. 2006;22(10):1231–6.
- [10] Vargas WS, Merchant S, Solomon G. Favorable outcomes in acute necrotizing encephalopathy in a child treated with hypothermia. *Pediatr Neurol*. 2012;46(6):387–9.
- [11] Okumura A, Mizuguchi M, Kidokoro H, Tanaka M, Abe S, Hosoya M, et al. Outcome of acute necrotizing encephalopathy in relation to treatment with corticosteroids and immunoglobulin. *Brain Dev*. 2009;31(3):221–7.