


Endovascular Treatment for Vertebrobasilar Artery Tandem Occlusion Beyond 24 Hours From Onset of Stroke—Case Report

Vascular and Endovascular Surgery
1-4
© The Author(s) 2020
Article reuse guidelines:
sagepub.com/journals-permissions
DOI: 10.1177/1538574420953953
journals.sagepub.com/home/ves


Takashi Mizowaki, MD, PhD¹ , Atsushi Fujita, MD, PhD² ,
Satoshi Inoue, MD, PhD¹, and Eiji Kurihara, MD, PhD¹

Abstract

We report a case in which endovascular treatment (EVT) was performed for vertebral and basilar artery (VA and BA) tandem occlusion beyond 24 hours from onset of stroke. A 78-year-old man was admitted to our institution with dysarthria and disturbance of gait. MRI revealed occlusion of the BA with acute ischemic change in bilateral cerebellum and brain stem. At 36 hours after onset and 30 hours after administration, EVT was performed because of deteriorating neurological symptom. Successful revascularization was achieved with percutaneous transluminal angioplasty for VA and thrombectomy for BA occlusion. The neurological symptoms were improved in postoperative course.

Keywords

acute ischemic stroke, vertebrobasilar artery, tandem occlusion, endovascular treatment

Introduction

If left untreated, the prognosis of both symptomatic severe vertebrobasilar stenosis as well as acute basilar artery (BA) occlusion is poor with mortality rates up to 21% for symptomatic posterior circulation stenoses and up to 85% for acute BA occlusion.¹⁻⁴ Up to 64% of patients with acute vertebrobasilar stroke have an underlying unilateral or bilateral vertebral artery (VA) stenosis or occlusion, also called tandem occlusion,⁵ and 26%–36% have an underlying intracranial stenosis.⁴ Therefore, emergency revascularization of acute vertebrobasilar artery tandem occlusion with a retrieval stent with or without concomitant stenting of the underlying stenotic or occlusive lesion is an emerging treatment option for this complex form of stroke. Only a few published studies have addressed the technical aspects and patient outcomes in this subpopulation of patients with acute vertebrobasilar artery tandem occlusion.⁶⁻¹¹ Vertebrobasilar artery tandem occlusion may be associated with longer procedural time and poor clinical outcome compared with purely embolic BA occlusion because of necessity of angioplasty for tandem VA lesion. In these patients, endovascular treatment (EVT) is more challenging and the best approaches for access are extracranial and intracranial permanent stenting. Furthermore, optimal treatment strategies to enhance recanalization rates, avoid peri-procedural complications, and improve the clinical outcome are yet to be determined. To the best of our knowledge, this is the first patient in which EVT was successfully performed for

vertebrobasilar artery tandem occlusion beyond 24 h from the onset of stroke.

Material and Methods

Patient History

A 78-year-old man with a past history of hypertension and diabetes mellitus without atrial fibrillation was admitted to our institute 6 h after the onset of mild dysarthria and gait disturbance. His National Institutes of Health Stroke Scale (NIHSS) score was 2. Magnetic resonance imaging (MRI) and magnetic resonance angiography (MRA) showed an occlusion of the BA (Figure 1A) with acute ischemic changes in the bilateral cerebellum and brain stem (Figure 1B). Systemic recombinant tissue-type plasminogen activator was not used because of beyond the therapeutic time window. Because the pathology was considered to be atherothrombotic stroke, medical treatment with antiplatelet drugs (75 mg clopidogrel and 200 mg cilostazol daily) was started. Systemic heparinization was

¹Department of Neurosurgery, Junshin Hospital, Kakogawa, Hyogo, Japan

²Department of Neurosurgery, Kobe University Graduate School of Medicine, Hyogo, Japan

Corresponding Author:

Takashi Mizowaki, Department of Neurosurgery, Junshin Hospital, 865-1 Befu-cho, Kakogawa, Hyogo 675-0122, Japan.

Email: mizowakit@yahoo.co.jp

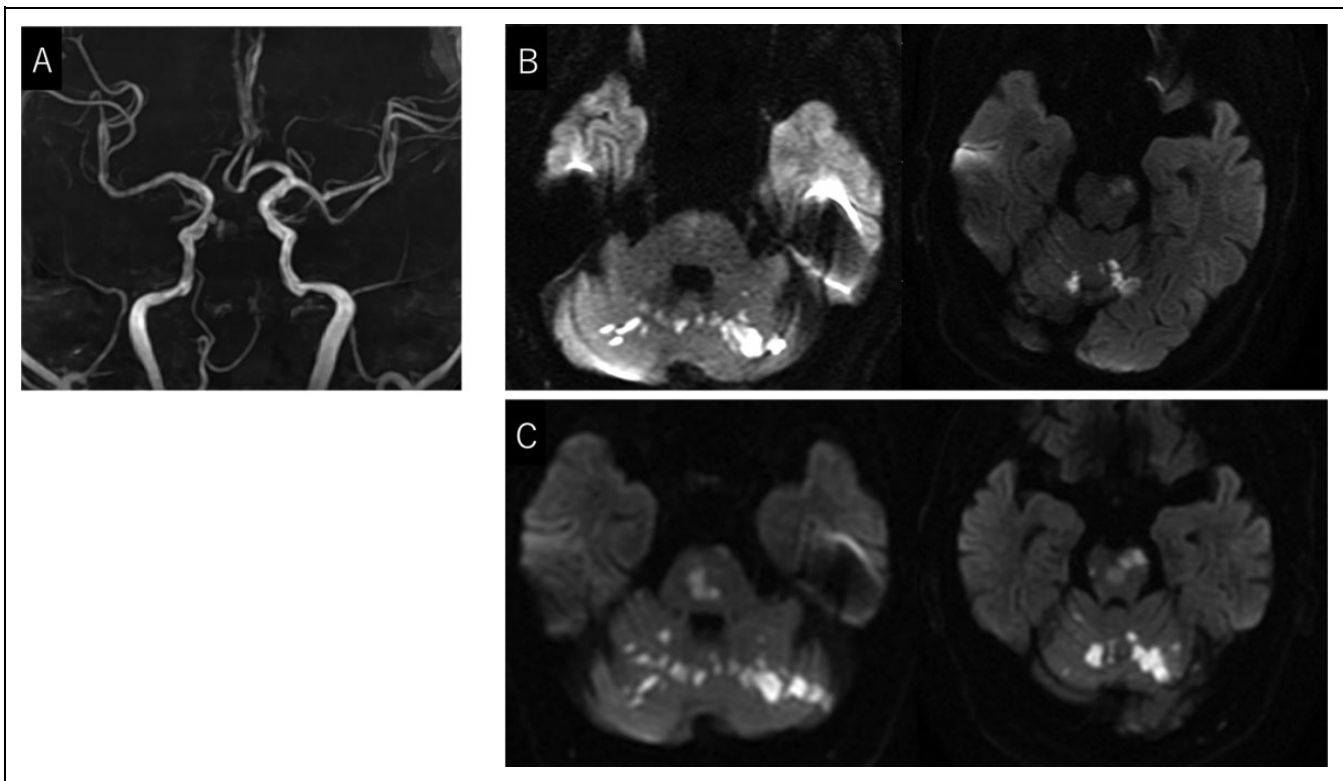


Figure 1. A, Magnetic resonance angiography shows occlusion of basilar artery. B, Magnetic resonance diffusion-weighted imaging on admission shows acute ischemic change in bilateral cerebellum and brain stem. C, Magnetic resonance diffusion-weighted imaging shows worsening cerebellum and brain stem infarction.

started 6 h after admission due to deterioration of dysarthria and the onset of mild right hemiparesis with NIHSS score 4. Temporary improvement of neurological symptoms was observed; however, his consciousness deteriorated, right hemiparesis recurred, and NIHSS score increased to 12 after 30 h since administration. MRI showed worsening of the cerebellum and brain stem infarction (Figure 1C); therefore, we decided to perform EVT.

Endovascular Procedure

EVT was performed under local anesthesia via femoral access after systemic heparinization with a bolus dose of 4000 IU. First, angiography confirmed right VA terminating in a posterior inferior cerebellum artery (PICA) (Figure 2A). A 6-French ultra-long sheath was placed in the cervical portion of the left VA. Angiography of the left VA confirmed persistent occlusion of the V3 portion (Figure 2B). Loading doses of aspirin (100 mg) and clopidogrel (225 mg) were administered using a gastric tube before percutaneous angioplasty (PTA). After 3 cycles of PTA (Figure 2C) by a 2.0-mm balloon, revascularization of the left VA was obtained, and BA occlusion was revealed (Figure 2D). The occlusion was crossed with a microcatheter and a micro-guidewire (Figure 2E). After injection of the microcatheter showed the distal artery to be normal,

a 4.0-mm retrieval stent was fully deployed across the occluded lesion. The deployed retrieval stent was slowly pulled back. Postprocedural angiography confirmed successful revascularization with the intra-stent retrieval clot (Figure 2F and G). The total time taken from femoral access to arterial revascularization was 200 min.

Results

The patient's neurologic symptoms improved slightly on the day after the procedure (NIHSS score 6). MRA performed 1 day after the procedure confirmed successful revascularization (Figure 3A), and diffusion-weighted imaging showed only small ischemic changes (Figure 3B). Antiplatelet drugs (75 mg clopidogrel and 200 mg cilostazol daily) were started 24 h after the procedure and continued. Three months later, the patient recovered with modified Rankin Scale 2. No ischemic events or recurrence of occlusion occurred during the 1 year follow-up period.

Discussion

We reported a case of EVT for vertebrobasilar artery tandem occlusion stroke 24 h from the onset of stroke. The course of disease and intraoperative findings revealed that the stroke mechanism was atherothrombotic brain infarction.

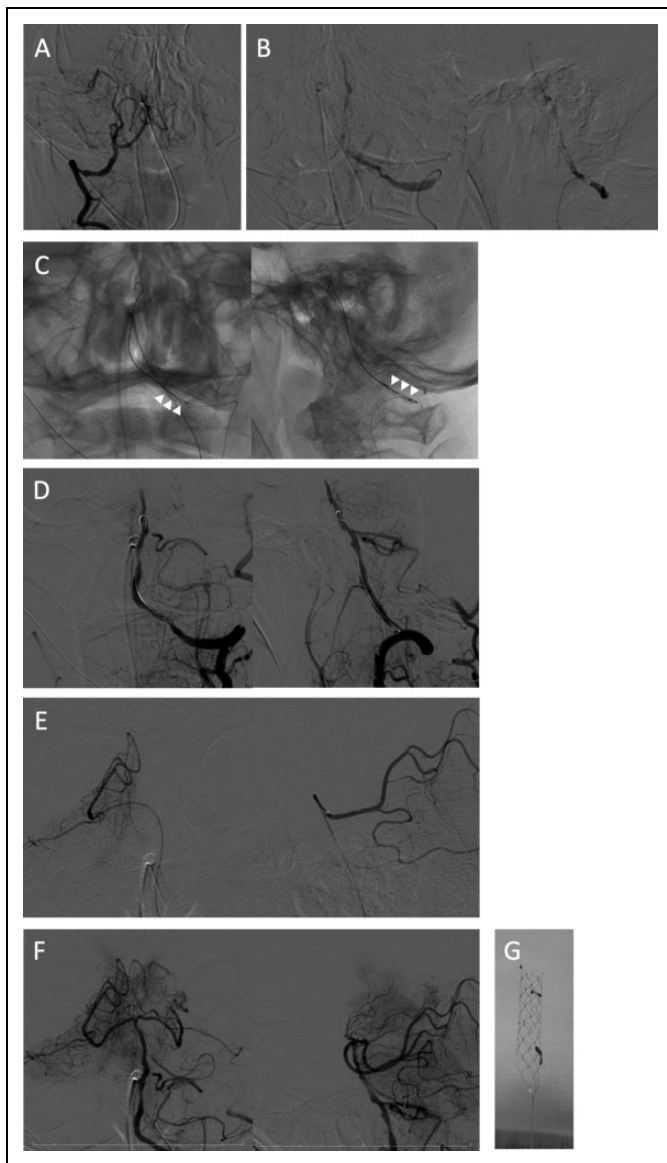


Figure 2. A, Angiographic imaging of right vertebral artery (anterior view) shows terminating in a posterior inferior cerebellum artery. B, Angiographic imaging of left vertebral artery (anterior and lateral view) shows occlusion of vertebral artery (V3 portion). C, Percutaneous transluminal angioplasty was performed by a 2.0-mm balloon (arrow heads) at left V3 portion of vertebral artery. D, Angiographic imaging of left vertebral artery (anterior and lateral view) shows revascularization of the left vertebral artery and basilar artery occlusion. E, Injection of a micro-catheter after passage of the occlusion shows the distal portion (right posterior cerebral artery, anterior and lateral view) of this artery to be normal. F, Final angiographic images of the left vertebral artery (anteroposterior and lateral views) show successful revascularization. G, Photograph shows slightly attached clot of the retrieval stent.

Medical treatment was initially performed because of mild neurological symptoms. However, the neurological symptoms deteriorated despite antiplatelet and anticoagulant therapies, and we performed EVT beyond 24 h from the onset of stroke.

Time Window to Recanalization

Antiplatelet therapy was initially performed because the patient's neurological symptoms were mild. The neurological symptoms temporarily deteriorated but improved after the antithrombotic treatment. There are several reports⁶⁻¹¹ of EVT for vertebrobasilar artery tandem occlusion; however, all of them are within 24 h of the onset. Zeumer et al¹² reported that aggressive revascularization should be performed after acute vertebrobasilar artery occlusion if there is no widespread infarction on computed tomography, regardless of the elapsed time. Regarding EVT, Yoon et al¹³ reported that patients with arteriosclerotic stroke have better functional prognosis than patients with other types of ischemic stroke due to the development of collateral circulation. Acute BA occlusion often takes the form of disturbed consciousness, while acute VA occlusion often takes the form of a progressive stroke.¹⁴ In our patient, the course of symptoms and intraoperative findings suggest the presence of preceding arteriosclerotic VA lesions, which may have resulted in tandem occlusion.

Endovascular Treatment

The role of EVT in tandem occlusion stroke is not yet clear; particularly, the data of mechanical thrombectomy in combination with PTA or stenting are still limited to small case studies.⁶⁻¹¹ Furthermore, procedural aspects concerning revascularization strategies, sequence, and techniques in this challenging group of serious conditions have only sparsely been evaluated or discussed in the literature. Two treatment approaches for tandem occlusion of anterior circulation have been reported¹⁵: antegrade and retrograde. In the setting of posterior circulation, Ecker et al⁸ reported on 6 patients treated with the antegrade approach, wherein half of the patients achieved functional independence and one-third of the patients died due to progressive infarction. Yang et al¹⁰ reported on 7 patients treated with the retrograde approach, wherein 3 of 7 patients achieved functional independence and 3 of 7 patients died due to progressive infarction. Generally, in vertebrobasilar artery tandem occlusion, the contralateral VA (clean-road path) was the priority access point to perform mechanical thrombectomy of the BA occlusion.⁷ Piechowiak et al¹¹ reported on a total of 15 patients with tandem occlusion, in which 11 were treated with a dirty load/retrograde approach and 4 were treated via the contralateral VA (clean-road) approach. The dirty load approach was selected because of the contralateral VA terminating in a PICA, and thrombectomy for BA was performed after PTA for VA in our case. Retrieval stent was used to thrombectomy for BA because the aspiration catheter may not cross the VA stenosis. Subsequently, no additional stenting for VA was needed. Postoperatively, dual antiplatelet therapy was continued to prevent the progression of VA arteriosclerotic stenosis.

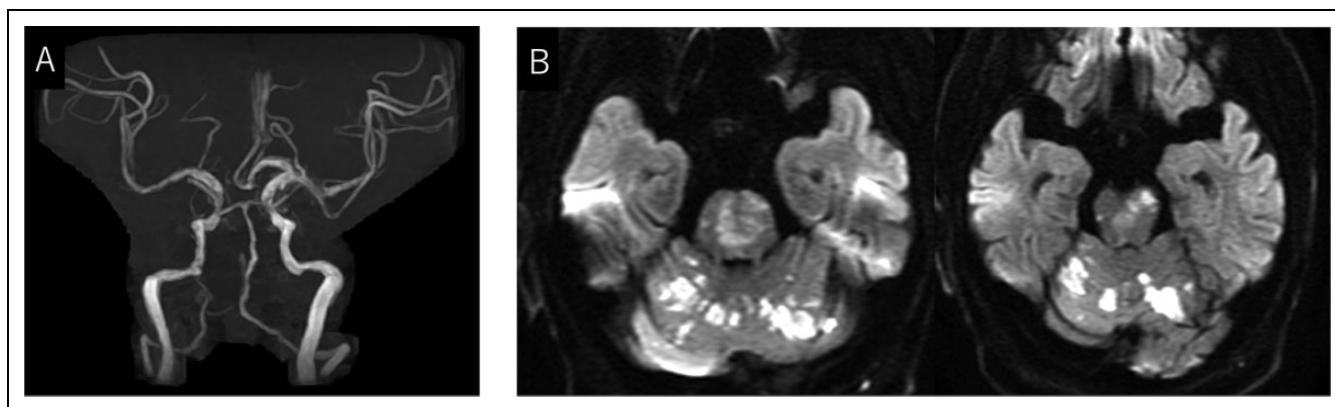


Figure 3. A, Magnetic resonance angiography performed 1 day after the procedure confirms successful revascularization. B, Magnetic resonance diffusion-weighted imaging performed 1 day after procedure shows mild ischemic change.

Conclusions

This case suggests that delayed EVT of acute vertebrobasilar artery tandem occlusion can be successfully performed without technical complications; however, further studies are needed to confirm this.

Authors' Note

Informed consent has been obtained from the patient for this study and publication of this case report with accompanying images.


Declaration of Conflicting Interests


The author(s) declared no potential conflicts of interest with respect to the research, authorship, and/or publication of this article.

Funding

The author(s) received no financial support for the research, authorship, and/or publication of this article.

ORCID iDs

Takashi Mizowaki  <https://orcid.org/0000-0003-2947-7040>

Atsushi Fujita  <https://orcid.org/0000-0003-1294-6584>

References

1. Qureshi AI, Ziai WC, Yahia AM, et al. Stroke-free survival and its determinants in patients with symptomatic vertebrobasilar stenosis: a multicenter study. *Neurosurgery*. 2003;52(5):1033-1039.
2. Prognosis of patients with symptomatic vertebral or basilar artery stenosis. The Warfarin-Aspirin Symptomatic Intracranial Disease (WASID) Study Group. *Stroke*. 1998;29(7):1389-1392.
3. Labauge R, Pages M, Marty-Double C, Blard JM, Boukobza M, Salvaing P. Occlusion of the basilar artery: a review with 17 personal cases (author's transl). *Rev Neurol (Paris)*. 1981;137(10):545-571.
4. Mattle HP, Arnold M, Lindsberg PJ, Schonewille WJ, Schroth G. Basilar artery occlusion. *Lancet Neurol*. 2011;10(11):1002-1014.
5. Compter A, van der Hoeven EJ, van der Worp HB, et al. Vertebral artery stenosis in the Basilar Artery International Cooperation Study (BASICS): prevalence and outcome. *J Neurol*. 2015;262(2):410-417.
6. Abe A, Okubo S, Onozawa S, et al. Acute vertebral artery origin occlusion leading to basilar artery thrombosis successfully treated by angioplasty with stenting and thrombectomy. *Interv Neuroradiol*. 2014;20(3):325-328.
7. Cohen JE, Leker RR, Gomori JM, et al. Emergent revascularization of acute tandem vertebrobasilar occlusions: endovascular approaches and technical considerations—confirming the role of vertebral artery ostium stenosis as a cause of vertebrobasilar stroke. *J Clin Neurosci*. 2016;34:70-76.
8. Ecker RD, Tsujiura CA, Baker CB, Cushing D. Endovascular reconstruction of vertebral artery occlusion prior to basilar thrombectomy in a series of six patients presenting with acute symptomatic basilar thrombosis. *J Neurointerv Surg*. 2014;6(5):379-383.
9. Siebert E, Bohner G, Zweynert S, et al. Revascularization techniques for acute basilar artery occlusion: technical considerations and outcome in the setting of severe posterior circulation stenocclusive disease. *Clin Neuroradiol*. 2019;29(3):435-443.
10. Yang H, Ma N, Zhang S, et al. Endovascular revascularisation of acute tandem vertebrobasilar artery occlusion: seven case series with literature reviews. *Stroke Vasc Neurol*. 2018;3(1):17-21.
11. Piechowiak EI, Kaesmacher J, Zibold F, et al. Endovascular treatment of tandem occlusions in vertebrobasilar stroke: technical aspects and outcome compared with isolated basilar artery occlusion. *J Neurointerv Surg*. 2020;12(1):25-29.
12. Zeumer H, Freitag HJ, Zanella F, Thie A, Arning C. Local intraarterial thrombolytic therapy in patients with stroke: Urokinase versus recombinant tissue plasminogen activator (r-TPA). *Neuroradiology*. 1993;35(2):159-162.
13. Yoon W, Kim SK, Park MS, Kim BC, Kang HK. Endovascular treatment and the outcomes of atherosclerotic intracranial stenosis in patients with hyperacute stroke. *Neurosurgery*. 2015;76(6):680-686.
14. Smith WS. Intra-arterial thrombolytic therapy for acute basilar occlusion: pro. *Stroke*. 2007;38(2 suppl):701-703.
15. Lockau H, Liebig T, Henning T, et al. Mechanical thrombectomy in tandem occlusion: procedural considerations and clinical results. *Neuroradiol*. 2015;57(6):589-598.