

## Case report

# A biventricular takotsubo cardiomyopathy complication: large thrombus formation to stroke in 150 min

Eric W Moffet ,<sup>1,2</sup> Gurjaspreet Kaur Bhattal,<sup>1</sup> Alexis N Simpkins,<sup>3</sup> John W Petersen<sup>4</sup>

<sup>1</sup>Internal Medicine, University of Florida College of Medicine, Gainesville, Florida, USA

<sup>2</sup>Ken & Ruth Davee Department of Neurology, Northwestern University Feinberg School of Medicine, Chicago, Illinois, USA

<sup>3</sup>Neurology, University of Florida College of Medicine, Gainesville, Florida, USA

<sup>4</sup>Cardiology, University of Florida College of Medicine, Gainesville, Florida, USA

**Correspondence to**  
Dr Eric W Moffet;  
emoffet@ufl.edu

Accepted 6 August 2020

## SUMMARY

A 67-year-old postmenopausal African American woman presented with biventricular takotsubo cardiomyopathy (TTC)—evidenced by transthoracic echocardiography (TTE) showing apical akinesis of both left and right ventricles in the absence of obstructive coronary artery disease on left heart catheterisation. On the 4th hospital day, she experienced acute left facial droop, dysarthria and dysphagia. CT of the head showed a wedge infarct of the right middle cerebral artery territory. Cardioembolism was presumed after intracranial and extracranial sources of thromboembolism were ruled out. Intravenous tissue plasminogen activator (tPA) was administered with resolution of symptoms. She was later discharged without neurological deficits. Crucially, repeat TTE after tPA infusion revealed a left ventricular mass concerning for thrombus. TTE 150 min prior to stroke onset was devoid of a mass. This case uniquely illustrates the potential for rapid thrombus formation and embolism in patients with TTC. As such, it emphasises the high index of suspicion required for management of these patients.

## BACKGROUND

Thromboembolic complications of takotsubo cardiomyopathy (TTC) have been described.<sup>1–3</sup> The current case emphasises how quickly a quite large intraventricular thrombus can form and embolise. Previous authors have reported large and rapid thrombus formation, including in TTC, in the context of interventional cardiology, and beyond.<sup>4–8</sup> However, in this case, the swift creation (in less than 2.5 hours) of a large thrombus proves remarkable.

TTC is characterised by left ventricular apical ballooning without evidence of coronary artery disease, though biventricular TTC also exists.<sup>9–10</sup> Stasis of flow within the left ventricle (LV) may create a nidus for thrombus formation.<sup>11–12</sup> Arterial embolisms can occur in TTC complicated by LV thrombus,<sup>13–19</sup> yet the mechanisms of thrombus formation have not been adequately addressed.

Herein, we report a case of cardioembolic stroke as a complication of biventricular TTC. Fortuitously timed echocardiograms support that thrombus formation and stroke took place in no more than 150 min. The case offers novel insight into the natural history of this TTC complication—providing clues to the mechanistic underpinnings

of such events—and highlights the need for a high index of suspicion required in caring for this patient population.

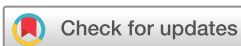## CASE PRESENTATION

A 67-year-old postmenopausal African American woman with a history of hypertension, hyperlipidemia, congenital atrial septal defect (repaired 10 years prior), and tobacco, alcohol and marijuana use presented with substernal chest ‘heaviness’. She was a poor historian, but preceding emotional stressors were not identified on interviewing her son. Vital signs were normal. Physical examination was remarkable for cachexia, poor dentition, dry mucous membranes and mild diffuse muscle wasting. Labs included a sodium of 127, potassium of 5.3 and bicarbonate of 18 with an anion gap of 21; aspartate aminotransferase was 76 and alanine transaminase was 23. High sensitivity troponin was 2540 pg/mL. An ECG showed T wave inversions in the lateral leads and right axis deviation. A transthoracic echocardiogram (TTE) was concerning for stress-induced cardiomyopathy on hospital day 1 and the diagnosis was confirmed via left heart catheterisation on the 3rd hospital day.

On day 4 of hospitalisation, a TTE at 07:30 showed ongoing TTC. The patient remained stable and was planned for discharge that day. Then, at approximately 10:00—150 min after the TTE—she experienced a 15 s episode of dysarthria and left-sided facial droop prompting a stroke code. Her CT of the brain with perfusion imaging showed a perfusion deficit in the right frontal lobe and no intracranial haemorrhage. Her symptoms resolved during the stroke alert after laying the head flat on her bed. At this time, she no longer had disabling deficits, so thrombolysis was not administered. However, at 12:05, she had reoccurrence of symptoms in addition to left arm weakness. Thus, a second stroke code was activated.

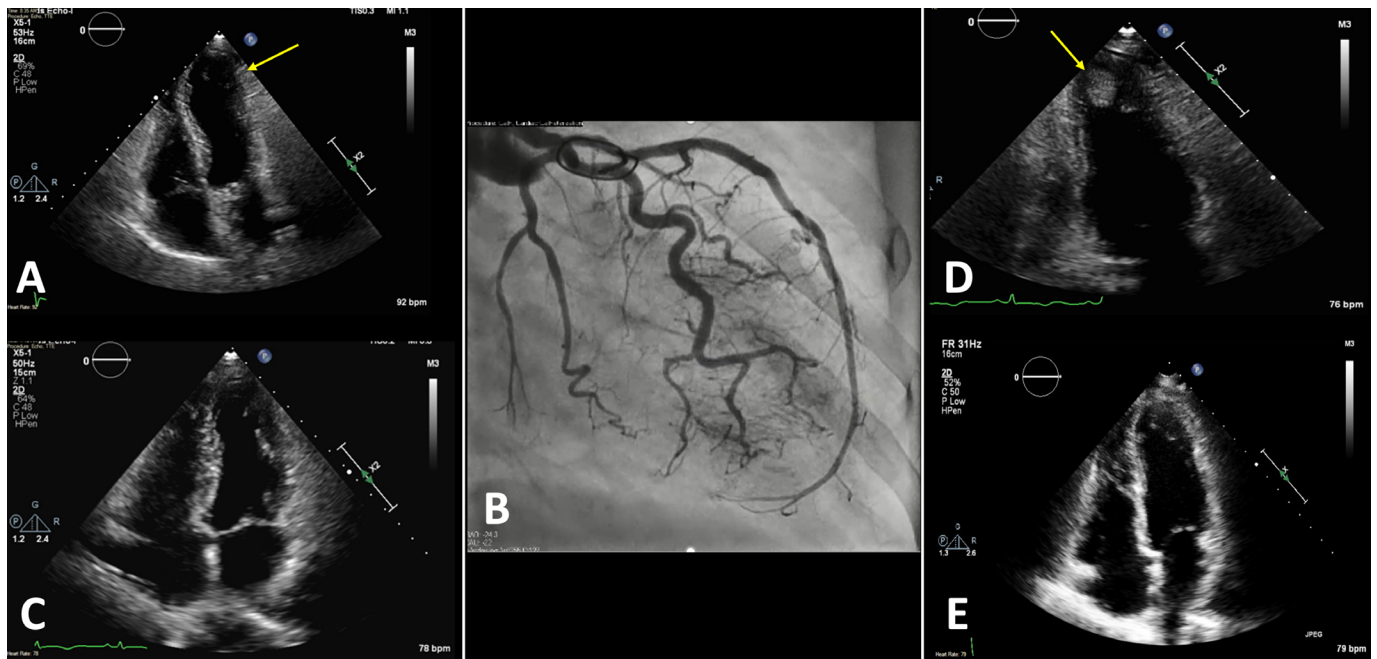
## INVESTIGATIONS

The patient’s first TTE ([figure 1A](#); [video 1](#)) displayed an LV ejection fraction of 30%–35%; all apical segments were akinetic, including the apical free wall of the right ventricle (RV). Basal segments appeared normal. Two days later cardiac catheterisation ([figure 1B](#); [video 2](#)) was completed and showed only ‘mild to moderate’ non-obstructive coronary artery disease. The next morning at 07:30, another



© BMJ Publishing Group Limited 2020. No commercial re-use. See rights and permissions. Published by BMJ.

**To cite:** Moffet EW, Bhattal GK, Simpkins AN, et al. *BMJ Case Rep* 2020;**13**:e235957. doi:10.1136/bcr-2020-235957



**Figure 1** Transthoracic echocardiography (TTE) apical four-chamber view. (A) On day 1 of admission displayed apical ballooning of the left ventricle and right ventricle apical free wall akinesis. coronary angiography. (B) On hospital day 3 was negative for significant coronary lesions, confirming stress-induced cardiomyopathy. TTE performed at 07:30 on hospital day 4 (C) was negative for thrombus. (D) TTE performed at 15:57 on hospital day 4, after patient had been stroke alerted and received tissue plasminogen activator, showed a 2.0×1.4 cm left ventricular thrombus. TTE performed on hospital day 6 (E) was negative for left ventricle thrombus.

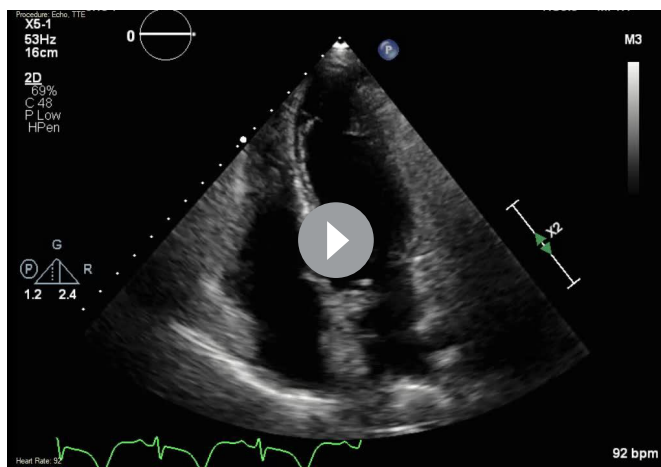
TTE (figure 1C; video 3) was completed—150 min prior to symptom onset—which demonstrated no changes. Another TTE (figure 1D; video 4) that afternoon (15:00) showed a new 2.0 × 1.4 cm pedunculated mobile mass in the LV apex. Two days later, a repeat TTE was negative for a mass (figure 1E; video 5).

CT angiography (CTA) with perfusion weighted imaging showed no intracranial (figure 2A) large vessel occlusion. There was no core volume on the cerebral blood volume map (figure 2B), but a perfusion deficit in the right frontal lobe was observed on the time-to-peak perfusion map. CT perfusion imaging (figure 2C) revealed a 3 mm wedge-shaped filling defect in the right frontal lobe. CTA of the head showed a distal M3/M4 occlusion of the right middle cerebral artery. CTA of the

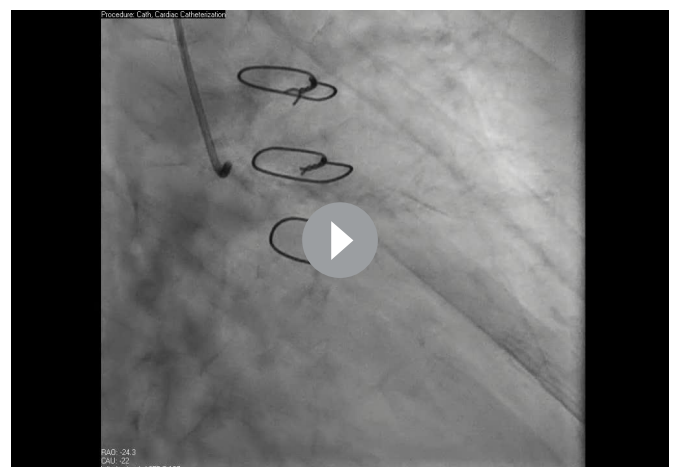
neck (figure 2D) was unremarkable and carotid duplex showed bilateral antegrade flow with <50% stenosis. CTA was negative for extracranial (figure 2E) large vessel occlusion. Magnetic resonance diffusion weighted sequence showed a small right frontal lobe infarct (figure 2F).

**DIFFERENTIAL DIAGNOSIS**

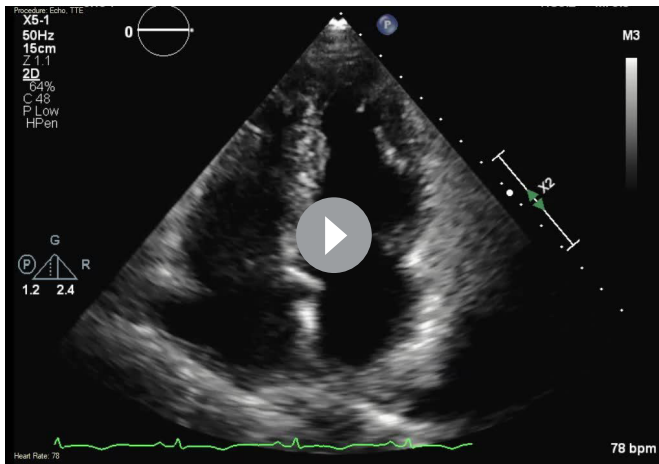
Given the wedge-shaped pattern of perfusion deficit and stroke risk factors, the differential diagnosis included cardioembolism, artery-to-artery embolisation from large artery atherosclerosis and hypercoagulability. Embolic ischaemic strokes are associated with atrial fibrillation, but also occur in the setting of left ventricular ballooning or due to



**Video 1.** A transthoracic echocardiography obtained on admission, which correlates with image A in figure 1, displayed apical ballooning of the left ventricle and right ventricle apical free wall akinesis.



**Video 2.** Coronary angiography on hospital day 3, this video correlates with image B in figure 1, was negative for significant coronary lesions—confirming stress-induced cardiomyopathy.

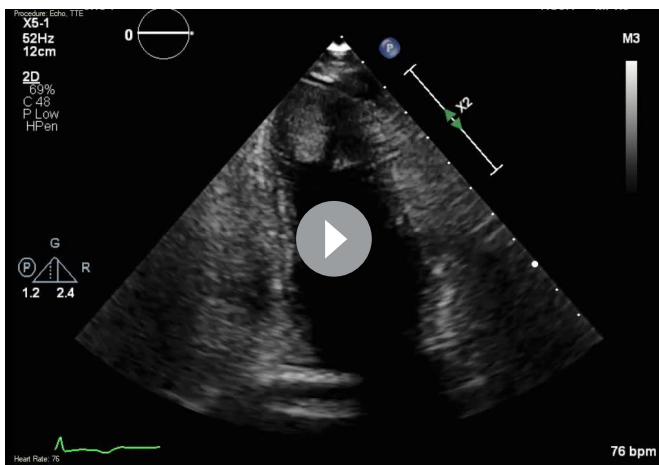


**Video 3.** Transthoracic echocardiography completed at 07:30 on hospital day 4, which correlates with image C in figure 1, showed ongoing stress-induced cardiomyopathy. Imaging was completed 150 min prior to stroke symptom onset.

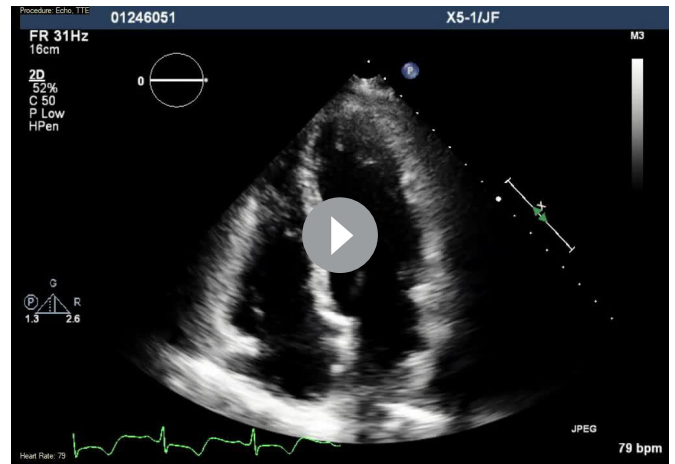
arterial-to-arterial thromboembolism from intracranial or extracranial arteries. Another aetiological concern included hypercoagulability, which was worked up (see below). Intracranial and carotid sources were ruled out via radiological imaging. The patient had not displayed atrial fibrillation during admission nor did she have a medical history of such. In this case, a cardioembolism was suspected due to the absence of intracranial and extracranial atherosclerotic disease and the presence of TTC with known left ventricular ballooning.

**TREATMENT**

Intravenous tPA was administered at 12:27, after a second stroke code was called, for suspected acute ischaemic stroke presenting with disabling deficits including facial weakness, dysarthria and left arm weakness. The patient was transferred to the neurointensive care unit (NICU) for further management thereafter.



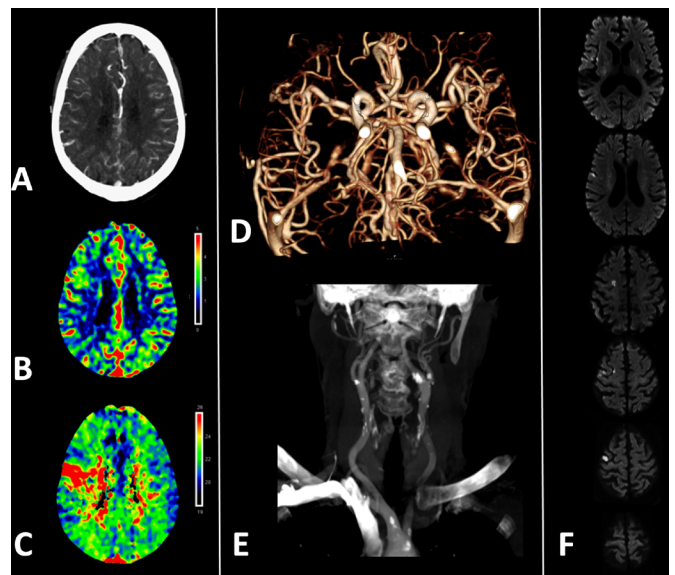
**Video 4.** Repeat transthoracic echocardiography done at 15:57 on day 4 of hospitalisation, after patient had been stroke alerted and received tissue plasminogen activator, showed a 2.0x1.4 cm left ventricular thrombus. This video correlates with image D in figure 1.



**Video 5.** Final transthoracic echocardiography, which was negative for thrombus, performed on hospital day 6; video correlates with image E in figure 1.

**OUTCOME AND FOLLOW-UP**

The day after thrombolysis, hospital day 5, the patient’s neurological examination was normal. CT of the head was negative for haemorrhagic transformation and evidence of ischaemia. Diffusion weighted magnetic resonance showed a small infarct in the right frontal lobe. A low-intensity heparin drip was started 24 hours post-tPA. That evening she was transferred to the neurology floor unit. On hospital day 6 at 02:30 she experienced a thromboembolism to her left iliac artery. Vascular surgery completed an emergent emblectomy. She was transferred back to the NICU by 9:30. At 14:00 a TTE was repeated, which showed no left ventricular mass. CT of the chest showed a 1.1 cm spiculated lung nodule



**Figure 2** CT angiography (CTA) with perfusion weighted imaging (A) showed that there was no intracranial large vessel occlusion. Cerebral blood volume map (B) showed no core volume. CT perfusion imaging (C) revealed a 3 mm wedge-shaped filling defect in the posterior right frontal lobe. CTA of the head and neck (D, E) revealed no large vessel occlusion extracranially. The magnetic resonance diffusion weighted sequence (F) demonstrated the small infarct in the right frontal lobe found on follow-up imaging.

## Unexpected outcome (positive or negative) including adverse drug reactions

in the right upper lobe. She was transferred to the neurology floor unit on hospital day 7; heparin was advanced to full intensity and a hypercoagulability work-up was ordered. On hospital day 9, she was transitioned from heparin to enoxaparin with plans for warfarin bridge. On hospital day 10 the patient was discharged without neurological deficits. The patient was lost to follow-up thereafter, including no-shows for appointments with cardiology, haematology, neurology, pulmonology and vascular surgery. The hypercoagulability work-up was negative for antiphospholipid antibody; anti-thrombin III and factor VIII activities were normal, as were homocysteine levels; activated protein C activity was low, at 60% (normal = >69%).

### DISCUSSION

TTC is a mimicker of acute coronary syndrome (ACS) with a reported incidence of 1%–3%.<sup>19 20</sup> It usually presents with chest pain and shortness of breath with unremarkable coronary angiography and a reversible reduction in ventricular systolic function. TTC is especially prevalent in postmenopausal women, with a mean presentation age of approximately 67 years.<sup>15</sup> Moreover, African-American patients suffer more in-hospital complications.<sup>19</sup> There are many echocardiographic variants of TTC, though LV apical akinesis pattern is most common.<sup>15 19</sup> Additionally, apical akinesis of the RV is seen in 25%–42% of TTC cases.<sup>10</sup> Simultaneous RV and LV akinesis has been reported to result in worse haemodynamic outcomes, and is associated with greater LV systolic dysfunction.<sup>10</sup> Despite being characterised as a relatively benign condition with a favourable prognosis, serious complications do occur, including thromboembolic events such as LV thrombus formation, cardioembolic strokes and acute arterial occlusion.<sup>3 15</sup>

The incidence of thromboembolic complications in TTC remains debatable. A 2014 multicentre study reported a 1% risk of stroke and a 3% risk of LV thrombus among 209 patients with TTC.<sup>21</sup> In contrast, a 2018 review that included four studies with 282 patients showed a 9.3% prevalence of thromboembolic events and/or LV thrombus; notably, only one patient with LV thrombus was a man.<sup>16</sup> A 2017 study with 541 patients from a multicentre international registry reported an incidence of 2.2% (12/541 patients) for LV thrombus; of those 12, 2 suffered stroke.<sup>3</sup> Interestingly, all patients who developed LV thrombus in this study were women and presented with an apical ballooning pattern. A troponin-I level >10 ng/mL in this study was associated with LV thrombus. Another study from 2017 based on 72 patients with TTC reported an event rate of 2.8% for stroke within 30 days and 4.2% within 12 months after initial diagnosis.<sup>22</sup> A 2020 multicentre study showed the prevalence of intraventricular thrombus and embolism at 3.3%. The median incident time was 2 days from TTC diagnosis, yet the interval for thromboembolic phenomena ranged from 0 to 38 days.<sup>23</sup>

A paucity of literature exists pertaining to the natural history and pathogenesis of LV thrombus formation in primary TTC. Thrombus formation risk is reportedly greatest 2–5 days after symptom onset, as LV function is most likely to be depressed during this period.<sup>3 15 16</sup> It is thought that turbulence within the ballooned ventricle, in addition to inflammatory milieu and enhanced platelet adhesiveness (due to increased catecholamines), may initiate thrombus formation.<sup>3 15</sup> Multiple studies have found the applicability of Virchow's triad of stasis, subendocardial ischaemia with

inflammation and hypercoagulable state to be present in patients with ACS leading to LV thrombus formation.<sup>24–29</sup> A similar, yet incompletely understood, cascade of mechanisms may be responsible for LV thrombus in TTC patients. For example, C reactive protein (CRP) has emerged as an independent predictor for thromboembolic events in TTC.<sup>2 23</sup> Elevated inflammatory markers herald coagulation cascade hyperactivity and are associated with endothelial dysfunction.<sup>23 30</sup> Of note, our patient developed an especially large LV thrombus over a very short time period without any evidence of declining left ventricular ejection fraction as compared admission. This suggests that factors such as hypercoagulability and endothelial dysfunction may have particularly contributed to the current case.

This case uniquely highlights the complication of cardioembolic stroke in a patient with rapidly developing (<150 min), impressively large, LV thrombus in the setting of TTC. The patient had classic predisposing risk factors: postmenopausal African-American woman with elevated troponin on admission, biventricular apical akinesis pattern on TTE and negative coronary catheterisation. The patient's hypercoagulability work-up was negative, but the spiculated lung nodule with her smoking history may suggest an undiagnosed malignancy promoting a hypercoagulable state. CRP was not measured on admission. This case illustrates the importance of considering factors such as age, gender, troponin I and CRP levels, TTE pattern and underlying hypercoagulability in recognising the patients who may be at high risk for thromboembolic complications. It also highlights the importance of maintaining high clinical suspicion and repeating serial TTE in TTC patients during the high risk period for LV thrombus formation (2–5 days after symptom onset). While the exact mechanism for thrombus formation remains to be explored, it is possible that a combination of low LV systolic function, endothelial dysfunction and a hypercoagulable state result in rapid thrombus formation in TTC. Finally, despite known thromboembolic complications, no guidelines exist for anticoagulation in TTC. Studies have recommended oral anticoagulation for patients with apical ballooning pattern and troponin-I level >10 ng/mL on admission.<sup>3 9</sup> In patients with TTC with risk factors for development of thromboembolic complications, anticoagulation should be considered.

**Contributors** All authors were involved in the acute in-hospital care of the patient. EWM drafted the manuscript for intellectual content, edited drafts and figures for continuity, and prepared the final manuscript submission. GKB drafted the manuscript for intellectual content, edited drafts, and created figure 1. ANS provided critical review of the manuscript and created figure 2. JWP conducted critical review of the manuscript.

**Funding** The authors have not declared a specific grant for this research from any funding agency in the public, commercial or not-for-profit sectors.

**Competing interests** None declared.

**Patient consent for publication** Obtained.

**Provenance and peer review** Not commissioned; externally peer reviewed.

### ORCID iD

Eric W Moffet <http://orcid.org/0000-0002-4168-7596>

### REFERENCES

- Herath HMMTB, Pahalagamage SP, Lindsay LC, *et al.* Takotsubo cardiomyopathy complicated with apical thrombus formation on first day of the illness: a case report and literature review. *BMC Cardiovasc Disord* 2017;17:176–76.
- El-Battrawy I, Gietzen T, Lang S, *et al.* Short- and long-term incidence of thromboembolic events in takotsubo syndrome as compared with acute coronary syndrome. *Angiology* 2019;70:838–43.

## Learning points

- ▶ Takotsubo cardiomyopathy (TTC) is a reversible cause of left ventricular systolic dysfunction which can be complicated by large left ventricle (LV) thrombus formation and embolism over a very short time period.
- ▶ A pro-inflammatory state and endothelial dysfunction, plus depressed left ventricular function, may create an environment apt for rapid formation of a large intraventricular thrombus.
- ▶ Serial transthoracic echocardiograms (TTE) can assist in discovering LV thrombus among patients with TTC especially in days following symptom onset when the risk is highest.
- ▶ A review of several studies indicated risk factors precluding for thromboembolic complications including female gender, apical akinesis pattern on TTE, troponin-I level >10 ng/mL, elevated C reactive protein level and African-American race.
- ▶ While no guidelines for anticoagulation exist, the above risk factors can be considered while making anticoagulation decisions in patients with TTC.

- 3 Santoro F, Stiermaier T, Tarantino N, *et al.* Left ventricular thrombi in takotsubo syndrome: incidence, predictors, and management: results from the GEIST (German Italian stress cardiomyopathy) registry. *J Am Heart Assoc* 2017;6:e006990.
- 4 Okamura A, Miake J, Miyagi M, *et al.* Ultra-Rapid and massive thrombus formation in cardiac chambers. *Intern Med* 2015;54:1947–47.
- 5 Ikeda A, Yamachika E, Mizutani M, *et al.* Rapid occurrence of left ventricular thrombus associated with platinum-based chemotherapy plus cetuximab for the treatment of metastatic squamous cell carcinoma of the head and neck: a case report. *Mol Clin Oncol* 2017;7:833–6.
- 6 Kimura K, Tanabe-Hayashi Y, Noma S, *et al.* Images in cardiovascular medicine. rapid formation of left ventricular giant thrombus with takotsubo cardiomyopathy. *Circulation* 2007;115:e620–1.
- 7 De Marchena E, Mesa J, Pomenti S, *et al.* Thrombus formation following transcatheter aortic valve replacement. *JACC Cardiovasc Interv* 2015;8:728–39.
- 8 Wakabayashi K, Dohi T, Daida H. Takotsubo cardiomyopathy associated with epilepsy complicated with giant thrombus. *Int J Cardiol* 2011;148:e28–30.
- 9 Moscatelli S, Montecucco F, Carbone F, *et al.* An emerging cardiovascular disease: takotsubo syndrome. *Biomed Res Int* 2019;2019:1–9.
- 10 Daoko J, Rajachandran M, Savarese R, *et al.* Biventricular takotsubo cardiomyopathy: case study and review of literature. *Tex Heart Inst J* 2013;40:305–11.
- 11 Mitsuma W, Kodama M, Ito M, *et al.* Thromboembolism in takotsubo cardiomyopathy. *Int J Cardiol* 2010;139:98–100.
- 12 Kim SM, Aikat S, Bailey A, *et al.* Takotsubo cardiomyopathy as a source of cardioembolic cerebral infarction. *BMJ Case Rep* 2012;2012:bcr2012006835.
- 13 Sanghvi SK, Harris DM. Anticoagulation and stress-induced cardiomyopathy. *J Thromb Thrombolysis* 2019;47:1–7.
- 14 Otani Y, Tokunaga K, Kawauchi S, *et al.* Cerebral infarction arising from takotsubo cardiomyopathy: case report and literature review. *NMC Case Rep J* 2016;3:119–23.
- 15 Medina de Chazal H, Del Buono MG, Keyser-Marcus L, *et al.* Stress Cardiomyopathy Diagnosis and Treatment: JACC State-of-the-Art Review. *J Am Coll Cardiol* 2018;72:1955–71.
- 16 Heckle MR, McCoy CW, Akinseye OA, *et al.* Stress-Induced thrombus: prevalence of thromboembolic events and the role of anticoagulation in takotsubo cardiomyopathy. *Ann Transl Med* 2018;6:4.
- 17 Y-Hassan S, Holmin S, Abdula G, *et al.* Thrombo-Embolic complications in takotsubo syndrome: review and demonstration of an illustrative case. *Clin Cardiol* 2019;42:312–9.
- 18 Ghadri JR, Cammann VL, Jurisic S, *et al.* A novel clinical score (InterTAK diagnostic score) to differentiate takotsubo syndrome from acute coronary syndrome: results from the International takotsubo registry. *Eur J Heart Fail* 2017;19:1036–42.
- 19 Ghadri J-R, Wittstein IS, Prasad A, *et al.* International expert consensus document on takotsubo syndrome (Part I): clinical characteristics, diagnostic criteria, and pathophysiology. *Eur Heart J* 2018;39:2032–46.
- 20 Sato H, Tateishi H, Uchida T, *et al.* Clinical aspect of myocardial injury: from ischemia to heart failure. *Kagaku Hyoronsha* 1990;55–64.
- 21 Schneider B, Athanasiadis A, Schwab J, *et al.* Complications in the clinical course of tako-tsubo cardiomyopathy. *Int J Cardiol* 2014;176:199–205.
- 22 Abanador-Kamper N, Kamper L, Wolfertz J, *et al.* Temporarily increased stroke rate after takotsubo syndrome: need for an anticoagulation? *BMC Cardiovasc Disord* 2018;18:117–17.
- 23 Ding KJ, Cammann VL, Szawan KA, *et al.* Intraventricular thrombus formation and embolism in takotsubo syndrome: insights from the International takotsubo registry. *Arterioscler Thromb Vasc Biol* 2020;40:279–87.
- 24 Garg P, van der Geest RJ, Swoboda PP, *et al.* Left ventricular thrombus formation in myocardial infarction is associated with altered left ventricular blood flow energetics. *Eur Heart J Cardiovasc Imaging* 2019;20:108–17.
- 25 Delemarre BJ, Visser CA, Bot H, *et al.* Prediction of apical thrombus formation in acute myocardial infarction based on left ventricular spatial flow pattern. *J Am Coll Cardiol* 1990;15:355–60.
- 26 Celik S, Baykan M, Erdöl C, *et al.* Doppler-Derived mitral deceleration time as an early predictor of left ventricular thrombus after first anterior acute myocardial infarction. *Am Heart J* 2000;140:772–6.
- 27 Solheim S, Seljeflot I, Lunde K, *et al.* Frequency of left ventricular thrombus in patients with anterior wall acute myocardial infarction treated with percutaneous coronary intervention and dual antiplatelet therapy. *Am J Cardiol* 2010;106:1197–200.
- 28 Vaitkus PT, Barnathan ES. Embolic potential, prevention and management of mural thrombus complicating anterior myocardial infarction: a meta-analysis. *J Am Coll Cardiol* 1993;22:1004–9.
- 29 Delewi R, Zijlstra F, Piek JJ. Left ventricular thrombus formation after acute myocardial infarction. *Heart* 2012;98:1743–9.
- 30 Hein TW, Singh U, Vasquez-Vivar J, *et al.* Human C-reactive protein induces endothelial dysfunction and uncoupling of eNOS in vivo. *Atherosclerosis* 2009;206:61–8.

Copyright 2020 BMJ Publishing Group. All rights reserved. For permission to reuse any of this content visit <https://www.bmj.com/company/products-services/rights-and-licensing/permissions/>  
BMJ Case Report Fellows may re-use this article for personal use and teaching without any further permission.

Become a Fellow of BMJ Case Reports today and you can:

- ▶ Submit as many cases as you like
- ▶ Enjoy fast sympathetic peer review and rapid publication of accepted articles
- ▶ Access all the published articles
- ▶ Re-use any of the published material for personal use and teaching without further permission

#### Customer Service

If you have any further queries about your subscription, please contact our customer services team on +44 (0) 207111 1105 or via email at [support@bmj.com](mailto:support@bmj.com).

Visit [casereports.bmj.com](http://casereports.bmj.com) for more articles like this and to become a Fellow