

A Rare Clinical Antity; Pure Gerstmann Syndrome

Gulnur Tekgol Uzuner, MD,* Ahmet Ubur, MD,† Murat Erten, MD,‡ and Nevzat Uzuner, MD§

Gerstmann syndrome is defined as a tetrad including agraphia, acalculia, finger agnosia, and right-left disorientation. In the case studies presented in the literature, it has been reported that Gerstmann syndrome usually appears as an incomplete tetrad of symptoms or accompanied by cognitive deficits including aphasia, alexia, apraxia and some perceptual disorders. Here, we present of the patient with left angular and supramarginal gyrus infarction affecting the parietal lobe. In addition to the symptoms mentioned above, the patient had alexia and anomia as well. We discussed the clinic appearance and reviewed the current literature.

Key Words: Gerstmann syndrome—Acalculia—agraphia—Finger agnosia—Right-left disorientation

© 2020 Elsevier Inc. All rights reserved.

Introduction

Gerstmann syndrome was first described in 1924 by an Austrian neuroscientist Josef Gerstmann in a 52-year-old female patient.¹ In the first case of Gerstmann, who had complaints of memory and writing difficulties, right hemianopia, difficulty in calculating and disability in recognizing the right-left side of his body were detected in the first case of the patient.¹ Another case has been reported with right-left discrimination disorder.² Gerstmann reported two other similar cases in 1927 with agraphia and finger agnosia.³ Gerstmann continued to publish similar cases in 1930, and by combining all the cases he studied, he defined the new syndrome, which he called Gerstmann syndrome, which

contains the symptom complex of acalculia, agraphia, right-left discrimination, and finger agnosia.⁴ In this case, we evaluated the symptoms and findings of a patient with left angular, supramarginal gyrus infarction, and in addition to pure Gerstmann syndrome tetrad in the light of the information in the literature.

Case

The 63-year-old male patient, who used his right hand, applied to the emergency room due to loss of power and speech disorder on the right side, which lasted 45 minutes. In his past medical history, he has diabetes mellitus, hypertension disease and coronary artery bypass graft operation. He did not use cigarettes and alcohol. Vital findings in the emergency room were within normal limits. Electrocardiography (ECG) was in normal sinus rhythm. The patient was aware in his neurological examination and had full orientation and cooperation. There was no motor deficit. Coordination tests were complete. Visual field impairment, central facial paralysis and aphasia were not detected. In the neuropsychological evaluation, difficulty in naming simple objects, astereogenesis, alexia, agraphia, right-left discrimination disorder (Ex: inability to hold the right knee with his left hand), and acalculia characterized by not performing simple mathematical calculations. There was finger agnosia, characterized by the disability of naming his own fingers and not

From the *Department of Neurology and Cerebrovascular Disease, Eskisehir Osmangazi University, 26040, Turkey; †Department of Neurology and Cerebrovascular Disease, Eskisehir Osmangazi University, 26040, Turkey; ‡Department of Neurology and Cerebrovascular Disease, Eskisehir Osmangazi University, 26040, Turkey; and §Department of Neurology and Cerebrovascular Disease, Eskisehir Osmangazi University, Eskisehir, 26040, Turkey.

Received June 14, 2020; accepted July 11, 2020.

Address correspondence to Uzuner, Nevzat Prof. in Neurology, MD, FESO Department of Neurology and Cerebrovascular Disease, Eskisehir Osmangazi University, Eskisehir, Turkey E-mail: nevzatuzuner@gmail.com.

1052-3057/\$ - see front matter

© 2020 Elsevier Inc. All rights reserved.

<https://doi.org/10.1016/j.jstrokecerebrovasdis.2020.105161>

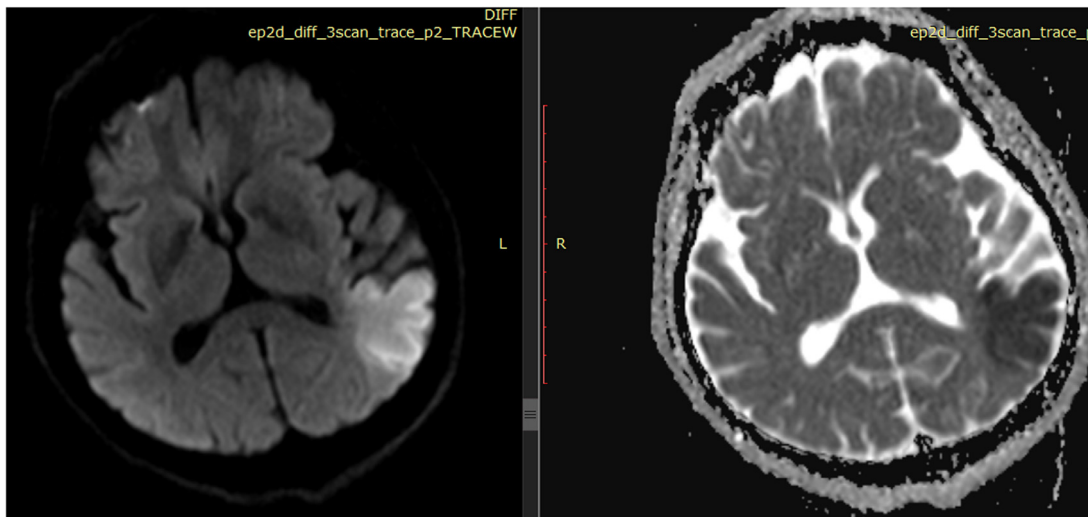


Fig. 1. Diffusion restriction in the left angular and Supramarginal Gyrus regions.

being able to command the specific finger given by the examiner to touch the opposite finger of the examiner.

Biochemical tests were normal. There was no pathology in computed brain tomography (CT). Major vessel occlusion was not detected on brain-neck CT angiography. Due to the lack of major vascular occlusion, endovascular intervention and low National Institutes of Health Stroke Scale (NIHSS) score, thrombolytic therapy was not considered, and the patient was admitted to the neurology stroke unit with dual antiaggregant therapy. Cranial diffusion Magnetic Resonance (MR) imaging revealed diffusion restriction in the left angular and supramarginal gyrus regions (Fig. 1). Anticoagulant therapy was initiated upon the detection of apical thrombus at transthoracic echocardiography.

Discussion

In the case studies presented in the literature, Gerstmann syndrome usually appears as a missing tetrad or accompanied by cognitive deficits including aphasia, alexia, apraxia, and some perceptual disorders. In 194 patients with acute stroke (by alexia in Zukic et al.,) agraphia, acalculia or different combinations were detected, and only two patients were found to have a tetrad of pure Gerstmann syndrome and concluded that pure Gerstmann syndrome was a rare clinical entity.⁵

One case report is presented from Turkey in 2014 was accompanied alexia in addition to the pure Gerstmann syndrome tetrad. In lesion localization, it was detected as left angular and supramarginal gyrus infarction.⁶

Roeltgen et al. In 1983, they published a 62-year-old male patient with four elements of Gerstmann syndrome without pure aphasia, alexia, structural apraxia or memory impairment as a case of pure Gerstmann syndrome.⁷ In the cranial CT examination of this patient, a cortical

lesion of the superior angular gyrus that spreads to the supramarginal gyrus and minimally superior parietal lobule was observed.⁷ Mayer et al. found a subcortical focal ischemic lesion in the left angular gyrus in the cranial magnetic resonance examination of a 59-year-old male patient with four elements of Gerstmann syndrome in 1999.⁸ Morris et al. In their cortical stimulation study in 1984, they created isolated Gerstmann syndrome by stimulating the area between angular and supramarginal gyrus.⁹ Ando et al. reported that Gerstmann syndrome did not only develop due to left angular gyrus dysfunction but could also occur in left middle frontal gyrus lesions.¹⁰

Sakurai et al., because of their evaluations on three patients in 2010, reported that only agraphia occurs in the angular gyrus lesion, but agraphia and alexia occurs in the lesions when extending from the angular gyrus to the middle occipital gyrus.^{11–13} Koseoglu et al. agreed with Gerstmann in their case report in 2014.⁶ In our case, the presence of agraphia and alexia due to extension of the lesion from the angular gyrus to the middle occipital gyrus confirms both studies.

Zhou et al., in their assessment of seven patients in 2002, finger agnosia, acalculia, agraphia, right-left discrimination disorder, which is the tetrad of Gerstmann syndrome, were detected in three patients, which have additional aphasia, three patients with anomia, and two patients with structural apraxia. In two patients, alexia was also accompanied as in our case. Cranial tomography of seven patients was performed and left parietal lesion was detected in all of them.

Since pure Gerstmann syndrome is a rare event, we would like to share our findings in a patient diagnosed Gerstmann syndrome, who have additional symptoms and signs, which are probable related to lesion localisation, lesion extension or deficient of the collateral circulation.

Authorship

The manuscript has been read and approved by all the authors, that the requirements for authorship have been met.

Declaration of Competing Interest

None.

Ethical approval

All procedures performed in studies involving human participants were in accordance with the ethical standards of the institutional research committee and with the 1964 Helsinki declaration and its later amendments or comparable ethical standards.

References

1. Gerstmann J. Finger agnosia: A specific disturbance of orientation of your own body. *Wien Klin Wschr* 1924;37(10):1010-1012.
2. Herrmann G, Pötzl O. *Über die Agraphie und ihre local diagnostischen Beziehungen*. Berlin: Krager; 1926.
3. Gerstmann J. Finger agnosia and isolated agraphia; a new syndrome. *Z Ges Neurol Psychiat* 1927;108(2):152-177.
4. Gerstmann J. To symptomatology of brain lesions in the transition region of the lower parietal and middle occipital convolution. *Dt Z Nervheilk* 1930;116(2):46-49.
5. Zukic, S, Mrkonjic, Z, Sinanovic, O, Vidovic, M, & Kojic, B. Gerstmann's syndrome in acute stroke patients. *Acta Informatica Medica* 2012; 20 (4), 242–243.
6. Köseoğlu E, Akgül N, Kendirci M. *Türkiye Klinikleri. J Case Rep* 2014;22(3).
7. Roeltgen DP, Sevush S, Heilman KM. Pure Gerstmann's syndrome from a focal lesion. *Arch Neurol* 1983;40(1):46-47.
8. Mayer E, Martory MD, Pegna AJ, Landis T, Delavelle J, Annoni JM. A pure case of Gerstmann syndrome with a subangular lesion. *Brain* 1999;122(Pt 6):1107-1120.
9. Morris HH, Lüders H, Lesser RP, Dinner DS, Hahn J. Transient neuropsychological abnormalities (including Gerstmann's syndrome) during cortical stimulation. *Neurology* 1984;34(7):877-883.
10. Ando Y, Sawada M, Morita M, Kawamura M, Nakano I. Incomplete Gerstmann syndrome with a cerebral infarct in the left middle frontal gyrus. *Rinsho Shinkeigaku* 2009;49(9):560-565.
11. Sakurai Y, Asami M, Mannen T. Alexia and agraphia with lesions of the angular and supramarginal gyri: evidence for the disruption of sequential processing. *J Neurol Sci* 2010;288(1-2):25-33.
12. Zhou XQ, He R, Liu Z, Wang CQ. *Zhongguo Yi Xue Ke Xue Yuan Xue Bao*. 2002; 24(5):510–1.
13. Rusconi E. *Handb Clin Neurol* 2018;151:395-411.