

Stroke and COVID19: Not only a large-vessel disease

Giovanni Frisullo, PhD, Simone Bellavia, MD, Irene Scala, MD, Carla Piano, PhD, Roberta Morosetti, PhD, Valerio Brunetti, MD, Paolo Calabresi, PhD, and Giacomo Della Marca, PhD

Recent evidence has underlined the association between large-vessel stroke and COVID-19, probably due to a proinflammatory and prothrombotic microenvironment induced by SARS-CoV-2. Here, we report the case of a young fit woman affected by COVID-19 without any flu-like symptom, who suffered from speech disorder and left hemiparesis. Brain magnetic resonance evidenced two small acute brain infarctions in right perirolandic cortex without signs of previous ischemic lesions and hemorrhagic infarction. Diagnostic workup excluded cardiac embolic sources, acquired and inherited thrombophilia or autoimmune diseases. Two positive nasopharyngeal swab tests and high titers of serum specific IgA/IgM confirmed COVID-19 diagnosis. In our case stroke seems to be the only manifestation of SARS-CoV-2 infection. Therefore the hypothesis of an underlying viral infection, as COVID-19, should be investigated in all the cases of small vessel cryptogenic stroke.

Keywords: Stroke—COVID19—Small-vessel occlusion—SARS-COV-2

© 2020 Elsevier Inc. All rights reserved.

A 49-year-old woman, scrub nurse in a COVID-19 hospital, was admitted to the Emergency Department for sudden onset of speech disorder and left hemiparesis with no fever, cough or wheezing. The neurological examination showed dysarthria, left facial weakness, left hemiparesis and hemianesthesia with National Institutes of Health Stroke Scale score (NIHSS) of 7. Brain angiography CT ruled out parenchymal lesions and large vessel occlusion (LVO). The patient received intravenous alteplase with improvement of neurological symptoms (NIHSS=1). Since she was positive for SARS-CoV-2 by RT-PCR from nasopharyngeal swab, the patient was transferred to COVID-19 subintensive Unit. Complete blood count revealed lymphocytosis ($4.09 \times 10^9/L$) while systemic

inflammatory and prothrombotic factors were normal. Furthermore, an EEG registration evidenced no irritative anomalies. Chest x-ray and CT did not show interstitial lung involvement.

SARS-COV-2 infection was confirmed by high titers of serum specific IgA/IgM and by the second positive nasopharyngeal swab sample.

Brain magnetic resonance imaging revealed two small cortical acute ischemic lesions in the right pre and post-central gyrus, without signs of previous ischemic lesions and hemorrhagic infarction (Fig. 1). Cardiac workup consisting of electrocardiogram, cardiac telemetry monitoring, transthoracic and transesophageal echocardiography excluded arrhythmias, cardiac source of emboli, or patent foramen ovale. Serological testing for malignancy, thrombophilia and autoimmune diseases were negative.

After two consecutive negative swab she was discharged with a diagnosis of COVID-19 related cryptogenic stroke.

Our report describes the case of a young fit woman without cerebrovascular risk factors or family history of neurological diseases who developed a cryptogenic stroke.

Although the relationship between viral infection and ischemic stroke is well-established, the pathogenic mechanism in the induction of cerebrovascular diseases is still

From the IRCCS – UOC Neurologia – Dipartimento di Scienze dell’Invecchiamento, Neurologiche, Ortopediche e della Testa-Collo, Fondazione Policlinico Universitario A. Gemelli IRCCS, Largo A Gemelli, 8 – 00168, Rome, Italy.

Received May 20, 2020; revision received June 9, 2020; accepted June 14, 2020.

Corresponding author. E-mail: giovanni.frisullo@policlinicogemelli.it.

1052-3057/\$ - see front matter

© 2020 Elsevier Inc. All rights reserved.

<https://doi.org/10.1016/j.jstrokecerebrovasdis.2020.105074>

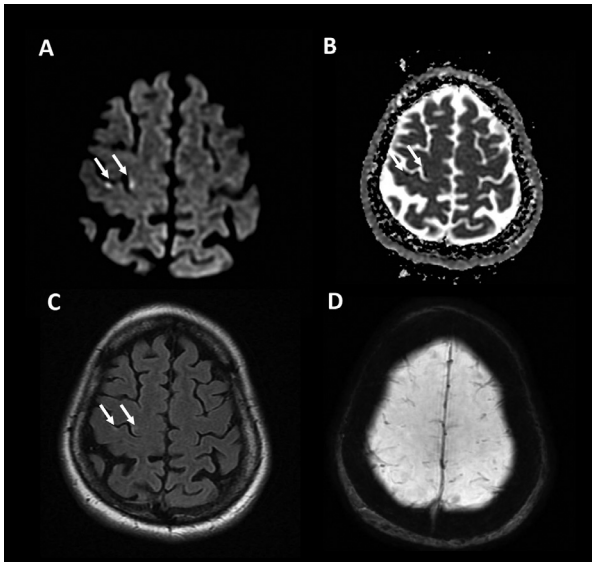


Fig. 1. An axial section of diffusion-weighted (Panel A), Apparent diffusion coefficient (ADC) (Panel B), Fluid attenuation inversion recovery (FLAIR) (Panel C) and Susceptibility-weighted Angiography (SWAN) (Panel D) images of the brain shows two small acute brain infarctions (arrows) in right perirolandic cortex without signs of previous ischemic lesions and hemorrhagic infarction.

debated.¹ SARS-COV-2 seems to be able to create a pro-inflammatory microenvironment and to induce a pro-thrombotic state, predisposing to thrombogenesis and

LVO stroke.^{2,3} In our patient we did not detect any alteration of serum inflammation markers,^{3,4} such as D-dimer, fibrinogen, C-reactive protein, erythrocyte sedimentation rate. Therefore, it is possible to hypothesize that SARS-COV-2 might penetrate the endothelial cells of the arterioles in the cerebral cortex inducing direct or immuno-mediated damage, without inducing a systemic response. This hypothesis is supported by the absence, in our patient, of flu or systemic symptoms, being stroke the only manifestation of COVID-19. In conclusion, the search for underlying viral infection such as COVID-19 should be investigated in all the cases of small vessel cryptogenic stroke.

References

1. Valderrama EV, Humbert K, Lord A, et al. Severe acute respiratory syndrome coronavirus 2 infection and ischemic stroke. *Stroke* 2020. STROKEAHA120030153.
2. Oxley TJ, Mocco J, Majidi S, et al. Large-vessel stroke as a presenting feature of Covid-19 in the young. *N Engl J Med* 2020;382:e60.
3. Umaphathi T, Kor AC, Venketasubramanian N, et al. Large artery ischaemic stroke in severe acute respiratory syndrome (SARS). *J Neurol* 2004;251:1227-1231.
4. Cui S, Chen S, Li X, Liu S, Wang F. Prevalence of venous thromboembolism in patients with severe novel coronavirus pneumonia. *J Thromb Haemost* 2020.