

A verified period of normal neurologic status in a young victim of abusive head trauma

Rene Romig, Angela Doswell, Danielle Horton, Cree Kachelski, Jim Anderst*

Children's Mercy Hospital, Kansas City, MO, United States

ARTICLE INFO

Keywords:

Abusive head trauma
Injury timing
Child physical abuse
Child protection

ABSTRACT

Abusive head trauma (AHT) is the leading cause of child physical abuse fatalities, and survivors frequently face life-long consequences. Victims of AHT are typically infants, and many are subjected to repeat AHT if not accurately identified and protected. Identifying the timing of AHT is often a medical-forensic process, and investigative personnel use the determination of timing of AHT to guide safety decisions for the child victim. If the medical-forensic timing of AHT is incorrect, a child could be inappropriately placed and/or an innocent caregiver could be subject to prosecution. Victims of AHT who suffer severe/permanent injury are felt to demonstrate symptoms immediately after the trauma, and AHT victims with milder injury are thought to generally have persistent or recurrent clinical signs shortly after the trauma. Periods of normal neurologic appearance, in which a victim of AHT is completely asymptomatic for an extended time after the trauma, are felt to be rare and have not been well characterized in the literature. This case involves a 2-month-old infant victim of AHT who presented to medical care with mild neurologic symptoms that resolved without intervention from medical personnel. While hospitalized, the infant had an asymptomatic period of approximately 38 hours prior to more severe neurologic decompensation, then later returned to neurologic baseline. This case highlights the challenges in accurately timing AHT in very young victims who return to neurologic baseline by characterizing a verifiable prolonged period of normal neurologic appearance and function after AHT.

1. Introduction

Abusive head trauma (AHT) is the leading cause of child physical abuse fatalities. Survivors frequently face life-long consequences.¹ In the past two decades, clear links have been established between the specifics of the clinical history of presentation, physical findings, radiological findings and AHT, facilitating increased confidence in diagnosis.²⁻⁵ However, at times, identifying the timing of AHT remains challenging. As timing based on neuroimaging is imprecise,⁶ clinical symptoms are often the most useful tool.^{7,8} Consensus has been reached that children with fatal head trauma generally have altered mental status immediately subsequent to the injury and do not experience prolonged periods of normal behavior/neurologic status occurring after head injury, prior to later decompensation.⁹ In non-fatal victims of AHT who demonstrate neurologic compromise, the moment of onset of clear and persistent neurologic symptoms may provide the best estimate of timing of AHT; however, prolonged periods of normal neurologic function may occur due to a few clinical scenarios.^{7,8} Cases with a detailed, verifiable delay in symptoms in infants after head trauma are lacking, particularly for

infants who eventually return to neurologic baseline. Most studies examining neurologic status after head trauma involve children older than most AHT victims or children who suffer permanent neurologic damage or death.¹⁰⁻¹⁶ Studies examining neurologic status in relation to timing of trauma in infants who survive AHT typically rely on a single witness account, often the alleged perpetrator, with minimal details regarding the infant's neurologic state and/or progression of symptoms.^{11,17}

We present the case of a 2-month-old male victim of AHT and a verifiable extended period of normal neurologic status after the abusive trauma. The infant then suffered neurological decompensation but subsequently returned to neurologic baseline. This case uniquely demonstrates the challenges in accurately timing non-fatal AHT in very young infants, specifically when the infant returns to neurologic baseline.

2. Case report

A previously well 2-month-old male infant born at 38 weeks via

* Corresponding author. Division of Child Adversity and Resilience, Children's Mercy Hospital, 2401 Gillham Road, Kansas City, MO, 64108, United States.
E-mail address: jdanderst@cmh.edu (J. Anderst).

<https://doi.org/10.1016/j.jflm.2020.102024>

Received 27 February 2020; Received in revised form 9 July 2020; Accepted 13 July 2020

Available online 18 July 2020

1752-928X/© 2020 Elsevier Ltd and Faculty of Forensic and Legal Medicine. All rights reserved.

vaginal delivery with an uncomplicated neonatal course was brought to a hospital by emergency medical services (EMS). The infant's mother last saw him at 0300 after she fed him a bottle. At that time, he was behaving normally, smiling and cooing, with no abnormal symptoms. From that point on, the infant was in the sole care of his biological father who reported that the infant remained normal until shortly after noon when he experienced an episode of choking/emesis and limpness without color change. The father denied any trauma or other abnormal events prior to this episode. The father performed 1 minute of CPR and subsequently noted spontaneous movement. He then called 911 at 1249. On arrival at 1258, EMS noted that the infant was spontaneously breathing, although respirations were labored and irregular, and he had a fixed gaze without tracking. Despite normal pulse oximetry readings, he was placed on 15 L of oxygen via non-rebreather mask. At 1310, the patient was noted to develop recurrent 10–15 second episodes of decorticate posturing followed by decerebrate posturing every 2 minutes. These episodes spontaneously resolved by the time of arrival at the emergency department (ED) at 1327. At that time, the infant was noted by EMS personnel to be “pink” and “breathing on his own very well”.

Initial vitals taken at 1331 in the ED were normal for age. On the initial physician assessment, the infant was alert without signs of respiratory distress or neurological compromise. Flexion of left extremities was documented in multiple resident physician (physicians in training) notes, with one indicating concern for seizure. The attending pediatric emergency medicine physician noted that the flexion slowly relaxed with consoling and did not document any concern for active seizing in the emergency department. The infant was given 40 mg/kg of levetiracetam at 1354 and 0.1 mg/kg of IV midazolam at 1356 as a “precaution for seizures due to the EMS report of prior posturing.” Radiology imaging obtained at that time included: CT head without contrast, CT spine without contrast, skeletal survey, and CT abdomen/pelvis with contrast. Imaging demonstrated no evidence of fracture or intrabdominal trauma, but CT head revealed a thin left convexity SDH with greatest thickness in right parasagittal area near the vertex (5mm in maximal thickness) without midline shift (Fig. 1). The infant was then admitted to the pediatric intensive care unit (PICU) at approximately 1450 on room air with normal vitals. The initial exam in the PICU revealed spontaneous eye opening and equal limb movements without evidence of focal defects.

While in the PICU, ophthalmology was consulted and detected bilateral “diffuse retinal hemorrhages, involving all layers, too numerous to count, many with white centers extending from posterior

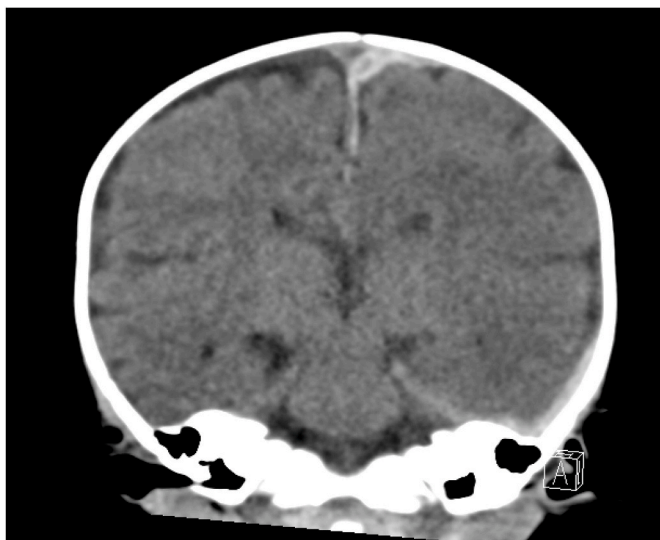

Fig. 1. Coronal view of head CT on day of admission.

pole to ora serrata”. A brain MRI revealed “small left frontotemporal hemorrhagic cerebral contusions as well as additional multifocal tiny nonhemorrhagic left temporal parenchymal contusions” and “bilateral supratentorial and infratentorial convexity subdural hemorrhages” (Figs. 2 and 3). Brain MRA and MRV were normal, as was spine MRI.

The PICU stay constituted the majority of a 38-h period of normal neurological status as documented by 11 normal nursing neurological checks, each of which included an assessment of pupil appearance and reactivity, response to verbal and tactile stimulation, muscle tone and strength and spontaneous movements, and physical exams by 7 different medical services. The infant did not receive any medications during this time. He had no emesis or other symptoms of head trauma, but he was not provided with oral feeds during the PICU stay. Due to his prolonged normal neurologic status, he was transferred to the floor.

After transfer to the floor, the infant initially tolerated oral bottle feeds provided by nursing staff, then subsequently had 2 episodes of bradycardia to the mid-80s and 3 episodes of emesis. The infant then exhibited seizure activity described as eyes rolling back and leg/hand twitching and multiple self-resolving desaturations to the 70s and 80s. He received 30 mg/kg levetiracetam and 0.1mg/kg lorazepam as treatment. Approximately 35 minutes later, the infant was noted to be apneic and unresponsive for 60 seconds with oxygen saturation to 47%; bag-mask ventilation was initiated, and a code blue was called. He then received 20 mg/kg fosphenytoin and was transferred to the PICU on 15 L/minute oxygen via face mask, after which the seizures stopped. Repeat head CT (Fig. 4) again showed SDH, now measuring 7mm in maximal thickness.

Within 24 hours of the transfer back to the PICU, the infant had multiple seizures requiring 3 doses of fosphenytoin (each 10 mg/kg) and two doses of lorazepam (each 0.1 mg/kg). He was then initiated on oxcarbazepine maintenance. Levetiracetam was continued and enteral feeds via nasogastric tube were started. Four days after transfer to the PICU, he had been seizure-free for 24 h. After six days in the hospital, he had no neurologic abnormalities and was discharged to his maternal great-grandmother. Three weeks after discharge, a repeat skeletal survey revealed no fractures. Children's Protective Services substantiated the allegation of abuse. The child remained in the care of his maternal great-grandmother for the next 12 months. During that period, he remained seizure free with no neurologic abnormalities.

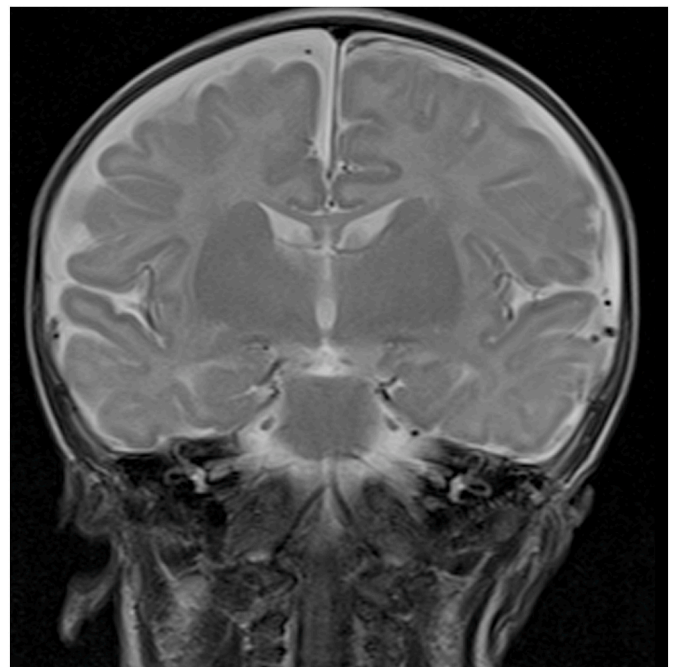


Fig. 2. T2 Coronal MRI of brain.

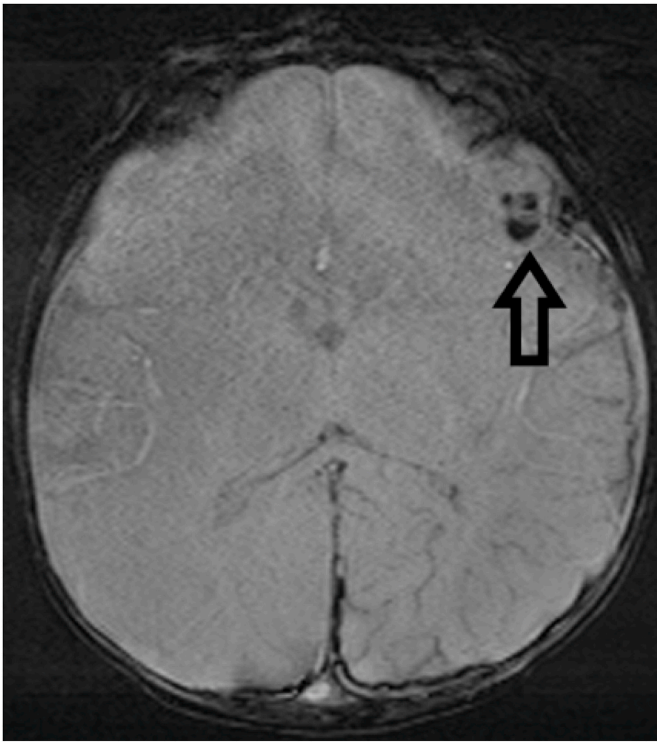


Fig. 3. Axial view of susceptibility weighted imaging sequence of brain MRI. The arrow demonstrates the left fronto-temporal hemorrhagic contusion.

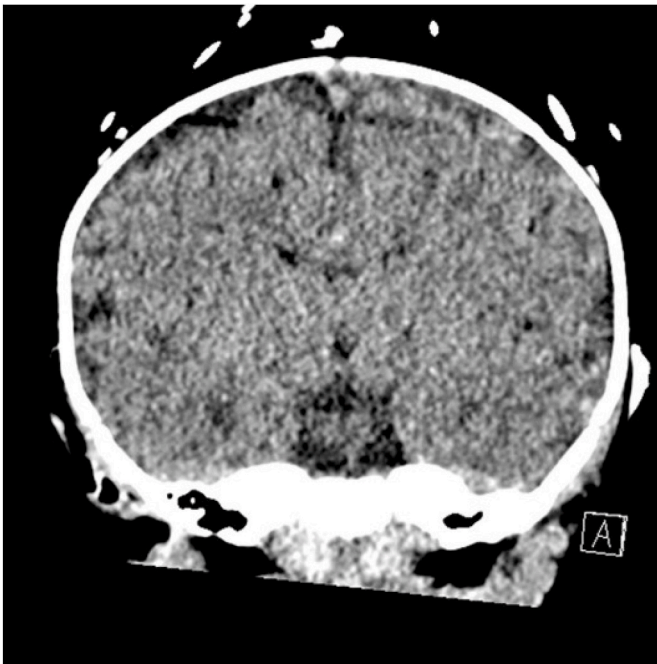


Fig. 4. Coronal view of head CT after 38 hours of normal neurologic status followed by more severe neurologic decompensation.

Written authorization for this case report was obtained by the infant's legal guardian.

3. Discussion

This case describes a 2-month-old infant with findings most consistent with AHT who had a symptom-free interval between minor and

more severe neurologic symptoms. Even if the infant had neurologic decompensation at the moment of seizure prophylaxis in the ED, he would have had at least an approximately 25 to 30-min period of normal neurologic status after AHT. After the one-time seizure prophylaxis, he had an approximately 38-h period of normal neurologic status after AHT. Had the infant not presented to care after his initial, minor symptoms of injury, it is possible that his more severe, later neurologic compromise would have occurred under supervision of different caregivers who had no knowledge of the prior symptoms. In such a case, if the AHT was incorrectly timed to the onset of severe neurologic symptoms, investigation into the potential perpetrator would likely have been limited to these caregivers, potentially missing a critical contact or suspect. This case demonstrates the challenges of accurately timing AHT in young infants who suffer no apparent long-term neurologic complications.

There is generalized agreement that children who have severe, permanent brain injury have immediate or near immediate and persistent symptoms after the head injury.⁷⁻⁹ Studies involving perpetrator admissions demonstrate immediate and persistent symptoms in cases with sufficient details.^{17,18} Other studies evaluating for possible delayed neurologic decompensation typically involve subjects older than most victims of AHT and/or subjects who suffer permanent neurologic damage or death.¹⁰⁻¹⁶ However, there is also a degree of agreement that, in some cases, particularly those in which the child eventually returns to neurologic baseline, a period of normal neurologic appearance is possible.⁷⁻⁹ The potential for delayed decompensation is most often attributed to gradually increasing intracranial pressure (from an expanding extra-axial hematoma or brain swelling due to hypoxia, sodium imbalance, progressive injury, or other causes) or post-traumatic seizures. Although the possibility for such situations is acknowledged, published scientific support that includes verified behaviors during and duration of the period of normal neurologic appearance in young infants is lacking. This case demonstrates a verifiable, extended, asymptomatic interval after AHT in a young victim who had delayed neurologic decompensation but subsequently returned to neurologic baseline.

The infant involved in this case most likely suffered later neurologic decompensation due to post-traumatic seizures, and, possibly, to expansion of the SDH. Though post-traumatic seizures are a well-known entity, they are not well described in relation to the timing of AHT or in severity after AHT. In the case described here, the child's neurologic decompensation was severe and persistent for days. This type of neurologic decompensation typically occurs immediately after severe head trauma. Additionally, the infant rapidly transitioned from asymptomatic to significantly symptomatic, as can be seen immediately after head trauma. He did receive minor medical interventions at initial presentation (1 dose each of 2 prophylactic anti-epileptic medications and oxygen), despite having returned to neurologic baseline. It is possible that the anti-epileptic medications contributed to the duration of the normal neurologic appearance. The half-lives of the medications, approximately 5 hours for levetiracetam and 1-3 hours for midazolam,^{19,20} suggest that the medications were unlikely to be providing clinically significant seizure suppression during much of the hospitalization. Additionally, levetiracetam reaches maximal concentration 1 hour after dosing, and typically requires twice daily dosing for two days to reach steady state levels.¹⁹ The effect of midazolam peaks at 15-30 minutes after dosage.²⁰ As such, it seems unlikely that the single doses of the two medications fully explain the lengthy period of apparent normal neurologic function after the AHT.

Although the child's presence in the hospital provides documented evidence of his normal neurologic status after AHT, the hospital interventions create a limitation. In addition to the potential contribution of the anti-epileptic medications to the duration of the period of normal neurologic status, the infant was not given oral feeds for a period in the PICU as he awaited sedation for the MRI. He initially tolerated oral feeds after transfer to the floor, but then began vomiting in the hours prior to his neurologic decompensation. It is unknown if he would have tolerated

oral feeds during the period when they were not allowed.

Cases such as this are rare in the literature likely because they are rare in clinical presentation. Despite the rarity of such a presentation, the existence of a well-documented, prolonged period of normal neurologic function after AHT must be considered when attempting to time the occurrence of AHT in very young infants who return to neurologic baseline. Physicians involved in such cases should obtain a detailed history regarding any prior symptoms or caregivers over the days preceding initial presentation and acknowledge that timing such cases is difficult in some situations. Information from this case should not be applied to older infants or infants who die or suffer permanent neurologic sequelae. Future studies are needed detailing the clinical course of very young victims of head trauma to better inform medical-forensic decision-making.

Human and animal rights

This research was performed in accordance with the ethical standards as laid down in the 1964 Declaration of Helsinki and its later amendments or comparable ethical standards. This article does not contain any studies with animals performed by any of the authors.

Funding source

None.

Contributor's statement page

Dr. Anderst conceptualized the case report and reviewed and revised the manuscript.

Dr. Romig conceptualized the case report, drafted the initial manuscript, and reviewed and revised the manuscript.

Drs. Kachelski, Horton, and Doswell critically analyzed and interpreted the information in the case report, reviewed the manuscript for scientific accuracy and revised the manuscript.

All authors approved the final manuscript as submitted and agree to the accountable for all aspects of the work.

Declaration of competing interest

Dr. Anderst has provided paid expert testimony and case consultation in cases of alleged child abuse. The remaining authors declare that

they have no conflict of interest.

References

- Christian CW, the Committee on Child Abuse and Neglect. The evaluation of suspected child physical abuse. *Pediatrics*. 2015;135(5):e1337.
- Vinchon M, Foort-Dhellemmes S, Desurmont M, Delestret I. Confessed abuse versus witnessed accidents in infants: comparison of clinical, radiological, and ophthalmological data in corroborated cases. *Childs Nerv Syst*. 2010;26:637–645.
- Piteau SH, Ward MGK, Barrowman NJ, Plint AC. Clinical and radiographic characteristics associated with abusive and nonabusive head trauma: a systematic review. *Pediatrics*. 2012;130:315–323.
- Maguire SA, Kemp AM, Lumb RC, Farewell DM. Estimating the probability of abusive head trauma: a pooled analysis. *Pediatrics*. 2011;128(3):e550–564.
- Kemp AM, Jaspan T, Griffiths J, et al. Neuroimaging: what neuroradiological features distinguish abusive from non-abusive head trauma? A systematic review. *Arch Dis Child*. 2011;96(12):1103–1112.
- Sieswerda-Hoogendoorn T, Postema FAM, Verbaan D, Majoie CB, Van Rijn RR. Age determination of subdural hematomas with CT and MRI: a systematic review. *Eur J Radiol*. 2014;83(7):1257–1268.
- Hymel KP, Deye KP. Abusive head trauma. In: Jenny C, ed. *Child Abuse and Neglect: Diagnosis, Treatment, and Evidence*. first ed. St. Louis, MO: Elsevier; 2011:349–358.
- Boos S. Abusive head trauma as a medical diagnosis. In: Frasier L, Rauth-Farley K, Alexander R, Parrish R, eds. *Abusive Head Trauma in Infants and Children*. first ed. St. Louis, MO: G.W. Medical Publishing; 2006:49–71.
- Choudhary AK, Servaes S, Slovis TL, et al. Consensus statement on abusive head trauma in infants and young children. *Pediatr Radiol*. 2018;48:1048–1065.
- Arbogast KB, Margulies SS, Christian CW. Initial neurologic presentation in young children sustaining inflicted and unintentional fatal head injuries. *Pediatrics*. 2005;116:180–184.
- Biron DL, Shelton D. Functional time limit and onset of symptoms in infant abusive head trauma. *J Paediatr Child Health*. 2007;43:60–65.
- Gilles EE, Nelson MD. Cerebral complications of nonaccidental head injury in childhood. *Pediatr Neurol*. 1998;19:119–128.
- Gilliland MGF. Interval duration between injury and severe symptoms in nonaccidental head trauma in infants and young children. *J Forensic Sci*. 1998;43(3):723–725.
- Willman KY, Bank DE, Senac M, Chadwick DL. Restricting the time of injury in fatal inflicted head injuries. *Child Abuse Negl*. 1997;21(10):929–940.
- Humphreys RP, Hendrick EB, Hoffman HJ. The head-injured child who “talks and dies”. *Child's Nerv Syst*. 1990;6:139–142.
- Snoek JW, Minderhoud JM, Wilmink. Delayed deterioration following mild head injury in children. *Brain*. 1984;107:15–36.
- Starling SP, Patel S, Burke BL, Sirotnak A, Stronks S, Rosquist P. Analysis of perpetrator admissions to inflicted traumatic brain injury in children. *Arch Pediatr Adolesc Med*. 2004;158:454–458.
- Adamsbaum C, Grabar S, Mejean N, Rey-Salmon C. Abusive head trauma: judicial admissions highlight violent and repetitive shaking. *Pediatrics*. 2010;126:546–555.
- United States Food and Drug Administration. https://www.accessdata.fda.gov/drugsatfda_docs/label/2009/021035s078s080,021505s021s024tbl.pdf. Accessed 11/15/19.
- United States Food and Drug Administration. https://www.accessdata.fda.gov/drugsatfda_docs/label/2017/208878Orig1s000tbl.pdf. Accessed 11/15/19.