

# A Rare Presentation of Neurobrucellosis in a 6-Year-Old Pediatric Patient with Sagittal Sinus Thrombosis

Ozden Turel<sup>1</sup> Fatouma Khalif Abdillah<sup>2</sup> Can Yilmaz Yozgat<sup>3</sup> Selcuk Uzuner<sup>4</sup>  
 Burcu Bursal Duramaz<sup>1</sup> Tolga Turan Dundar<sup>5</sup> Mehmet Hakan Seyithanoglu<sup>5</sup> Osman Yesilbas<sup>4</sup>  
 Nurettin Onur Kutlu<sup>4</sup>

<sup>1</sup> Department of Pediatric Infectious Diseases, Bezmialem Vakif University, Istanbul, Turkey

<sup>2</sup> Department of Pediatrics, Bezmialem Vakif University, Istanbul, Turkey

<sup>3</sup> Faculty of Medicine, Bezmialem Vakif University, Istanbul, Turkey

<sup>4</sup> Department of Pediatric Critical Care Medicine, Bezmialem Vakif University, Istanbul, Turkey

<sup>5</sup> Department of Neurosurgery, Bezmialem Vakif University, Istanbul, Turkey

Address for correspondence Can Yilmaz Yozgat, MD, Faculty of Medicine, Adnan Menderes Bulvarı, Vatan Caddesi, Bezmialem Vakif University, 34093, Istanbul, Turkey  
 (e-mail: yozgatyilmaz@gmail.com).

Neuropediatrics 2021;52:48–51.

## Abstract

Brucellosis is one of the most common zoonosis worldwide. It is still endemic in many regions of the world. A 6-year-old female was admitted to the emergency department (ED) due to a sudden change in consciousness, urinary incontinence, vomiting, and difficulty in walking. Neurological examination demonstrated abducens nerve paralysis, mild-to-moderate motor deficit in hemiparesis in the left arm. Brain magnetic resonance imaging showed a hemorrhagic focus at the right frontal lobe and thrombosis in the superior sagittal sinus of the brain. The diagnosis of neurobrucellosis was confirmed by identifying *Brucella* spp. in the blood culture on the day 6 of pediatric intensive care unit admission; thus, trimethoprim-sulfamethoxazole and rifampicin, and ceftriaxone were promptly initiated. Despite neuroprotective management and acetazolamide, the patient's neurological problems and high intracranial pressure (ICP) persisted. An external ventricular drainage tube and a Codman ICP monitor were placed to be on the consent vigilance of the patient's neurological condition. The patient's ICP continued to increase despite the current treatment regimen; therefore, a decompressive bitemporal craniectomy was performed. The ICP level of the patient returned to its normal range immediately after the craniectomy. The patient did not have any notable neurologic sequelae at the first-year follow-up. Neurobrucellosis is a rare complication of systemic brucellosis and may present as meningitis, encephalitis, myelitis, radiculitis, and/or neuritis. Herein, we describe a six-year-old girl with brucellosis complicated with cerebral vein thrombosis. This case illustrates the need for close monitoring of patients with unexplained neurological signs or symptoms for brucellosis in endemic areas.

## Keywords

- ▶ neurobrucellosis
- ▶ childhood
- ▶ pediatric intensive care unit
- ▶ cerebral vein thrombosis

received  
 February 5, 2020  
 accepted  
 April 22, 2020  
 published online  
 October 5, 2020

© 2020, Thieme. All rights reserved.  
 Georg Thieme Verlag KG,  
 Rüdigerstraße 14,  
 70469 Stuttgart, Germany

DOI <https://doi.org/10.1055/s-0040-1715482>.  
 ISSN 0174-304X.

## Introduction

Brucellosis is one of the most common zoonosis worldwide. Humans can become infected due to the consumption of products from infected animals such as unpasteurized milk, cheese, and insufficiently cooked or raw meat. Infection may also result from the entry of the bacteria from infected animals or their secretions through skin lesions, conjunctiva, or inhalation of contaminated dust or aerosols. Although it has virtually been eliminated from most developed countries, it is still endemic in many regions of the world. The disease is seen in Mediterranean areas, in parts of South and Central America, and East and Western Africa. Syria and Mongolia have the highest incidences (>500 per million annually).<sup>1</sup> The annual incidence in Turkey is 262 per million, and cases are mainly detected in eastern regions. Contact with infected animals or consumption of food products like unpasteurized milk and cheese are the main routes of transmission of disease from animals to humans.<sup>2</sup> Neurobrucellosis is a rare complication of systemic brucellosis and may present as meningitis, encephalitis, myelitis, radiculitis, and/or neuritis.<sup>3-5</sup> Herein, we describe a 6-year-old girl with brucellosis complicated with cerebral vein thrombosis.

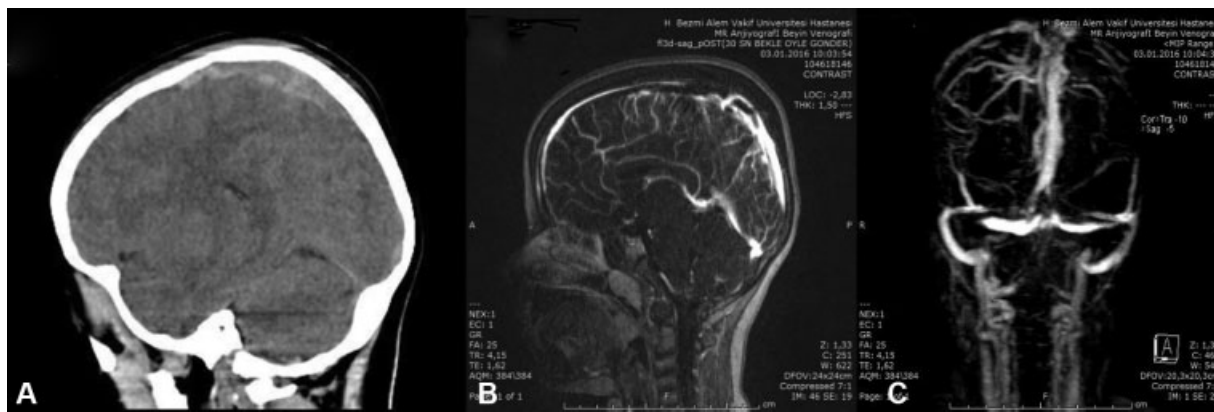
## Case Report

A 6-year-old female was admitted to the emergency department (ED) due to a sudden change in consciousness, urinary incontinence, vomiting, and difficulty in walking. Total 2 days before her ED admission, she had been evaluated by a practitioner in family medicine due to her ongoing fever, headache, and pain on the right leg. The practitioner prescribed the patient with amoxicillin-clavulanic acid for her upper respiratory tract infection. Past medical and family history was unremarkable for any chronic illnesses. Her twin brother had no complaints. The family was living in as the same city as the ED admission and denied any travel activities. On the ED admission, the patient was lethargic and her Glasgow Coma Scale score was 9 out of 12. Physical examination in the ED revealed a bodyweight of 25 kg (75–90 p), a height of 118 cm (50 p), a pulse rate of 139/min, a respiratory rate of 30/min, a capillary refill time of less than 2 seconds, a body temperature of 36.5°C, a blood pressure of 120/60 mm/Hg, and an oxygen saturation of 95% at room air. Neurological examination in the ED was also done, and the examination demonstrated abducens nerve paralysis, mild-to-moderate motor deficit in hemiparesis in the left arm, and positive Babinski reflex was observed on the left arm as well. Nuchal rigidity was noted to be absent. Laboratory investigations showed a hemoglobin level of 10.8 g/dL, a white blood cell count of 12,450/mm<sup>3</sup> (60% neutrophils), a platelet count of 20,000/mm<sup>3</sup>, an erythrocyte sedimentation rate of 18 mm/h, a C-reactive protein level of 3.2 mg/dL, a prothrombin time of 20 seconds, an activated partial thromboplastin time of 31.6 seconds, a D-dimer level of 47,755 ng/mL, a serum glucose of 133 mg/dL, a creatinine level of 0.45 mg/dL, a blood urea nitrogen level of 9.81 mg/dL, a sodium level of 139 mmol/L, a potassium level of 3.95 mEq/L, a calcium level of 9.6 mg/dL, an alanine aminotransferase level of

16 U/L and an aspartate aminotransferase level of 22 U/L. Brain magnetic resonance imaging (MRI) showed a hemorrhagic focus at the right frontal lobe and thrombosis in the superior sagittal sinus of the brain (→ Fig. 1A). MRI and MR venography also demonstrated thrombosis, which located in superior sagittal sinus and hemorrhagic focus in the frontal lobe (→ Fig. 1B, C). Our multidisciplinary team, including neurology, critical care, and infectious diseases, decided to hospitalize the patient in the pediatric intensive care unit (PICU) for high level of care.

Upon PICU admission, ceftriaxone and clarithromycin were promptly initiated. Peripheral blood smear showed hemolysis, and the direct Coombs' test was positive. Thereof, pediatric hematology was consulted, and intravenous immunoglobulin 0.4 g/kg was given following the department's consultation. When the patient's platelet count went up to 50,000/mm<sup>3</sup>, low molecular heparin enoxaparin was started. The bone marrow examination was normal. Plasma homocysteine (2.17 μmol/L) and C3, C4 complement levels were noted to be within normal limits. Antinuclear antibody and antiribosomal P antibodies were negative. Since anticardiolipin IgG was positive (20.3 GPL/mL), our primary diagnoses to the patient's condition was the antiphospholipid syndrome. Therefore, plasma exchange was performed for five consecutive days. On day 6 of PICU admission, the serum tube agglutination test (SAT) for brucellosis was positive at the rate of 1/360. One day later, we received the results from the microbiology laboratory, which revealed that her blood culture grew pleomorphic gram-negative bacilli, and 72 hours later, were identified as *Brucella* spp. On day 6 of PICU admission, clarithromycin was stopped; trimethoprim-sulfamethoxazole and rifampicin were added to the patient's current treatment. Despite neuroprotective management (30 degrees elevation and midline position of the head, intravenous 3%), the patient's neurological problems persisted.

On day 10 of PICU admission, acetazolamide was given to reduce intracranial pressure (ICP). An external ventricular drainage (EVD) tube and a Codman ICP monitor were placed to be on the consent vigilance of the patient's neurological condition. Cerebrospinal fluid (CSF) taken from EVD tube. The fluid analysis revealed a cell count of five cells per mm<sup>3</sup>, a protein level of 11.7 mg/dL, and an average glucose level of 69 mg/dL. On day 11 of PICU admission, the patient's ICP continued to increase despite the current treatment regimen; therefore, a decompressive bitemporal craniectomy was performed. The ICP level of the patient returned to its normal range immediately after the craniectomy. There was not any notable development of the patient's situation until the 40th day of PICU admission. On PICU day 40, she was discharged from the PICU and then transferred to a regular pediatric ward. The patient stayed in the pediatric ward for 3 weeks until ceftriaxone treatment was completed, and she was then discharged from the hospital. Total 6 months later, cranioplasty was done. The patient continued to be attended at our pediatric neurology outpatient clinic for a year and was still under the treatment of rifampicin and cotrimoxazole for 9 months. The patient did not have any notable neurologic sequelae at the first-year follow-up and returned to her normal state of health.



**Fig. 1** (A) The coronal section of computerized tomography of the brain showing hemorrhagic focus in frontal lobe and thrombosis in superior sagittal sinus. (B) The axial cross-section of cranial magnetic resonance showing thrombosis in superior sagittal sinus. (C) The coronal cross-section of cranial magnetic resonance image showing thrombosis in superior sagittal sinus.

## Discussion

Poor control of infection in animals is the main reason for the ongoing prevalence of brucellosis in humans. *Brucella melitensis*, which can cause severe forms of brucellosis, is the most prevalent strain in Turkey.<sup>6</sup> Cetinkaya et al reported that a history of brucellosis in the family, raising livestock at home, preparing dried cow dung, and cleaning of stables were the most common factors increasing the seropositivity rate in Turkey.<sup>7</sup> Making cheese, butter, and cream with raw milk were other risk factors. The patient in this report had neither a family history of brucellosis nor contact with animals. Consumption of ice cream prepared from unpasteurized milk was probably the responsible cause of the infection.

Due to nonspecific signs and symptoms, brucellosis can be confused with many diseases. Clinical manifestations of the condition are fever, sweating, fatigue, loss of appetite, headache, and musculoskeletal symptoms. Neurological complications are rare (2–7%).<sup>8</sup> Patients may present with meningitis, encephalitis, polyradiculopathy, brain abscess, epidural abscess, meningovascular complications, peripheral neuropathy, and psychosis. Venous sinus thrombosis is uncommonly associated with neurobrucellosis. Zaidan and Tahan first described this rare combination in 1999<sup>9</sup> later, few authors emphasized venous complications due to brucellosis. Lima et al reported a 30-year-old woman who was presented with thrombosis of the lateral and sigmoid sinus and ipsilateral internal jugular vein.<sup>10</sup> *Brucella* spp. was identified in the CSF sample by a polymerase chain reaction. Inan et al mentioned transient ischemic attack, vasculopathy changes, intracerebral granulomas, and basal ganglia infarction in a 17-year-old patient with brucellosis.<sup>11</sup> Uncontrolled seizures may develop due to cerebral venous thrombosis with neurobrucellosis.<sup>12</sup> Adaletli et al presented a 22-year-old man with central facial paralysis, hemiparesis, and mild left-sided hemihypoesthesia.<sup>13</sup> Digital subtraction angiography demonstrated occlusion of branches of the right middle cerebral artery, multiple vascular cut-off signs, vascular contour irregularities, and stenosis. Vasculopathy in brucellosis involves the skin, extremities, aorta, or cerebral vessels. The mechanisms for cerebrovascular involvement in neurobrucellosis are explained as either a hemorrhagic

stroke, which is caused by a rupture of a mycotic aneurysm or the inflammatory process of the vessels with consequent lacunar infarcts, small hemorrhages, or venous thrombosis. The patient in our report presented with thrombocytopenia, prolonged PT, increased D-dimer, and sagittal sinus thrombosis. The causes of thrombophilia, including proteins C, protein S, and antithrombin-III deficiency; factor V Leiden homozygous mutation; autoimmune diseases; anticardiolipin and antiphospholipid antibody syndromes were excluded. The diagnosis of brucellosis was confirmed by the growth of *Brucella* in blood culture and serum agglutination test (SAT) result of 1:360.

Laboratory diagnosis of brucellosis is made by isolating *Brucella* in blood, bone marrow, or other body fluids. However, blood cultures are positive in only 16 to 30% of patients with neurobrucellosis, and CSF cultures are positive in less than 50% cases.<sup>10</sup> Serological tests for the detection of antibodies such as the Rose Bengal test and SAT are also helpful. Major antigens that are used in serological tests are smooth lipopolysaccharides of the external membrane (S-LPS) and internal proteins. SAT detects antibodies formed against S-LPS. Positive titers consist of 1:80 in nonendemic regions and 1:160 in endemic areas. *Brucella* immunoglobulin (Ig)M and IgG antibodies can also be detected by enzyme-linked immunosorbent assay. The Coombs and immunocapture agglutination (Brucellacapt) tests may be more suitable in relapsing brucellosis and patients with persistent active infection. The 2-mercaptoethanol agglutination test measures IgG antibodies only and is an excellent marker to follow the disease's activity after the initiation of therapy. *Brucella* microagglutination test is also advised by the Centers for Disease Control and Prevention. CSF Coombs' test agglutination with a cut-off titer  $\geq 1:8$  was found to have a high sensitivity and specificity (0.94 and 0.96, respectively) in neurobrucellosis.<sup>14</sup>

There is variability in the literature regarding the optimal antimicrobial regimen and the appropriate duration of the treatment of pediatric neurobrucellosis. Regimens must include antibiotics that can penetrate the mesencephalic barrier, maintain proper concentrations in the CSF, and maintain intracellular action. Monotherapies can characterize high-relapse rates; hence, multiple drug regimens should

presently be used. The recommended treatment should be given at least for 2 months with a combination of two or three drugs that cross the blood–brain barrier, such as doxycycline, rifampicin, and trimethoprim-sulfamethoxazole or ceftriaxone, is recommended as well. In a previous report, among 24 neurobrucellosis adult patients more than 90% received a doxycycline plus rifampicin combination for 6 months. Ceftriaxone (4 g/day, intravenous) was added for the first month.<sup>15</sup>

## Conclusion

In conclusion, in endemic areas like Turkey, patients with unexplained neurological signs or symptoms should be evaluated for brucellosis. Clinical suspicion and accurate evaluation of a patient's history are the most critical clues in regards to the diagnosis and treatment of brucellosis.

### Authors' Contributions

All authors participated in creating content for the manuscript, editing, and provided final approval for submission. No undisclosed authors contributed to the manuscript.

### Ethical Approval

This article does not contain any studies with human participants or animals performed by any of the authors. Institutional Review Board approval was not required for this case report.

### Funding

None.

### Conflict of Interest

None declared.

### Acknowledgments

Permission was granted by the parents and patient to publish the case report.

## References

- 1 Pappas G, Papadimitriou P, Akritidis N, Christou L, Tsianos EV. The new global map of human brucellosis. *Lancet Infect Dis* 2006;6(02):91–99
- 2 Boschirolu ML, Ouahrani-Bettache S, Foulongne V, et al. The *Brucella suis virB operon* is induced intracellularly in macrophages. *Proc Natl Acad Sci U S A* 2002;99(03):1544–1549
- 3 Buzgan T, Karahocagil MK, Irmak H, et al. Clinical manifestations and complications in 1028 cases of brucellosis: a retrospective evaluation and review of the literature. *Int J Infect Dis* 2010;14(06):e469–e478
- 4 Gul HC, Erdem H, Bek S. Overview of neurobrucellosis: a pooled analysis of 187 cases. *Int J Infect Dis* 2009;13(06):e339–e343
- 5 Al-Sous MW, Bohlega S, Al-Kawi MZ, Alwatban J, McLean DR. Neurobrucellosis: clinical and neuroimaging correlation. *AJNR Am J Neuroradiol* 2004;25(03):395–401
- 6 Ceran N, Turkoglu R, Erdem I, et al. Neurobrucellosis: clinical, diagnostic, therapeutic features and outcome. Unusual clinical presentations in an endemic region. *Braz J Infect Dis* 2011;15(01):52–59
- 7 Cetinkaya F, Naçar M, Aydin T, Koç N, Gökahmetoğlu S. Prevalence of brucellosis in the rural area of Kayseri, Central Anatolia, Turkey. *Int J Infect Dis* 2006;10(02):179–181
- 8 Gotuzzo E, Pappas G. Brucellosis. In: Guerrant RL, Walker DH, Weller PF, eds. *Tropical Infectious Diseases: Principles, Pathogens and Practice*. 3rd ed. Philadelphia: Saunders Elsevier; 2011:271
- 9 Zaidan R, Al Tahan AR. Cerebral venous thrombosis: a new manifestation of neurobrucellosis. *Clin Infect Dis* 1999;28(02):399–400
- 10 Lima JI, Canelas CF, Veiga AS, Carvalho DM. Neurobrucellosis and venous sinus thrombosis: an uncommon association. *Rev Soc Bras Med Trop* 2016;49(03):383–385
- 11 Inan AS, Ceran N, Erdem I, et al. Neurobrucellosis with transient ischemic attack, vasculopathic changes, intracerebral granulomas and basal ganglia infarction: a case report. *J Med Case Reports* 2010;4:340
- 12 Faraji F, Didgar F, Talaie-Zanjani A, Mohammadbeigi A. Uncontrolled seizures resulting from cerebral venous sinus thrombosis complicating neurobrucellosis. *J Neurosci Rural Pract* 2013;4(03):313–316
- 13 Adaletli I, Albayram S, Gurses B, et al. Vasculopathic changes in the cerebral arterial system with neurobrucellosis. *AJNR Am J Neuroradiol* 2006;27(02):384–386
- 14 Guven T, Ugurlu K, Ergonul O, et al. Neurobrucellosis: clinical and diagnostic features. *Clin Infect Dis* 2013;56(10):1407–1412
- 15 Kursun E, Turunc T, Demiroglu Y, Arslan H. Evaluation of four hundred and forty seven brucellosis cases. *Intern Med* 2013;52(07):745–750