




# Successful endovascular treatment of pediatric basilar infectious (mycotic) aneurysm: a case report and review of the literature

Kittiphop Somboonnithiphol<sup>1</sup> · Ekachat Chanthanaphak<sup>1</sup> · Sirintara (Pongpech) Singhara Na Ayudhaya<sup>1</sup> · Chaiyos Khongkhatithum<sup>2</sup> · Bandit Sirilert<sup>1</sup> 

Received: 22 July 2020 / Accepted: 1 October 2020  
© Springer-Verlag GmbH Germany, part of Springer Nature 2020

## Abstract

**Background** Intracranial infectious aneurysms are rarely reported in children; in particular, they are very rare in infants. They are mostly related to infective endocarditis and are usually located in the anterior cerebral vasculature. A ruptured intracranial infectious aneurysm is a catastrophic event associated with high morbidity and mortality rates.

**Case report** An 8-month-old female infant presented with a prolonged fever without any organ-specific symptoms. Two weeks after admission, she had a high-grade fever with drowsiness; the cerebrospinal fluid (CSF) examination indicated meningitis. Despite treatments with empiric antibiotic and antiviral agents, both her condition and the repeated CSF profiles worsened. The ineffective medications were promptly changed to susceptible antibiotic after the CSF culture showed *Pseudomonas aeruginosa*. Three days after the diagnosis of meningitis, the patient suddenly developed seizures and alteration of consciousness. The computerized tomography and angiography (CT and CTA) of the brain demonstrated a diffuse subarachnoid hemorrhage (SAH) with intraventricular hemorrhage (IVH) and a lobulated fusiform aneurysm at the proximal basilar artery, suggestive of a ruptured basilar infectious aneurysm. Endovascular treatment was planned and a transarterial occlusion of the vertebrobasilar junction was performed in order to disrupt inflow of the aneurysm. After endovascular intervention, her clinical symptoms gradually improved and the patient was discharged after completing a 4-week course of antibiotics. At the 6-week follow-up, she was doing well without neurological deficit.

**Conclusion** To our knowledge, this is the first reported case of a ruptured basilar infectious aneurysm in an infant secondary to *Pseudomonas* meningitis, successfully treated with parent artery occlusion.

**Keywords** Infectious (mycotic) aneurysm · Basilar artery · Infant · Intracranial hemorrhage · Endovascular parent artery occlusion

## Introduction

Intracranial infectious aneurysms are rarely reported in children; in particular, they are very rare in infants [23]. Infectious aneurysms develop secondary to the invasion of infectious pathogens in the tunica media causing vascular wall necrosis. Infectious pathogens frequently disseminate through the arterial wall via the bloodstream, principally

from infective endocarditis. Occasionally, pathogens can invade the arterial wall from the surrounding infected tissues, such as the cavernous sinus thrombophlebitis, bacterial meningitis, subdural empyema, or orbital cellulitis [2, 9, 14]. Infectious aneurysms are mainly located at anterior circulation arteries, especially distal branches of middle cerebral artery, and seldom affect posterior circulation [10, 14, 27]. The reported ruptured risk of an infectious aneurysm is less than 2%; however, significant morbidity and mortality exist after rupture and are reported in up to 80% of cases [10, 14]. Here, we report a ruptured basilar infectious aneurysm in an 8-month-old female with successful endovascular parent artery occlusion and a good outcome. The pathogenesis, causative pathogens, treatment, and prognosis of pediatric basilar infectious aneurysms are discussed and reviewed in this article.

✉ Bandit Sirilert  
ballband.alex@gmail.com

<sup>1</sup> Department of Radiology, Ramathibodi Hospital, Mahidol University, 270 Rama VI Road, Bangkok 10400, Thailand

<sup>2</sup> Department of Pediatrics, Ramathibodi Hospital, Mahidol University, 270 Rama VI Road, Bangkok 10400, Thailand

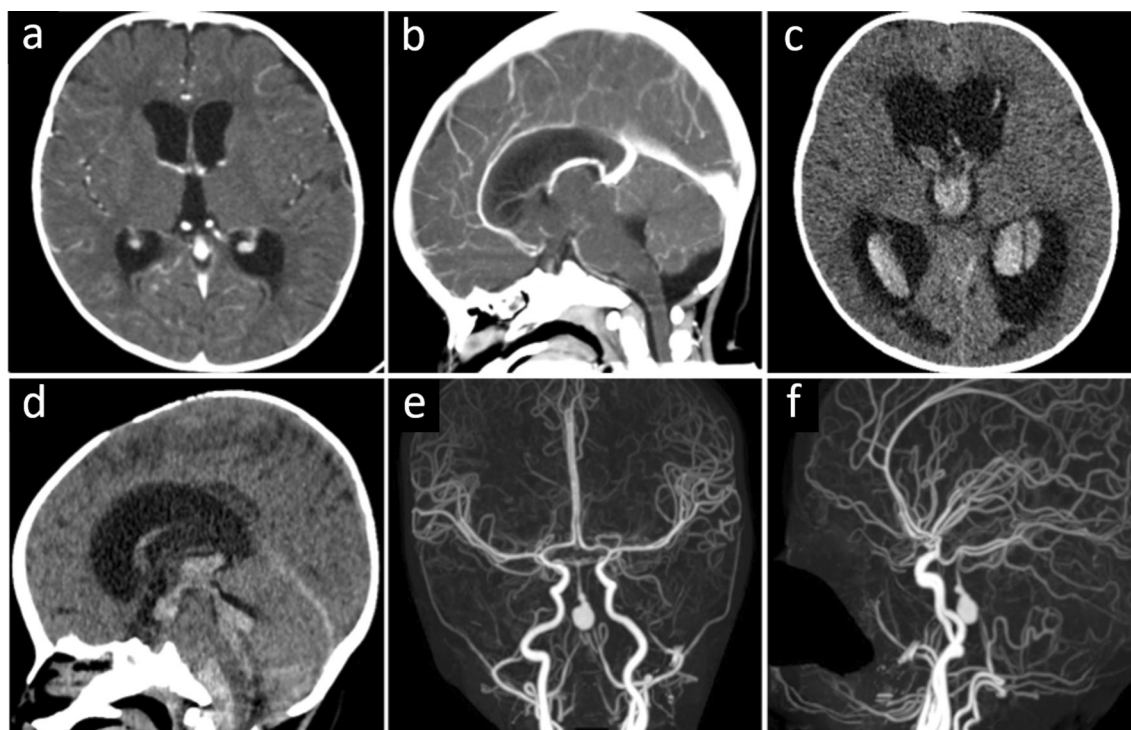
## Patient case report

A previously healthy 8-month-old female infant was admitted to the primary hospital with a prolonged fever without any organ-specific symptoms. Two weeks after admission, she had high-grade fever with drowsiness. Lumbar puncture was performed and CSF examination indicated meningitis. Empiric treatment with cefotaxime and acyclovir was administered. A contrast-enhanced CT of the brain revealed mild communicating hydrocephalus without space-occupying lesion or gross aneurysm (shown in Fig. 1a, b). Despite treatment with antibiotic and antiviral agents, her condition worsened with an increased degree of drowsiness. The repeated CSF examination showed worse profiles, and the previous CSF culture grew *Pseudomonas aeruginosa*, hence the antibiotic and antiviral agents were promptly changed to meropenem. One day after susceptible antibiotic administration, the patient suddenly developed seizures and drowsiness. The non-contrasted CT of the brain demonstrated a diffuse subarachnoid hemorrhage (SAH) with intraventricular hemorrhage (IVH); she was then transferred to our institute.

After admission to our hospital, she experienced seizures again and a further decreased level of consciousness. The neurological examination showed drowsiness, normotonia with equal movement of all extremities, and positive Brudzinski and Kernig signs. Repeated CT and CTA of the brain revealed progression of SAH and communicating

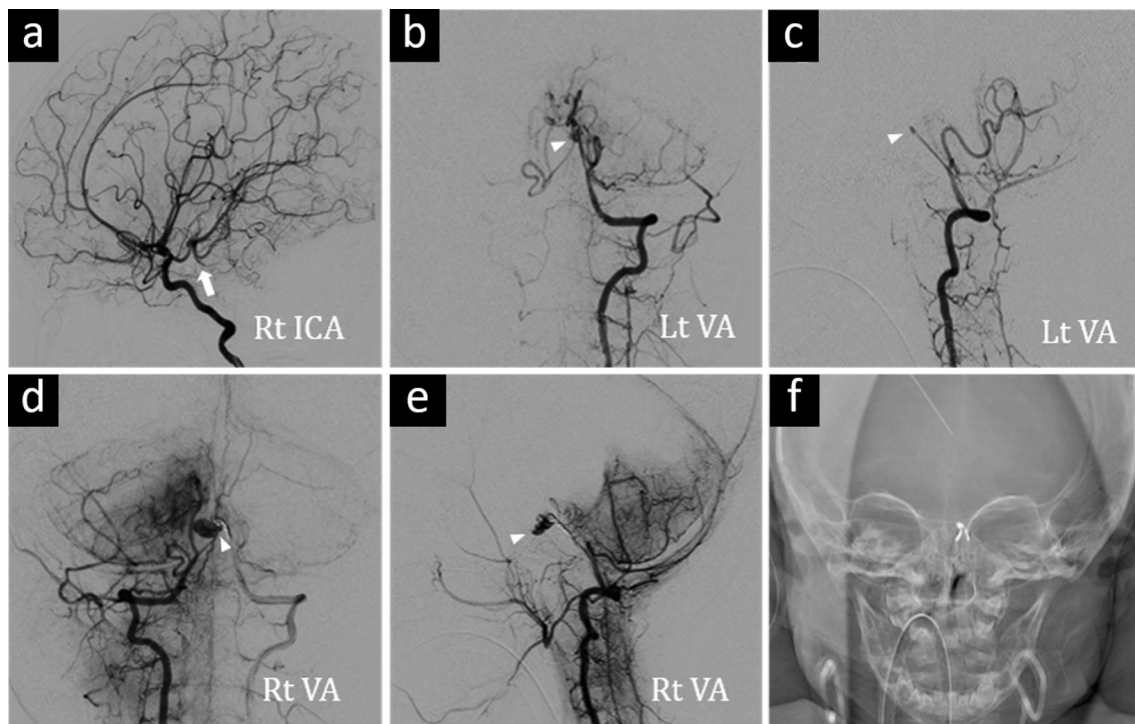
hydrocephalus with a newly developed lobulated fusiform aneurysm (8 mm in maximal diameter and 13 mm in length) at the proximal basilar artery, a suspected re-ruptured infectious aneurysm (shown in Fig. 1c–f). She underwent right frontal external ventriculostomy to relieve hydrocephalus, and after discussion about definite treatment with her parents, endovascular parent artery occlusion was decided.

A right transfemoral approach was used with a 5 French sheath (Terumo, Hanoi, Vietnam). The bilateral carotid angiography demonstrated collateral flow to the upper part of basilar artery via bilateral posterior communicating arteries (shown in Fig. 2a). A 5 French Guider Softip guiding catheter (Boston Scientific, Maple Grove, MN, USA) was advanced into the left vertebral artery with a 0.035-in. angled guidewire (Terumo, Hanoi, Vietnam) as a base catheter. Left vertebral angiography showed a partially thrombosed aneurysm at the proximal basilar artery without any antegrade flow to the basilar trunk above the aneurysm (shown in Fig. 2b, c). The proximal basilar artery was catheterized by using a Headway 17 Advanced microcatheter (Microvention/Terumo, Alajuela, Costa Rica) and a 0.014-in. Standard Pre-shaped Synchro2 guidewire (Salt Lake City, UT, USA). Partial coiling of the aneurysm and coiling of the left vertebrobasilar junction were then performed with Guglielmi detachable coils (GDCs) until total occlusion of the distal left vertebral artery. The right vertebral angiography via 5 Fr guiding catheter showed the residual aneurysm (shown in Fig. 2d–f), so coiling of the aneurysm at the right vertebrobasilar junction



**Fig. 1** a, b The contrast-enhanced CT of the brain shows mild communicating hydrocephalus without space-occupying lesion or gross aneurysm. c, d The non-contrasted CT of the brain reveals a diffuse SAH

with intraventricular hemorrhage and communicating hydrocephalus. e, f The CT angiography of the brain demonstrates a lobulated fusiform aneurysm at the proximal basilar artery



**Fig. 2** **a** The right carotid angiography reveals retrograde flow to the upper part of basilar artery (arrow) via right posterior communicating artery. **b, c** Left and **d, e** right vertebral angiography demonstrate the

aneurysm (arrowhead) at the proximal basilar artery without antegrade flow to the basilar trunk. **f** The frontal film of the skull after endovascular treatment depicts the coil meshes at the vertebrobasilar junction

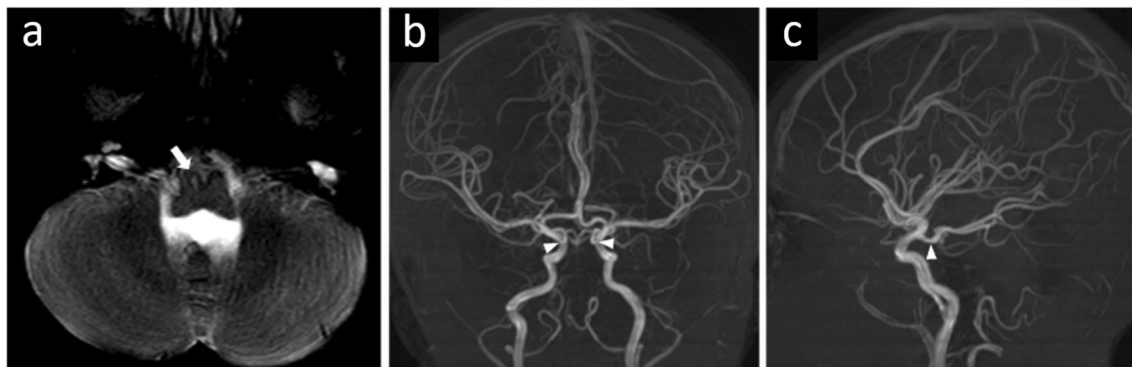
was performed in the same manner of the left side with GDCs. The control right vertebral angiography demonstrated no antegrade contrast filling of the aneurysm and total occlusion of the distal right vertebral artery.

After endovascular intervention with broad-spectrum antibiotic and supportive treatment, her clinical symptoms gradually improved, and the patient was discharged after a complete 4-week course of antibiotics. At 6-week follow-up, her motor, language, and social skills were appropriate for age. The magnetic resonance imaging and angiography (MRI and MRA) of the brain were performed at 10-month follow-up and revealed lacunar infarction at the right medial portion of the medulla

oblongata. Obliteration of the basilar aneurysm and occlusion of vertebrobasilar junction were noted. The upper part of basilar artery was supplied by collateral flow from bilateral posterior communicating arteries (shown in Fig. 3).

## Discussion

Intracranial infectious aneurysms in children under the age of 1 year are extremely rare, with only small numbers of infantile intracranial infectious aneurysms reported [1, 20, 21, 23, 24]. The low amount of reported cases may be underestimated as



**Fig. 3** **a** The axial T2-weighted MRI of the brain at 10-month follow-up shows lacunar infarction at the right medial portion of the medulla oblongata (arrow). **b, c** The time-of-flight MRA of the brain reveals the

collateral flow from bilateral posterior communicating arteries to upper part of the basilar artery (arrowhead)

most infectious aneurysms are asymptomatic with a low rupture rate and can be resolved after treatment with antibiotics. Nonetheless, our case presented with an intracranial infectious aneurysm, rarely found in this age group. Although one can argue that an aneurysm etiology in this case could be dissection because of its high incidence in the pediatric age group and vertebrobasilar location [15], the clinical history in conjunction with positive CSF culture in this patient makes the infectious cause more likely.

Most infectious aneurysms are secondary to an intravascular dissemination from infective endocarditis; however, other less common extravascular causes, including bacterial meningitis, cavernous sinus thrombophlebitis, cerebral abscess, and subdural empyema, can also lead to infectious aneurysms [2, 9, 14]. In cases of infective endocarditis, the aneurysms tend to be found at the distal branch of the intracranial artery where anterior circulation is more common. Alternatively, in extravascular invasion and meningitis, the aneurysms are usually involved at the more proximal part of the artery, which is closer to the base of the skull [10]. The infectious process from bacterial meningitis causes acute infiltration of neutrophils into the tunica media and adventitia, together with marked proliferation of the tunica intima and destruction of the internal elastic lamina. This pathologic vascular wall, along with the accompanying pulsatile arterial pressure, leads to an aneurysmal formation and consequential growth [9, 28]. The causative pathogens of an infectious aneurysm are usually bacterial, the most common organisms being *Streptococcus viridans* and *Staphylococcus aureus*. In addition, less commonly encountered pathogens, including *Salmonella*, *Pseudomonas aeruginosa*, *Aspergillus*, *Candida*, varicella zoster virus, and human immunodeficiency virus, have also been reported [9, 10]. In our patient, the infectious aneurysm rapidly developed at the proximal basilar artery during the process of *Pseudomonas* meningitis, which was uncommon in location, causative pathogen, and pathogenesis.

Management of intracranial infectious aneurysms depends on such factors as the presence or absence of hemorrhage, anatomical location, and clinical course [23]. Current treatment options for intracranial infectious aneurysms include medication, surgery, and endovascular treatment. Medical treatment specified with causative pathogens, e.g., antibiotic, antiviral, or antifungal agents, provides the benchmark for the treatment of all infectious aneurysms. The surgical techniques include clipping, trapping, and wrapping, the most common technique being surgical trapping with resection of the aneurysm, which may be followed by extracranial–intracranial bypass when the parent artery supplies an eloquent area of the brain [10]. Endovascular strategies include an indirect approach by parent artery occlusion using coils or liquid embolic agents, and a direct approach by embolization of the aneurysm using coils, stent-assisted coiling, flow diverters, or liquid embolic agents [29]. Parent artery occlusion is currently the most

common endovascular technique for treatment of infectious aneurysms [10]. This method induces aneurysm thrombosis in a high percentage of patients but does carry a risk of immediate or delayed ischemia due to hypoperfusion or thrombosis of perforating arteries [25]. Balloon test occlusion should be performed to assess the feasibility of therapeutic vessel occlusion and guide the treatment strategy, as previously reported [10, 12, 15]; however, balloon test occlusion was not done in our patient due to the fact of already occluded proximal basilar artery without antegrade flow. While the endovascular treatment of intracranial aneurysm is increasingly utilized in the pediatric population, there are some challenges. Pediatric intracranial aneurysms have more tendency to be nonsaccular configuration [15], requiring novel reconstructive or well-prepared deconstructive approach. In addition, very low body weight patients, especially neonates, limit the use of larger endovascular devices requiring for complex technique and contrast medium during the operation. Presently, there is no standard treatment for an intracranial infectious aneurysm; however, because of the high morbidity and mortality associated with ruptured aneurysms, active intervention (either surgery or endovascular treatment) is suggested in cases of hemorrhagic presentation or progressive aneurysmal growth (despite proper medication) [10].

Our patient experienced re-bleeding of the basilar infectious aneurysm, expediting our decision for prompt active management. Endovascular treatment with parent artery occlusion was decided because of her age and pathologic vessel location. Fortunately, favorable clinical status and angiographic findings were observed just before treatment. She had intact motor movement of extremities, while there was no antegrade flow to the basilar artery distal to the aneurysm, indicating good collaterals from anterior circulation to supply the brainstem. Therefore, parent artery occlusion at the vertebrobasilar junction could be performed in our patient with low risk of hypoperfusion of the brainstem. Asymptomatic lacunar infarction of the right medial portion of the medulla oblongata was observed, possibly a result of the coil meshes obstructing the perforating branch of the right vertebral artery, or a consequence of vasospasm from SAH.

Previous studies of pediatric basilar infectious aneurysms are limited (shown in Table 1). The most common presentation of pediatric basilar infectious aneurysms with a high mortality rate is SAH. Ischemic and compressive symptoms are usually related to basilar aneurysms in HIV patients. The basilar infectious aneurysms in this age group can relate to either intravascular or extravascular invasion. Pediatric basilar infectious aneurysms are mostly associated in the immunocompromised and those with atypical pathogens, such as *Candida albicans*, *Aspergillus*, and HIV (as described in Table 1). In hemorrhagic presentation, treatment by medication only usually ends in fatality. Only two cases by Ahmad et al. [1] and



**Table 1** Summary data of previously reported pediatric patients with infectious aneurysm of basilar artery

Year	Authors	Age/sex	Underlying/presentation	Pathogen	Location(s)	Treatment	Outcome
1979	Goldman JA et al. [13]	16 yr/F	SLE/DM/meningitis/SAH/IVH	<i>Candida albicans</i>	BA	NA	Death
1990	Barrow D et al. [6]	12 yr/M	Burkitt's lymphoma/meningitis	<i>Pseudomonas aeruginosa</i>	BA, ICA	Antibiotics/surgical clipping	Good
1990	Barrow D et al. [6]	4 yr/M	Brain tumor resection/graft infection/SAH/IVH	<i>Aspergillus</i> sp.	BA, left VA	Antibiotics	Death
1990	Barrow D et al. [6]	18 yr/NA	SLE/intracranial hemorrhage	<i>Candida albicans</i>	BA	Antibiotics	Death
1993	Aspoas AR et al. [5]	16 yr/F	Infective endocarditis/SAH	NA	BA, MCA	Antibiotics/surgical clipping	3rd nerve palsy due to persisted aneurysm
1998	Allison JW et al. [3]	9 yr/M	HIV infection/TIA	HIV	BA, left ICA	Medical treatment	NA
1998	Fulmer BB et al. [11]	6 yr/F	SAH, IVH	HIV, VZV	BA, both PCAs, SCAs, ICAs, ACAs, MCAs	NA	Death
2001	Nunes ML et al. [20]	1 mo/F	HIV infection/encephalitis/SAH	HIV, HSV	BA	Antiviral drugs	Death
2002	Messori A et al. [19]	3 yr/F	Near drowning/brain abscess/SAH/IVH	<i>Pseudallescheria boydii</i>	BA, right PCA	Antifungal drug	Death
2003	Petropoulou F et al. [22]	12 yr/M	HIV infection/asymptomatic	HIV	BA, right ICA	Antiviral drugs	Stable size at 2-yr F/U
2005	Lasjaunias P et al. [15]	6 yr/M	CMCC/SAH	<i>Candida albicans</i>	BA, both VAs, left PCA, left ICA	Antibiotics/antifungal drugs	Delayed SAH/death
2006	Laurencikas E et al. [16]	12 yr/M	Continuous steroid therapy/SAH/IVH	<i>Aspergillus</i> sp.	BA, left ICA, left ACA, left MCA	Antifungal drug	Death
2006	Ahmad FU et al. [1]	9 mo/M	Congenital IgA deficiency/SAH	NA	BA	Antibiotics	Reducing size at 6-mo F/U
2008	Marazzi MG et al. [18]	5 yr/M	CMCC/SAH	<i>Candida albicans</i>	BA, left ICA, left PcomA	NA	Death
2008	Mahadevan A et al. [17]	16 yr/M	Multiple lower cranial nerve palsies	HIV	BA, both VAs, right ICA, right MCA	NA	Death
2009	Daugherty WP et al. [8]	14 yr/F	CVID/decreased sensation right side of face, arm, hemithorax	VZV	BA, both ICAs, PCAs, left PcomA	Antiviral drug	Stable size at 6-mo F/U
2012	Saraf R et al. [25]	NA/NA	Meningitis/intracranial hemorrhage	NA	BA	Endovascular coiling with PAO	Survive
2014	Chimparlee N et al. [7]	16 yr/F	Infective endocarditis/SAH	<i>Streptococcus viridans</i>	BA	Antibiotics/endovascular coiling	Good
2017	Palacios A et al. [21]	5 mo/M	Meningitis/SAH	<i>Streptococcus pneumoniae</i>	BA	Antibiotics	Death
2018	Vyas S et al. [26]	12 yr/M	HIV infection/right hemiparesis	HIV	BA, both ICAs, ACAs, MCAs	Antiviral drugs	NA
2018	Garg M et al. [12]	12 yr/M	SAH	<i>Mycobacterium tuberculosis</i>	BA	Antitubercular drugs	Reducing size at 2-yr F/U
2019	Ares WJ et al. [4]	2 yr/M	Infective endocarditis/SAH	NA	BA	Antibiotics/flow diversion device	Good

yr years, mo months, M male, F female, NA not applicable, SLE systemic lupus erythematosus, DM diabetes mellitus, SAH subarachnoid hemorrhage, IVH intraventricular hemorrhage, TIA transient ischemic attack, CMCC chronic mucocutaneous candidiasis, CVID common variable immunodeficiency, HIV human immunodeficiency virus, VZV varicella zoster virus, HSV herpes simplex virus, BA basilar artery, ICA internal carotid artery, VA vertebral artery, ACA anterior cerebral artery, MCA middle cerebral artery, PCA posterior cerebral artery, SCA superior cerebellar artery, PcomA posterior communicating artery, PAO parent artery occlusion, F/U follow-up

Garg et al. [12] have reported a reduced size of previously ruptured basilar aneurysms after treatment with antibiotic and antitubercular drugs, respectively. Alternatively, endovascular treatments of ruptured basilar aneurysms have been associated with good outcomes. Three previous cases of ruptured basilar aneurysms that underwent endovascular treatment have been reported. Two cases had basilar tip aneurysms treated with a simple coiling technique [7] and flow diverter device [4]. The other case, a distal basilar artery aneurysm, underwent endovascular coiling with parent artery occlusion. In regard to surgical treatment, Aspoas et al. [5] reported one case of ruptured basilar aneurysm, which underwent surgical clipping but with a persistence of aneurysm and third cranial nerve palsy.

## Conclusion

This is the first reported case of successful parent artery occlusion of a ruptured basilar infectious aneurysm in an infant secondary to *Pseudomonas* meningitis. The management of an intracranial infectious aneurysm in an infant should be individualized depending on the clinical presentation, anatomical location, and the clinical course of the disease. Endovascular treatment is an effective method for the management of a ruptured pediatric intracranial infectious aneurysm.

## Compliance with ethical standards

**Conflict of interest** The authors have no conflicts of interest to declare.

## References

- Ahmad FU, Mahajan H, Mahapatra AK, Suri A (2006) Mycotic aneurysm. An unusual cause of pyrexia of unknown origin in an immunodeficient infant. *Pediatr Neurosurg* 42(4):237–239
- Alawieh A, Chaudry MI, Turner RD, Turk AS, Spiotta AM (2018) Infectious intracranial aneurysms: a systematic review of epidemiology, management, and outcomes. *J Neurointerv Surg* 10(7):708–716
- Allison JW, Davis PC, Sato Y, James CA, Haque SS, Angtuaco EJ et al (1998) Intracranial aneurysms in infants and children. *Pediatr Radiol* 28(4):223–229
- Ares WJ, Tonetti DA, Greene S, Sharma MS, Xavier F, Jankowitz BT, Jadhav A (2019) Pipeline embolization of an infectious basilar artery aneurysm in a 2-year-old child: case report, discussion of the literature and perioperative considerations. *Oper Neurosurg (Hagerstown)* 17(5):E224–E2e8
- Aspoas AR, de Villiers JC (1993) Bacterial intracranial aneurysms. *Br J Neurosurg* 7(4):367–376
- Barrow DL, Prats AR (1990) Infectious intracranial aneurysms: comparison of groups with and without endocarditis. *Neurosurgery* 27(4):562–572 discussion 72–3
- Chimparlee N, Jittapiromsak P, Tantivatana J, Chattranukulchai P (2014) Classical complication of infective endocarditis: ruptured, large mycotic cerebral aneurysm. *BMJ Case Rep* 2014: brc2013202275. <https://doi.org/10.1136/brc-2013-202275>
- Daugherty WP, Clarke MJ, Cloft HJ, Lanzino GL (2009) Going viral: fusiform vertebrobasilar and internal carotid aneurysms with varicella angitis and common variable immunodeficiency. *J Neurosurg Pediatr* 4(6):528–531
- Ducruet AF, Hickman ZL, Zacharia BE, Narula R, Grobelny BT, Gorski J et al (2009) Intracranial infectious aneurysms: a comprehensive review. *Neurosurg Rev* 33(1):37
- Flores BC, Patel AR, Braga BP, Weprin BE, Batjer HH (2016) Management of infectious intracranial aneurysms in the pediatric population. *Childs Nerv Syst* 32(7):1205–1217
- Fulmer BB, Dillard SC, Musulman EM, Palmer CA, Oakes J (1998) Two cases of cerebral aneurysms in HIV+ children. *Pediatr Neurosurg* 28(1):31–34
- Garg M, Shambanduram S, Singh PK, Sebastian LJD, Sawarkar DP, Kumar A, Gaikwad S, Chandra PS, Kale SS (2018) Management of pediatric posterior circulation aneurysms-12-year single-institution experience. *World Neurosurg* 116:e624–ee33
- Goldman JA, Fleischer AS, Leifer W, Parent A, Schwarzman SW, Raggio J (1979) Candida albicans mycotic aneurysm associated with systemic lupus erythematosus. *Neurosurgery*. 4(4):325–328
- Kannoth S, Iyer R, Thomas SV, Furtado SV, Rajesh BJ, Kesavadas C, Radhakrishnan VV, Sarma PS (2007) Intracranial infectious aneurysm: presentation, management and outcome. *J Neurol Sci* 256(1–2):3–9
- Lasjaunias P, Wuppapapati S, Alvarez H, Rodesch G, Ozanne A (2005) Intracranial aneurysms in children aged under 15 years: review of 59 consecutive children with 75 aneurysms. *Childs Nerv Syst* 21(6):437–450
- Laurencikas E, Sandstedt B, Söderman M (2006) Intrathecal aspergillosis and fusiform arterial aneurysms in an immunocompromised child: a clinico-pathological case report. *Childs Nerv Syst* 22(11):1497–1501
- Mahadevan A, Tagore R, Siddappa NB, Santosh V, Yasha TC, Ranga U, Chandramouli BA, Shankar SK (2008) Giant serpentine aneurysm of vertebrobasilar artery mimicking dolichoectasia-an unusual complication of pediatric AIDS. Report of a case with review of the literature. *Clin Neuropathol* 27(1):37–52
- Marazzi MG, Bondi E, Giannattasio A, Strozzi M, Savioli C (2008) Intracranial aneurysm associated with chronic mucocutaneous candidiasis. *Eur J Pediatr* 167(4):461–463
- Messori A, Lanza C, De Nicola M, Menichelli F, Capriotti T, Morabito L et al (2002) Mycotic aneurysms as lethal complication of brain pseudallescheriasis in a near-drowned child: a CT demonstration. *AJNR Am J Neuroradiol* 23(10):1697–1699
- Nunes ML, Pinho AP, Sfoggia A (2001) Cerebral aneurysmal dilatation in an infant with perinatally acquired HIV infection and HSV encephalitis. *Arq Neuropsiquiatr* 59(1):116–118
- Palacios A, Llorente AM, Ordóñez O, Martínez de Aragón A (2017) Intracranial mycotic aneurysm in a 5 month-old infant with pneumococcal meningitis. *Enferm Infecc Microbiol Clin* 35(4):267–269
- Petropoulou F, Mostrou G, Papaevangelou V, Theodoridou M (2003) Central nervous system aneurysms in childhood AIDS. *Aids*. 17(2):273–275
- Piastra M, Chiaretti A, Tortorolo L (2000) Ruptured intracranial mycotic aneurysm presenting as cerebral haemorrhage in an infant: case report and review of the literature. *Childs Nerv Syst* 16(3):190–193
- Ren Y, Zhao S, Liu L, Sun H, Liu Y, Li H, Ma L, He M, You C, Li J (2018) Successful microsurgical treatment of intracranial aneurysms in infants: a retrospective study and literature review. *Acta Neurochir* 160(4):783–792

25. Saraf R, Shrivastava M, Siddhartha W, Limaye U (2012) Intracranial pediatric aneurysms: endovascular treatment and its outcome. *J Neurosurg Pediatr* 10(3):230–240
26. Vyas S, Moudgil S, Kumar A, Goyal M (2018) HIV-associated diffuse intracranial aneurysmal arteriopathy. *J Pediatr* 203:461–4e1
27. Wang X, Chen G, Li M, Liang J, Guo H, Song G, Bao Y (2020) Rapid formation and rupture of an infectious basilar artery aneurysm from meningitis following suprasellar region meningioma removal: a case report. *BMC Neurol* 20(1):94
28. Yu W, Rickert K, Flores B, Samson D (2012) Infectious mid basilar artery aneurysm from *Pseudomonas* meningitis. *J Neurointerv Surg* 4(3):e10
29. Zanaty M, Chalouhi N, Starke RM, Tjoumakaris S, Gonzalez LF, Hasan D et al (2013) Endovascular treatment of cerebral mycotic aneurysm: a review of the literature and single center experience. *Biomed Res Int* 2013:151643

**Publisher's note** Springer Nature remains neutral with regard to jurisdictional claims in published maps and institutional affiliations.