



Ruptured pontine cavernomas in infants: a report of two cases

Ioan Alexandru Florian^{1,2} · Teodora Larisa Timis³ · Kinga Renata Kiss¹ · Ioan Stefan Florian^{1,2} · Ioana Berindan-Neagoe^{4,5}

Received: 3 July 2020 / Accepted: 22 September 2020
© Springer-Verlag GmbH Germany, part of Springer Nature 2020

Abstract

Background Cavernous malformations (CMs) are either congenital or acquired vascular lesions comprised of sinusoid spaces filled with either blood or its breakdown products. They possess a relatively reduced risk of hemorrhage, yet placement within the posterior fossa and especially the brainstem heightens their likelihood to rupture, making them a likely cause of permanent and debilitating neurological deficit, as well as a veritable surgical challenge. Although the incidence of rupture varies with age among reported case series, it is undoubtable that the severity of this occurrence is the highest while the brain is at its most vulnerable period, i.e. during infancy.

Case presentations We present two patients, both female, 6.5- and 5-months-old respectively, who presented with brainstem hemorrhage from CM. They suffered from a sudden onset of hemiparesis and were subjected to surgical removal of their lesions and resulting hematomas. Both patients were discharged in a favorable neurological status and are currently alive and in good health.

Conclusion Microsurgical treatment of brainstem CMs in infants is not only possible with minimal deficit, but also advisable if the lesions are symptomatic. Nevertheless, this requires substantial patience and experience to prevent significant loss of blood and injury to the structures of the posterior fossa. We argue that the safest method to prevent further damage from brainstem CM rebleed is to remove these lesions shortly after the initial hemorrhage.

Keywords Cavernous malformation (CM) · Infant · Hemorrhagic stroke · Surgical removal · Brainstem

Electronic supplementary material The online version of this article (<https://doi.org/10.1007/s00381-020-04898-8>) contains supplementary material, which is available to authorized users.

✉ Ioan Alexandru Florian
florian.ioan.alexandru@gmail.com

- ¹ Clinic of Neurosurgery, Cluj County Emergency Clinical Hospital, Cluj-Napoca, Romania
- ² Department of Neurosurgery, Iuliu Hatieganu University of Medicine and Pharmacy, Cluj-Napoca, Romania
- ³ Department of Physiology, Iuliu Hatieganu University of Medicine and Pharmacy, Cluj-Napoca, Romania
- ⁴ The Research Center for Functional Genomics, Biomedicine and Translational Medicine, Iuliu Hatieganu University of Medicine and Pharmacy, Cluj-Napoca, Romania
- ⁵ Functional Genomics and Experimental Pathology Department, The Oncology Institute “Prof. Dr. Ion Chiricuta”, Cluj-Napoca, Romania

Introduction

Intracranial cavernous malformations (CMs), otherwise known as cavernomas, represent congenital or occasionally acquired anomalies of the cerebral vasculature, being the second most common intracranial vascular malformation [1–4]. They are typically asymptomatic and discovered on routine imaging studies, although the most common presenting symptom is epileptic seizures. Hemorrhage from CMs can be small and restricted to the lesion itself, or it can surpass the boundaries of the malformation and, depending on the site, can actually become life-threatening. Because they are angiographically occult, there is no possibility to treat them endovascularly, whereas stereotactic radiosurgery remains a controversial form of treatment [5, 6]. As such, the best course of therapy that can entirely remove the risk of symptoms and stroke in the future is microsurgical removal.

Congenital CMs can be either sporadic or inherited with an autosomal dominant trait, the latter case usually involving a larger number of intracranial lesions [7]. Brainstem CMs have a more vaguely established natural course and surgical indication

than those of other locations [8]. Although they rarely rupture in infancy, the hemorrhage can lead to permanent neurological deficit, and in the case of brainstem CMs, it can even be fatal. There are few cases reported in the literature wherein surgical evacuation of the hematoma and the CM was performed before 1 year of age, especially of lesions located in the brainstem. In this case report, we present two infant girls who presented with hemiparesis subsequent to a pontine CM rupture. Both underwent surgical removal of the hematomas and CMs and were discharged in a favorable neurological status. The neurosurgical treatment poses a genuine challenge in this specific category because of the low amount of blood available in an infant body, the anesthesia-related difficulties, and last but not least, the risk of permanent and debilitating neurological deficit. The purpose of this paper is to offer our experience in the management of infant cavernomas of the brainstem, as well as to provide a concise review of the pertinent literature on this topic.

Case descriptions

Case 1

A 6.5-month-old girl was admitted with a sudden onset of right hemiparesis and internal strabismus of the left eye, the symptoms having commenced 3 days prior to presentation. Her father had been diagnosed with asymptomatic supratentorial cavernomatosis and at the time was under clinical observation. Upon neurological examination, the girl was somnolent, with a pGCS of 13 (M:6, V:4, O:3), with the palsy of the left abducens and left facial nerve, and moderate spasticity and reduction of movement on the right side.

The preoperative MRI scan revealed a hematoma of the pons surrounding a ventral pontine lesion (1.2-cm maximum diameter) that did not enhance with contrast and did not reach the pial layer (Fig. 1a–b), as well as multiple supratentorial lesions on the right temporal and bilateral parietal and occipital lobes with similar aspect to the pontine lesion. The benefits and risks of surgery were explained to the parents, as well as the chances of repeated hemorrhages and worsening neurological status if the intervention was delayed. Both parents consented for surgical removal. She underwent early surgery, being placed in the sitting position (the smallest child operated by the authors in this position) and with her head fastened in a horseshoe support. We performed a left retrosigmoidian craniotomy with a stellar incision of the dura mater. Via the peritrigeminal entry zone, the lesion was then completely removed, while the hematoma surrounding it was evacuated. We performed rigorous hemostasis with temporary application of small patties of SURGICEL® Original (Ethicon—Johnson & Johnson) and saline, closing with watertight suture of the dura and autologous pericranium, followed by the reinsertion of the bone flap.

The pathologic analysis confirmed that it was a cavernous malformation with vascular walls being entirely comprised of fibrotic tissue and no signs of neural tissue within the lesion. Her postoperative evolution was mildly favorable, with the slight amelioration of the right hemiparesis, yet with the persistence of the 6th and 7th nerve palsy. The scalp wound healed adequately, without signs of infection or dehiscence. The postoperative CT scan (special pediatric low radiation protocol) performed the day after surgery demonstrated the complete removal of the cavernoma and hematoma, with no signs of iatrogenic hemorrhage (Fig. 1c). She was discharged a month after surgery with no additional deficit.

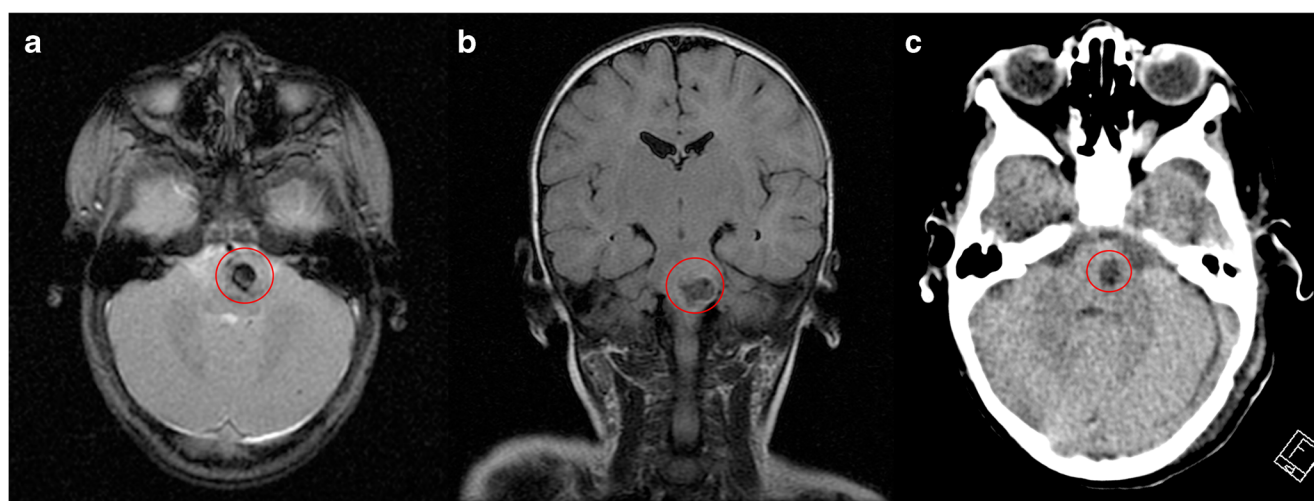
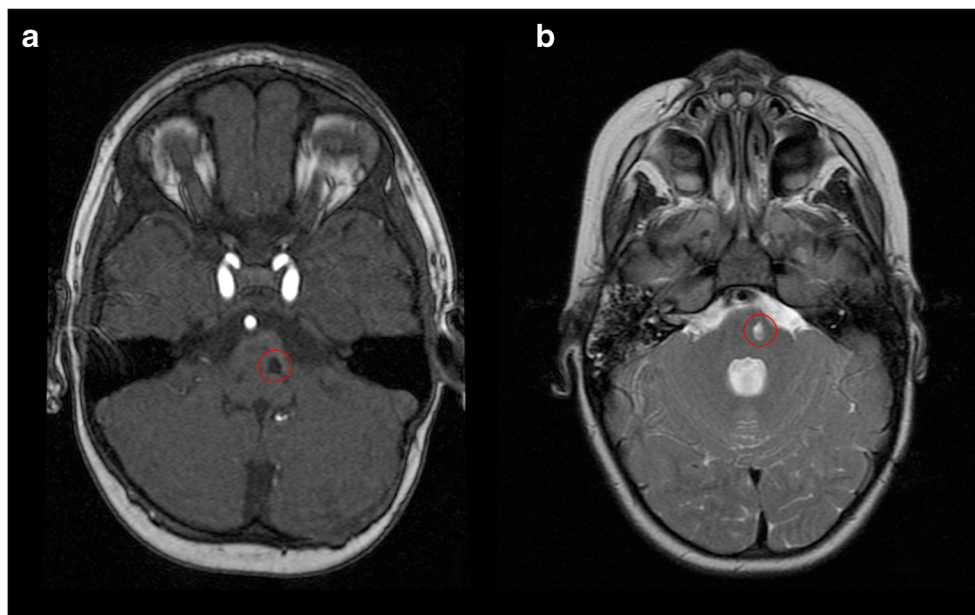


Fig. 1 Preoperative axial T2-weighted GRE (Gradient echo) (a) and coronal T2-weighted FLAIR (fluid-attenuated inversion recovery) (b) MRI scans of case 1, showing a hypointense pontine mass (red circle), denoting the ruptured cavernoma and surrounding edema. Postoperative

non-contrast axial CT scan of case 1 (c) (special pediatric low radiation protocol), revealing the resection cavity within the pons (red circle), with no signs of residual cavernoma or hemorrhage. Also noticeable is the bilateral internal strabismus

Fig. 2 Axial 3D TOF (time of flight) SPGR (spoiled gradient recalled echo) MRI at 2 years (**a**), and T2-weighted FRFSE (fast recovery fast spin echo) MRI at 4 years follow-up (**b**), revealing the residual pontine cavity (*red circle*) and no signs of cavernoma recurrence. The residual cavity displayed no significant changes in volume



Later controls, performed at 4 months, 1 year, 2 years (Fig. 2a), and 4 years after surgery (Fig. 2b), revealed no signs of marked evolution of the remaining lesions. At 3.6 years of age, she underwent an ophthalmological intervention with the intention of correcting the strabismus of her left eye. As the remaining cavernomas are asymptomatic and showed no signs of hemorrhage, we decided on maintaining them under observation. We obtained the informed consent of the parents to use the anonymized patient data in our studies.

Case 2

A 5-month-old girl was brought to our department with a sudden onset of a mild hemiparesis of the right side, alongside right facial palsy and deviation of both eyes toward her left-hand side, the symptoms having appeared 3 days prior to admission. The girl was born at 30 weeks of pregnancy and had a dizygotic twin sister.

The neurological examination revealed a somnolent infant, with a pGCS of 14 (M:6, V:4, O:4), a mild right hypertonia and hemiparesis and accentuated tendon reflexes on this side, axial hypotonia, right facial palsy, and left palpebral edema. Her eyes did not follow movement and she kept her head preferentially toward her left-hand side.

The preoperative contrast enhanced-CT demonstrated an acute hemorrhage at the level of the pons and superior medulla oblongata (2.1-cm maximum diameter), encompassing a lesion that did not enhance with the contrast and was not in contact with the pial layer, causing a significant mass effect on the 4th ventricle (Fig. 3 a–b). Both parents consented to surgery after understanding the implications of early surgery and that a repeated hemorrhage may result in death.

She underwent early surgery, placed in the park-bench position. We performed a right retrosigmoidian craniotomy (Video 1). We then opened the cisterna magna, approaching via the peritrigeminal entry zone. The lesion was entirely removed, and the hematoma surrounding it was evacuated. Rigorous hemostasis was then performed, with temporary application of small patties of SURGICEL® Original (Ethicon—Johnson & Johnson) and saline, avoiding the use of the bipolar coagulator, followed by the watertight suture of the dura and autologous pericranium, and then by the reinsertion of the bone flap.

The pathologic analysis revealed that it was indeed a ruptured cavernous malformation that was surrounded by a reactive fusocellular astrocytosis. After surgery, her evolution was favorable, with the noticeable amelioration of the hemiparesis and facial palsy, despite the persistence of the palsy of the abducens on the right side. The postoperative CT scan (special pediatric low radiation protocol) made on the day after surgery showed the complete removal of the brainstem lesion and adjacent hematoma, with no signs of subsequent hemorrhage (Fig. 3c). The scalp incision healed without complications. She was discharged on the 8th day after surgery with the added recommendation of performing brain MRI scans of the parents and sibling, in order to determine the presence of possible silent cavernomas.

The control performed at 1 year after surgery demonstrated a slight delay of neurological development in respect to her age, the persistence of a slight hemiparesis on the right side, as well as a slight internal strabismus on the same side. The control MRI at both 1 year (Fig. 4a) and 2 years follow-up (Fig. 4b) showed a small hyperintense cavity in the pons in the T2 sequence, validating the complete removal of the cavernoma. The angio-MRI scan of her sibling did not reveal

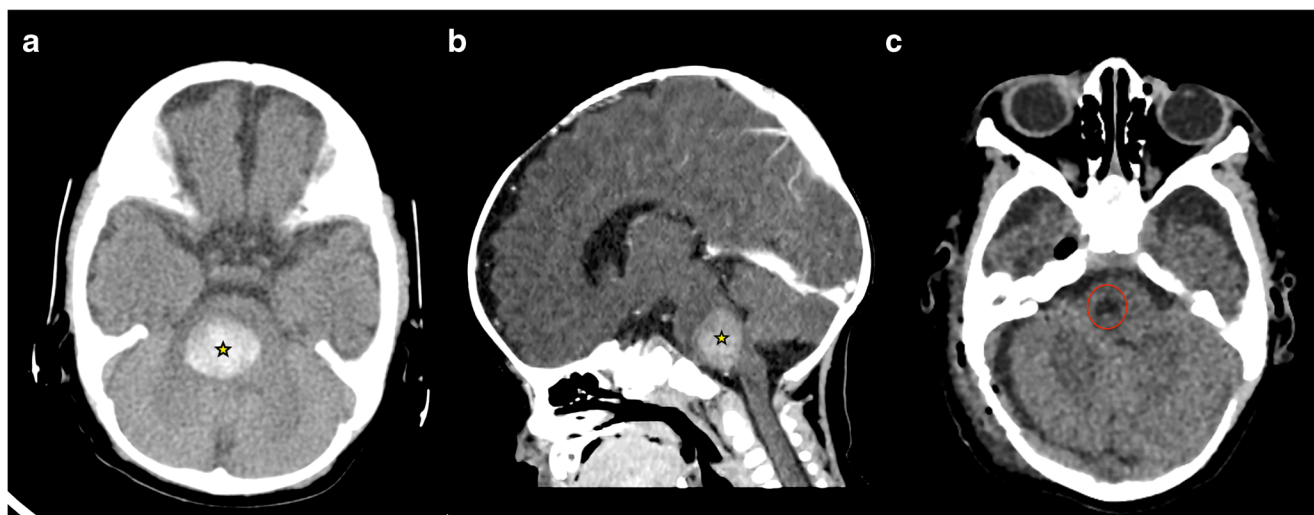


Fig. 3 Non-contrasted preoperative CT scan (special pediatric low radiation protocol); (a) axial section; (b) sagittal reconstruction) of case 2, showing a spontaneously hyperdense mass within the pons (yellow star), signaling a significant acute hemorrhage and significant mass effect on the 4th ventricle. Non-contrasted postoperative CT scan (special

pediatric low radiation protocol), axial section (c), revealing the residual pontine cavity (red circle) after the complete removal of the cavernoma and hematoma, with no signs of recurrent hemorrhage or cavernoma residue. A reduced amount of pneumocephalus in the right middle fossa can also be seen

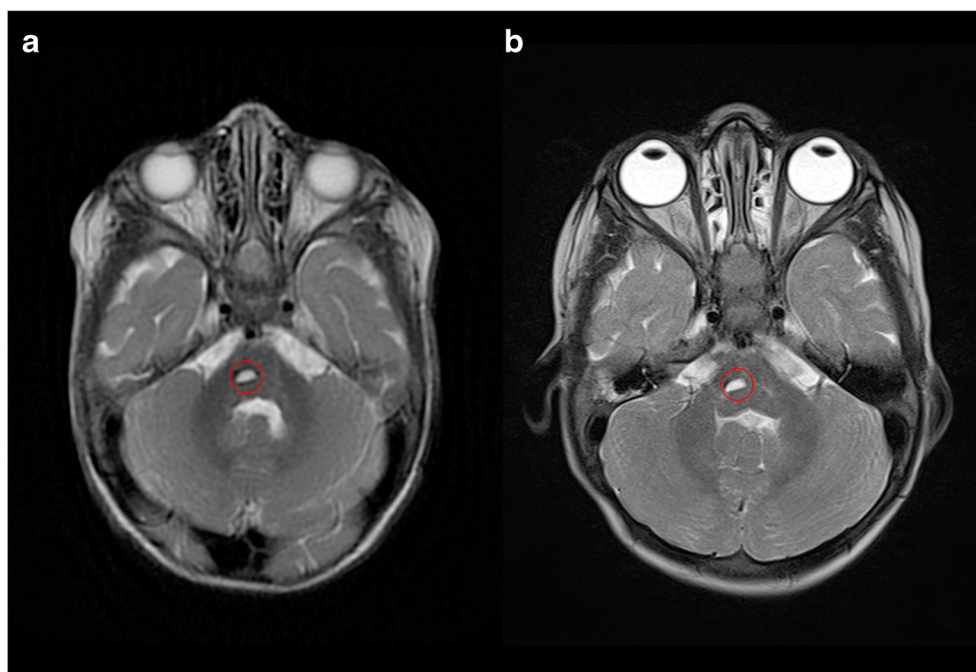
any cerebral vascular malformations. The parents gave their informed consent for us to utilize the anonymized patient data in our future research.

Discussion

Owing to the recent developments in surgery of brainstem CMs, lesions can be safely resected in their entirety with a considerably low mortality, and the majority of deficits

acquired after an intervention heal spontaneously [8–10]. The retrosigmoidian craniotomy offers wide and direct access to the pons, while the peritrigeminal area allows for a safe entry zone inside its structure, with minimal risk of injury [11–13]. The peritrigeminal region is bordered on the medial side by the pyramidal tract, the inferior margin is delineated by the pontomedullary sulcus out to the flocculus, and its lateral edge is just medial to the root entry point of the fifth cranial nerve. It is also worth mentioning that brainstem cavernomas displace rather than invade neural tissue and are therefore

Fig. 4 Axial T2 MRI at 1 year (a) and 2 years follow-up (b), showing the unchanged residual cavity within the pons (red circle), with no signs of cavernoma recurrence



easier to completely remove than other neoplastic lesions with the same location [8]. As stated in a recent meta-analysis that included 68 surgical studies and a total of 1390 patients, it appeared that patients with ventral pons cavernomas had a better evolution than those with lesions of the dorsal pons, possibly due to the less harmful entry zones involved and the lower morbidity of the approach [5]. In this regard, piecemeal removal is more adequate for complete ablation, since this implies less traction of the brainstem. To more effectively avoid the risk of neurological deficits, routine monitoring of somatosensitive evoked potentials and motor evoked responses is recommended [8, 14]. We operated our infant patients without the use of intraoperative neuromonitoring as this would not have been possible under the profound anesthesia required to minimize blood loss.

To the best of our knowledge, our cases are among the four youngest such patients subjected to surgery and reported in the literature. Bhardwaj et al. described seven children operated for brainstem cavernomas; out of which, one had a medulla CM diagnosed at 4 months of age, and the other harbored a pontine CM at the age of 2 months [15]. However, they do not specify the interval between imaging findings and neurosurgical intervention. In the case series by Abila et al, a single infant patient of 10 months of age was diagnosed and later operated for a pontine CM [16]. Braga et al presented two children of 18 and 9 months, respectively, at the time of surgery [7].

Familial CMs are generally associated with mutations in any of the three genes *KRIT1/CCM1*, *MGC4607/CCM2*, or *PDCD10/CCM3* [17–19]. These present an autosomal dominant inheritance pattern, and certain studies show a higher propensity for familial CMs within certain ethnic groups (50% of Hispanic patients compared with only 10–20% of Caucasian patients). However, the number might actually be higher if a thorough family history and MRI screening are obtained [7]. At least two family members must be diagnosed with CMs of the brain for the familial form. The only difference between the familial and sporadic forms is the number of cavernomas identified on imaging studies, typically multiple in the former and usually solitary in the latter. Apart from this, the lesions in both forms are identical from both a clinical and a pathological perspective [18]. Such was the case for our first infant patient with a brainstem CM, as both she and her father harbored multiple supratentorial lesions. As of writing this manuscript, the patient is due to perform a genetic test to identify the causal mutation.

According to studies on the natural history of CMs in pediatric patients, the brainstem location is associated with a higher risk of hemorrhage, as well as a more aggressive clinical course [5, 20, 21]. Furthermore, a prior hemorrhagic event and a solitary lesion increase the likelihood of rupture, with rebleeding rates higher within the brainstem than for any other site. Also, as stated by Gross et al., there is a possibility of

hemorrhage clustering in the first 3 years after the initial event [5]. This evidence further underlines the importance of early interventions within the pediatric age group for ruptured CMs of the brainstem.

An argument supporting surgical intervention at such an early age is the longer life expectancy of children, as well as the resultant higher risk of rebleeding [7, 22]. Despite the fact that some authors have reported a slightly worse surgical outcome at discharge for children with brainstem CMs when compared with adults, the differences became insignificant during follow-up [16, 23]. This temporarily poorer outcome in the youngest patients may be explained by the greater volume and mass effect of the lesion, as well as the disruption of a proportionally larger amount of the brainstem via surgery. Another major peculiarity of brainstem surgery at this age stems from the lower amount of blood in the infant body, as well as the much smaller workspace and shorter distances between critical neurovascular structures. These features make experience, steady hands, and a profound knowledge of the neuroanatomy crucial for the neurosurgeon. Careful dissection of the arachnoid using sharp instruments, the moderate use of retractors, and abstaining from employing the bipolar coagulator in this region are all required. Moreover, there is growing concern regarding the administration of anesthetics in infants and its effects on the developing brain [24]. It has been shown that general anesthesia at this age may be correlated with a decreased white matter volume and integrity on MRI studies, as well as possible disturbances in higher cognitive functions. Nevertheless, we believe that these risks are acceptable considering the severity of ruptured brainstem CMs.

However, there are some in favor of conservative treatment for ruptured brainstem CMs if certain conditions are met. In case there is no severe deterioration after a single bleed and if the lesion is deep seated and small, a noninvasive alternative may be advised [11]. Additionally, if the neurological deficit is not life-threatening or progressive, or if the residual symptoms after an initial stroke are minimal, it may be argued that waiting for a second hemorrhage is prudent [17]. Complete recovery can also occur in pediatric patients after conservative treatment, improvement ensuing usually a few days after the initial bleed [14]. Although these suggestions generally apply to older children and adults, whereas in infants, we maintain that waiting for a second hemorrhage would be detrimental to their neurological development, and potentially catastrophic.

A useful adjuvant for preoperative planning and postoperative control of brainstem CM surgery could be represented by diffusion tensor imaging (DTI) [25, 26, 27]. This method does nonetheless have its limitations. On the one hand, due to the low volume of the brainstem itself, it can be difficult to obtain accurate fiber tracts. On the other hand, the desire to preserve tract integrity during surgery might impede resection. Moreover, since the central nervous system of infants is still

developing, we are unsure whether preoperative DTI would be useful in this patient category.

Given the acute and brutal onset of the hemiparesis in both of our patients, as well as their tender age, we argue that a delayed emergency surgical resection of their causal pontine CMs was warranted. After allowing the hematomas to begin degrading and softening, we alleviated the surgical effort of evacuating the clots and resecting the lesions, which were clearly delineated from the adjacent eloquent structures. By using the peritrigeminal entry zone, we minimized the postoperative neurological damage and ensured an acceptable recovery. Had we waited for a second hemorrhage, we might have risked irrecoverable deficit or even death of either patient. Notwithstanding the urgency of these interventions, it is mandatory for the surgeons and anesthesiologists concerned to have sufficient skill and experience before attempting to resect brainstem CMs in infants.

Conclusions

Microsurgical treatment of brainstem CMs in infants is not only possible with minimal deficit but also advisable if the lesions are symptomatic. Nevertheless, these interventions require a tremendous amount of patience and experience in order to avoid significant loss of blood and injury to the sensitive structures of the posterior fossa. As the CMs in the brainstem have a higher tendency to rupture than those of the supratentorial compartment, the safest method to prevent further damage from rebleed is to remove them shortly after the initial hemorrhage. An additional argument for surgical interventions in infants is that their CNS is not yet fully developed; therefore, they benefit from an even better chance at postoperative recovery.

Compliance with ethical standards

Conflict of interest There is no conflict of interest to disclose.

Informed consent Considering that the patients were underage, informed consent was obtained from the parents of all individual participants included in this study.

References

- Gross BA, Du R (2015) Cerebral cavernous malformations: natural history and clinical management. *Expert Rev Neurother* 15(7):771–777
- Gross BA, Du R, Orbach DB, Scott RM, Smith ER (2016) The natural history of cerebral cavernous malformations in children. *J Neurosurg Pediatr* 17(2):123–128
- Horne MA, Flemming KD, Su IC, Stapf C, Jeon JP, Li D et al (2016) Clinical course of untreated cerebral cavernous malformations: a meta-analysis of individual patient data. *Lancet Neurol* 15(2):166–173
- Xie MG, Li D, Guo FZ, Zhang LW, Zhang JT, Wu Z et al (2018) Brainstem cavernous malformations: surgical indications based on natural history and surgical outcomes. *World Neurosurg* 110:55–63
- Gross BA, Batjer HH, Awad IA, Bendok BR, Du R (2013) Brainstem cavernous malformations: 1390 surgical cases from the literature. *World Neurosurg* 80(1–2):89–93
- Maurer AJ, Bonney PA, Strickland AE, Safavi-Abbasi S, Sughrue ME (2015) Brainstem cavernous malformations resected via miniature craniotomies: technique and approach selection. *J Clin Neurosci* 22(5):865–871
- Braga BP, Costa LB Jr, Lemos S, Vilela MD (2006) Cavernous malformations of the brainstem in infants. Report of two cases and review of the literature. *J Neurosurg* 104(6 Suppl):429–433
- Abla AA, Lekovic GP, Turner JD, de Oliveira JG, Porter R, Spetzler RF (2011) Advances in the treatment and outcome of brainstem cavernous malformation surgery: a single-center case series of 300 surgically treated patients. *Neurosurgery*. 68(2):403–415
- Frischer JM, Gatterbauer B, Holzer S, Stavrou I, Gruber A, Novak K et al (2014) Microsurgery and radiosurgery for brainstem cavernomas: effective and complementary treatment options. *World Neurosurg* 81(3–4):520–528
- Zhang S, Li H, Liu W, Hui X, You C (2016) Surgical treatment of hemorrhagic brainstem cavernous malformations. *Neurol India* 64(6):1210–1219
- Hauck EF, Barnett SL, White JA, Samson D (2010) The presigmoid approach to anterolateral pontine cavernomas. *Clinical article. J Neurosurg* 113(4):701–708
- Mai JC, Ramanathan D, Kim LJ, Sekhar LN (2013) Surgical resection of cavernous malformations of the brainstem: evolution of a minimally invasive technique. *World Neurosurg* 79(5–6):691–703
- Recalde RJ, Figueiredo EG, de Oliveira E (2008) Microsurgical anatomy of the safe entry zones on the anterolateral brainstem related to surgical approaches to cavernous malformations. *Neurosurgery*. 62(3 Suppl 1):9–17
- Amato MC, Madureira JF, Oliveira RS (2013) Intracranial cavernous malformation in children: a single-centered experience with 30 consecutive cases. *Arq Neuropsiquiatr* 71(4):220–228
- Bhardwaj RD, Auguste KI, Kulkarni AV, Dirks PB, Drake JM, Rutka JT (2009) Management of pediatric brainstem cavernous malformations: experience over 20 years at the hospital for sick children. *J Neurosurg Pediatr* 4(5):458–464
- Abla AA, Lekovic GP, Garrett M, Wilson DA, Nakaji P, Bristol R et al (2010) Cavernous malformations of the brainstem presenting in childhood: surgical experience in 40 patients. *Neurosurgery*. 67(6):1589–1599
- Noushad M, Bhattacharjee S, Weatherby SJ, Whitefield P. A British family with familial cerebral cavernous malformation due to a rare mutation of the CCM2 gene [published online ahead of print, 2020 Mar 13]. *Acta Neurol Belg*. 2020; 10.1007/s13760-020-01329-y
- Ramírez-Zamora A, Biller J (2009) Brainstem cavernous malformations: a review with two case reports. *Arq Neuropsiquiatr* 67(3B):917–921
- Rosário Marques I, Antunes F, Ferreira N, Grunho M (2017) Familial cerebral cavernous malformation: report of a novel KRIT1 mutation in a Portuguese family. *Seizure*. 53:72–74
- Block RI, Magnotta VA, Bayman EO, Choi JY, Thomas JJ, Kimble KK (2017) Are Anesthesia and Surgery during Infancy Associated with Decreased White Matter Integrity and Volume during Childhood? *Anesthesiology*. 127(5):788–799
- Di Rocco C, Iannelli A, Tamburrini G (1997) Cavernous angiomas of the brain stem in children. *Pediatr Neurosurg* 27(2):92–99

22. Porter RW, Detwiler PW, Spetzler RF et al (1999) Cavernous malformations of the brainstem: experience with 100 patients. *J Neurosurg* 90:50–58
23. Boulouis G, Blauwblomme T, Hak JF, Benichi S, Kirton A, Meyer P et al (2019) Nontraumatic pediatric intracerebral hemorrhage. *Stroke*. 50(12):3654–3661
24. Faraji AH, Abhinav K, Jarbo K, Yeh FC, Shin SS, Pathak S, Hirsch BE, Schneider W, Fernandez-Miranda JC, Friedlander RM (2015) Longitudinal evaluation of corticospinal tract in patients with resected brainstem cavernous malformations using high-definition fiber tractography and diffusion connectometry analysis: preliminary experience. *J Neurosurg* 123(5):1133–1144
25. Li D, Hao SY, Tang J, Xiao XR, Jia GJ, Wu Z et al (2014) Clinical course of untreated pediatric brainstem cavernous malformations: hemorrhage risk and functional recovery. *J Neurosurg Pediatr* 13(5):471–483
26. Li D, Jiao YM, Wang L, Lin FX, Wu J, Tong XZ et al (2018) Surgical outcome of motor deficits and neurological status in brainstem cavernous malformations based on preoperative diffusion tensor imaging: a prospective randomized clinical trial. *J Neurosurg* 130(1):286–301
27. Ulrich NH, Kockro RA, Bellut D, Amaxopoulou C, Bozinov O, Burkhardt JK et al (2014) Brainstem cavernoma surgery with the support of pre- and postoperative diffusion tensor imaging: initial experiences and clinical course of 23 patients. *Neurosurg Rev* 37(3):481–492

Publisher's note Springer Nature remains neutral with regard to jurisdictional claims in published maps and institutional affiliations.