

Case report

Olfactory gyrus intracerebral hemorrhage in a patient with COVID-19 infection

Sai Si Thu^{a,c}, Nassim Matin^{a,c}, Steven R. Levine^{a,b,c,*}^a Departments of Neurology, SUNY Downstate Health Sciences University, Brooklyn, NY, United States^b Emergency Medicine, SUNY Downstate Health Sciences University, Brooklyn, NY, United States^c Department of Neurology, Kings County Hospital Center, Brooklyn, NY, United States

ARTICLE INFO

Article history:

Received 11 June 2020

Accepted 13 July 2020

Keywords:

Intracerebral hemorrhage

COVID-19

Olfactory gyrus

SARS-CoV-2 infection

ABSTRACT

Since the outbreak with novel corona virus in December 2019, a myriad of different neurological manifestations in patients with COVID-19 infection have been reported. We present a case of non-traumatic intracranial hemorrhage in the olfactory gyrus in a patient who tested positive for SARS-CoV-2. The area of hemorrhage is not a common location for spontaneous hemorrhage. Given that loss of smell is considered a relatively common symptom of this pandemic, it is an intriguing association of COVID-19 and olfactory gyrus ICH for neurotropism of SARS-CoV2 for olfactory bulb and glia cells through nasal mucosa. Future studies will need to elucidate the exact mechanism of anosmia from COVID-19 and potential mechanisms leading to ICH.

© 2020 Elsevier Ltd. All rights reserved.

1. Introduction

During the current coronavirus pandemic, there have been a myriad of neurological manifestations including anosmia, dysgeusia, encephalopathy, hemorrhagic encephalitis, cerebral ischemic events, meningitis/encephalitis, headache, and Guillain Barre Syndrome [1,2]. We report a case with COVID-19 infection presenting with focal status epilepticus from a unilateral olfactory gyrus intracerebral hemorrhage (ICH).

2. Case report

A 72 year old man without prior medical history presented with 6 seizures, each lasting less than one minute, back to back, several minutes apart; seizures were arrested with intravenous diazepam. Initial EMS examination revealed a left gaze deviation and a witnessed generalized convulsion. In the ED, he was loaded with levetiracetam. He did not recall what had happened to him. He had left-sided weakness which slowly improved. He did not take any prescription nor over the counter medications. He denied any drug use but drank almost one liter of vodka every other day. His last drink was 2 days prior to admission.

Neurological exam showed a post-ictal state, drowsy, but he was following commands consistently, inattentive, without right-left confusion, intact cranial nerves with mild left-sided hemiparesis. There was no sign of head trauma. He had persistent loss of smell and appetite during the hospitalization.

Laboratory studies showed mild leukocytosis with transiently elevated bands. SARS-CoV2-RNA was positive in a nasopharyngeal swab. C-Reactive Protein was elevated to 164 mg/L (0–8 mg/L) and procalcitonin was 0.22 ng/ml (0.00–0.10 ng/ml). A comprehensive metabolic panel, coagulation studies, lactate dehydrogenase, lipid panel, hemoglobin A1c, blood alcohol level, urinalysis, blood culture and chest x-ray were normal.

Head CT (Fig. 1) showed an ICH along right olfactory gyrus with surrounding edema, without evidence of soft tissue injury nor cerebral contusion. CT angiogram of head and neck were normal. Serial non-contrast head CTs showed stability of the ICH. EEG showed frequent sharp waves and multiple electrographic seizures over the right frontal and anterior temporal regions. Oxcarbazepine was added to the levetiracetam. His mental status normalized and his left hemiparesis improved. A brain MRI with and without gadolinium demonstrated a right olfactory gyrus ICH with surrounding edema (Fig. 1).

3. Discussion

Our patient presented with focal onset status epilepticus with a Todd's paralysis and was found to have a right olfactory gyrus ICH

* Corresponding author at: Department of Neurology, MSC 1213, SUNY Downstate Health Sciences University, 450 Clarkson Avenue, Brooklyn, NY, United States.

E-mail addresses: saisi.thu@downstate.edu (S.S. Thu), steven.levine@downstate.edu (S.R. Levine).

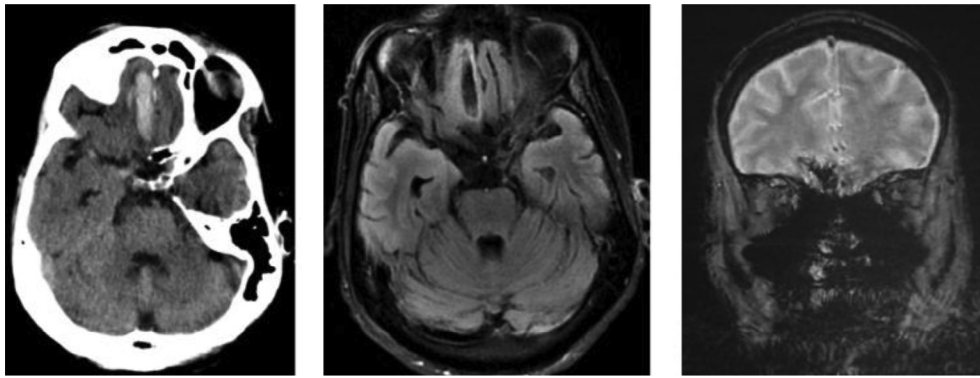


Fig. 1. CT head, MRI brain T1 and GRE sequences showing hemorrhage in right frontal base with adjacent edema.

associated with COVID-19 infection. There was no evidence of head trauma and the patient denied any fall. The alternate day heavy alcohol consumption history could increase the risk of ICH [3] however his blood alcohol level was normal. He was not on any antiplatelet nor anticoagulant therapy. The location was atypical for a spontaneous parenchymal or traumatic ICH. CT angiography did not detect a vascular malformation or aneurysm. Brain MRI showed no other contrast enhancing lesion nor ischemic stroke.

It is an intriguing association of covid-19 and olfactory gyrus ICH, given that loss of smell is considered a relatively common symptom of this pandemic [1]. There are various hypotheses regarding the mechanism of action of coronavirus affecting the nervous system. The angiotensin-converting enzyme-2 (ACE-2) receptor, a port of entry of SARS-CoV2, is present in lung parenchyma, nasal mucosa, renal and urinary tract, gastrointestinal tract as well as both glial cells and neurons in the brain. Further, the ACE-2 receptor is present in arterial and venous endothelial cells and arterial smooth muscle cells in all organs studied [4].

Altered mental status in addition to anosmia and ageusia, and detection of virus in cerebrospinal fluid, is consistent with neurotropic and neuroinvasive nature of the virus. Animal studies with previous coronaviruses (e.g. SARS-CoV, MERS-CoV) indicated that infiltration of the virus starts from the olfactory nerves [5]. Thus, hyposmia and anosmia, in a patient with minimal respiratory symptom, may indicate invasion of virus to olfactory gyrus and brain tissue via olfactory bulb. Through the olfactory nerve, the virus follows its way to pyriform cortex and brainstem as shown in animal models [5]. Once cerebral vascular endothelium is affected by the virus through ACE-2, function of the microvasculature could be altered, possibly leading to hemorrhage. Coagulopathy and endotheliopathy [6] associated with SARS-CoV2 is another factor potentially contributing to both ischemic and hemorrhagic strokes [7].

Our case is consistent with neurotropism of SARS-CoV2 for olfactory bulb and glia cells through nasal mucosa, as the animal studies suggest [5]. Olfactory disorders and hemorrhage in this area, are generally caused by trauma [8] or anterior communicating artery aneurysm rupture [9]. Different locations of ICH cases

in COVID-19 infected patients have been reported but it was unclear whether it is causative or incidental findings [10]. Future studies will need to elucidate the exact mechanism of anosmia from COVID-19 and potential mechanisms leading to ICH.

Funding

The authors received no financial support for the research, authorship, and/or publication of this article.

Declaration of Competing Interest

The authors declare that they have no known competing financial interests or personal relationships that could have appeared to influence the work reported in this paper.

References

- [1] Mao L et al. Neurologic manifestations of hospitalized patients with coronavirus disease 2019 in Wuhan, China. *JAMA Neurol* 2020.
- [2] Sedaghat Z, Karimi N. Guillain Barre syndrome associated with COVID-19 infection: a case report. *J Clin Neurosci* 2020.
- [3] Reynolds K et al. Alcohol consumption and risk of stroke: a meta-analysis. *JAMA* 2003;289(5):579–88.
- [4] Hamming I et al. Tissue distribution of ACE2 protein, the functional receptor for SARS coronavirus. A first step in understanding SARS pathogenesis. *J Pathol* 2004;203(2):631–7.
- [5] Netland J et al. Severe acute respiratory syndrome coronavirus infection causes neuronal death in the absence of encephalitis in mice transgenic for human ACE2. *J Virol* 2008;82(15):7264–75.
- [6] Varga Z et al. Endothelial cell infection and endotheliitis in COVID-19. *Lancet* 2020;395(10234):1417–8.
- [7] Zhang Y et al. Coagulopathy and antiphospholipid antibodies in patients with Covid-19. *N Engl J Med* 2020;382(17):e38.
- [8] Schofield PW, Moore TM, Gardner A. Traumatic brain injury and olfaction: a systematic review. *Front Neurol* 2014;5:5.
- [9] Martin GE et al. Olfactory dysfunction after subarachnoid hemorrhage caused by ruptured aneurysms of the anterior communicating artery. *J Neurosurg* 2009;111(5):958–62.
- [10] Sharifi-Razavi A, Karimi N, Rouhani N. COVID-19 and intracerebral haemorrhage: causative or coincidental?. *New Microbes New Infect* 2020;35:100669.