

Internal carotid artery rupture successfully rescued after resection of locally advanced mucosal malignant melanoma of the eustachian tube: a case report

Journal of International Medical Research

48(10) 1–6

© The Author(s) 2020

Article reuse guidelines:

sagepub.com/journals-permissions

DOI: 10.1177/0300060520963005

journals.sagepub.com/home/imrJianfeng Li , Xiaohong Chen and Jing Zhou

Abstract

Mucosal melanoma of the eustachian tube is a rare and highly malignant tumour. Local radical resection combined with radiotherapy and systemic chemotherapy is a classic treatment strategy for this tumour. The internal carotid artery (ICA) is easily damaged when this tumour is removed. Once the ICA ruptures and causes haemorrhage, it can be fatal. We report a case of mucosal malignant melanoma of the eustachian tube with ICA rupture and haemorrhage in a 62-year-old woman 3 days after resection of the tumour. After successful emergency endotracheal intubation, anti-shock treatment was performed. Further, the ICA was examined using digital subtraction angiography under general anaesthesia and the bleeding site was embolized. The patient recovered uneventfully after surgery and was discharged from hospital without hemiplegia, aphasia, or other intracranial complications. Because of economic reasons, the patient discontinued comprehensive treatment after being discharged from the hospital. Finally, she developed bone and kidney metastases 8 months after surgery and died of distant metastases 1.5 years later. When removing eustachian tube lesions, the ICA must be particularly protected. Once the ICA ruptures and there is postoperative haemorrhage, prevention of airway asphyxia, timely anti-shock treatment, and emergency digital subtraction angiography and vascular embolization are effective treatment methods.

Department of Otolaryngology, Head and Neck Surgery, Beijing Tongren Hospital, Capital Medical University, Beijing, People's Republic of China

Corresponding author:

Xiaohong Chen, Department of Otolaryngology, Beijing Tongren Hospital, Capital Medical University, No. 1 Dongjiaominxiang Street, Dongcheng District, Beijing 100730, People's Republic of China.
Email: trchxh@163.com



Creative Commons Non Commercial CC BY-NC: This article is distributed under the terms of the Creative Commons Attribution-NonCommercial 4.0 License (<https://creativecommons.org/licenses/by-nc/4.0/>) which permits non-commercial use, reproduction and distribution of the work without further permission provided the original work is attributed as specified on the SAGE and Open Access pages (<https://us.sagepub.com/en-us/nam/open-access-at-sage>).

Keywords

Eustachian tube, malignant melanoma, internal carotid artery, haemorrhage, embolization, digital subtraction angiography

Date received: 29 January 2020; accepted: 23 July 2020

Introduction

Melanoma is a high-grade malignant tumour that can be divided into cutaneous, mucosal, and chorioretinal types. Mucosal melanoma is more common in the head and neck, accounting for 22.6% of all cases of mucosal melanoma in the body.^{1,2} The lesion site includes mucosal tissues of the head and neck, and malignant melanoma from the eustachian tube mucosa is relatively rare. Features of eustachian tubular mucosal melanoma include a complex anatomy, difficult complete resection, a high incidence of surgical complications, high rates of local recurrence and distant metastasis, and a poor overall prognosis.³ We report a case of a ruptured internal carotid artery (ICA) that was successfully rescued 3 days after resection of mucosal malignant melanoma of the eustachian tube.

Case report

A 62-year-old woman complained of persistent nasal discharge with nose bleeding

accompanied by right tinnitus for 2 years. A nasopharyngeal mass was found on a nasopharyngeal endoscopic examination at another hospital. Histopathology of the biopsy specimen showed nasopharyngeal malignant melanoma. After taking six cycles of temozolomide at another hospital, the nasopharyngeal mass did not decrease in size. Therefore, conventional segmentation radiotherapy was performed 20 times.

Finally, the patient was admitted to our hospital. A specialist examination showed a mass in the nasopharyngeal cavity with pigmentation on the surface and growth into the right nasal cavity. Enhanced magnetic resonance imaging (MRI) (Figure 1a, 1b) showed masses in the right lateral wall of the nasopharyngeal cavity, which involved the nasal cavity and was consistent with melanoma. The masses showed high-signal intensity on T1-weighted images and low-signal intensity on T2-weighted images. Non-enhanced computed tomography (CT) (Figure 1c) showed an irregular mass in the nasopharyngeal cavity with an

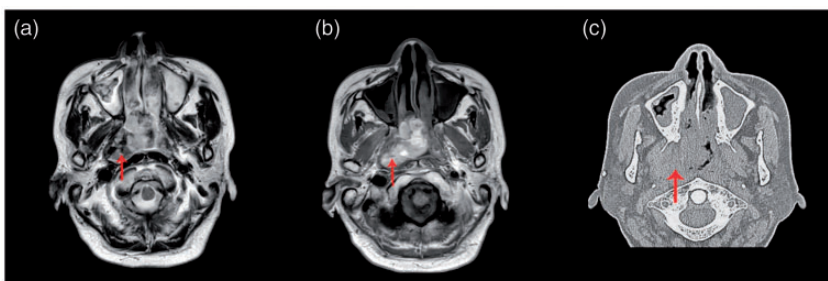


Figure 1. (a) On magnetic resonance imaging, a T2-weighted image shows masses with a low-intensity signal (arrow). (b) A T1-weighted image shows masses with a high-intensity signal (arrow). (c) An axial computed tomography scan shows a right nasopharyngeal mass (arrow).

unclear boundary with the lateral nasopharynx wall. After excluding distant metastases, such as to the chest and abdomen, the operation plan of partial resection was selected. The operation process was divided into two parts. First, surgery was performed to open the whole group of bilateral sinuses. The tumour was found at the centre of the eustachian tube, and extended forward to the nasal cavity and sinuses, and invaded the ethmoid roof and meningeal tissue. Second, the diseased meningeal tissue was removed and cerebrospinal fluid rhinorrhoea was repaired.

Two weeks later, subtotal resection of the right temporal bone with the Fisch type B posterior auricular approach and of the lateral cranial base lesions was performed in the second stage. Intraoperatively, the lesion was found to be located inferomedially to the cartilaginous portion of the eustachian tube. The cartilage and lesion were removed together up to the foramen lacerum and down to the pharyngeal orifice of the eustachian tube. The ICA was exposed and properly protected. Three days after the second operation, the patient developed sudden massive oral and nasal bleeding with a volume of approximately 300 mL. Therefore, nasal endoscopic probing was performed after endotracheal intubation under general anaesthesia at the site of haemorrhage on the right side of the nasopharynx. Because of continuous bleeding, we performed emergency cerebrovascular angiography and balloon (Cordis 6 × 20 mm; Johnson & Johnson, New Brunswick, NJ, USA) embolization of the ICA. The specific process was as follows. Super selective arteriography of the bilateral common carotid arteries, internal carotid artery, and left vertebral artery was performed, and contrast media leakage was observed in the temporal segment of the right ICA (Figure 2). Cerebral angiography showed that the anterior communicating artery was open and

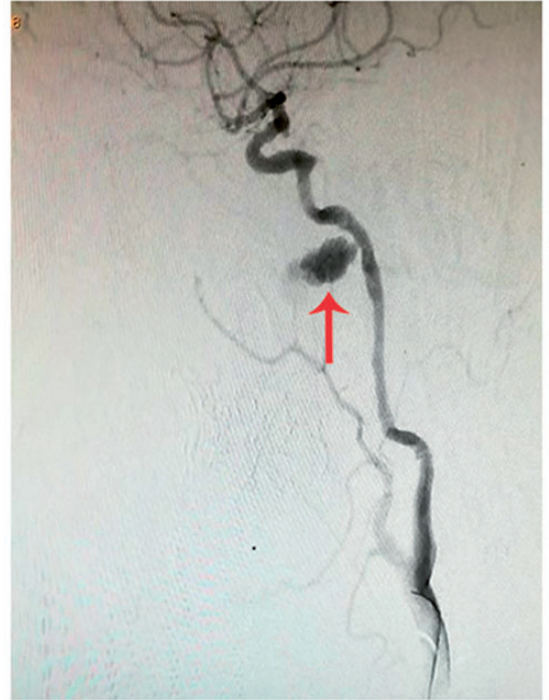

Figure 2. Cerebral angiography shows rupture of the petrosal segment of the right ICA (arrow). ICA, internal carotid artery; Cart., cartilaginous/cartilage; ET, eustachian tube; For., foramen; Genu., geniculate; Hori., horizontal; Post., posterior; Pteryg., pterygoid; Seg., segment.

the bilateral anterior cerebral arteries, middle cerebral arteries, and their branches were well developed. The balloon was placed at the distal and proximal ends of the orifice of the fistula to block the blood vessel. Postoperative angiographic results are shown in Figure 3. The patient developed transient myocardial ischaemia postoperatively, and 4 days after the treatment, the patient returned to the local hospital for medical treatment. No abnormalities were found on brain CT at discharge. After discharge, the patient did not receive any other comprehensive treatment. At the 6-month follow-up, the patient showed multiple bone and kidney metastases. She died of systemic metastases 1.5 years later.

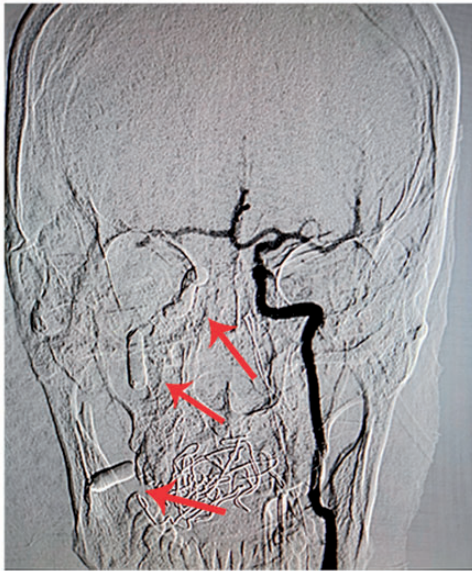


Figure 3. Cerebral angiography after right internal carotid artery embolization shows that the anterior communicating artery is opened and the balloons are well placed (arrow).

Discussion

The patient was pathologically diagnosed with nasopharyngeal mucosal malignant melanoma. Mucosal melanoma is refractory to radiotherapy and chemotherapy, and local radical resection combined with postoperative adjuvant radiotherapy is a classic treatment strategy. Our patient only received 50 Gy radiotherapy preoperatively, which could not cure the tumour. For such patients, radical surgery is essential.

Removal of the eustachian tube is a difficult surgical procedure. The eustachian tube is close to the base of the skull and is closely connected to the surrounding structures. Because the eustachian tube is adjacent to the ICA, its removal can easily damage the ICA. ICA rupture is a serious complication of removing the eustachian tube. In our case, ICA rupture occurred on the third day postoperatively, which

excluded the cause of infection. Possible reasons for rupture of the ICA in our patient are as follows. (1) The range of lesions was large and close to the ICA, which was accidentally injured because of bipolar coagulation or an electric drill during the operation. The ICA enters the skull through the carotid canal located in the petrous part of the temporal bone. The bony bed for the cartilaginous part of the eustachian tube lies parallel to the anterior and infra-anterior to the horizontal carotid canal, and is separated only by thin bone and even mucosa (Figure 4).⁴ In our case, preoperative MRI suggested a close relationship between the lesions and the blood vessels (Figure 1a, b). Therefore, the thickness of the bone wall separating the eustachian tube from the ICA and the extent of an invading lesion are closely related to the safety of the ICA. Consequently, damage to the ICA should be avoided as much as possible during the operation. Although the ICA was well exposed and protected during the operation for our patient, formation of a pseudoaneurysm may have been caused by accidental injury of the vessel wall by electrocoagulation or an electric drill. (2) Local radiotherapy can preoperatively cause the tissues to become brittle and hard, increasing the risk of intraoperative injury.

Massive bleeding from rupture of the ICA can easily cause airway asphyxia and shock. Reasonable emergency treatment measures should be taken at the bleeding site. Our patient's rescue was successful for two reasons. First, early intermittent bleeding was used to complete airway intubation and prevent the risk of airway asphyxia. Second, DSA was performed decisively, and the fistula was blocked by a balloon. In this case, after nearly 6 hours of examination, bleeding did not stop completely. The patient was transferred to the interventional chamber, and angiography showed a fracture rupture of

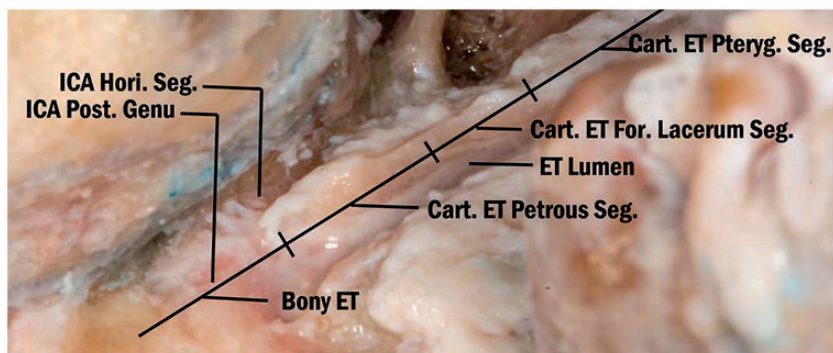


Figure 4. Anatomical relationship between the internal carotid artery and the eustachian tube.⁴

the petrosal segment of the ICA. An ICA occlusion test and full evaluation of total cerebrovascular angiography showed that the left side was well compensated, and balloon occlusion of the right ICA was finally performed. The endovascular technique is a reliable method for treating rupture of an ICA. However, embolization or catheterization should be determined on the basis of DSA results and evaluation of the openness of the cerebral circle of Willis. Many clinical studies have indicated the safety and validity of this method.^{5,6}

Because the prognosis of mucosal melanoma is not determined by the size of the primary lesion and the rate of distant metastasis is high, a follow-up period of 5 years after treatment is performed in 80% of cases.⁷ Therefore, postoperative adjuvant chemotherapy is important for improving the survival rate. Because of economic reasons, the patient was unable to complete postoperative comprehensive treatment. At the 6-month follow-up, no local recurrence was found. However, systemic metastasis occurred, and the patient died from distant metastasis. Therefore, the combination of surgery with postoperative adjuvant radiotherapy and systemic therapy, including chemotherapy, targeted therapy, or immunotherapy, for mucosal melanoma is important.

Conclusion

Eustachian tubular mucosal malignant melanoma is rare, and standardized treatment with surgery plus postoperative radiotherapy and chemotherapy are the classic regimen. Attention should be paid to protection of the ICA during surgical resection. Once the ICA ruptures and haemorrhage occurs, emergency treatment is important, including prevention of airway asphyxia, emergency haemostasis, and other anti-shock treatments. When conditions permit, DSA should be adopted as much as possible to perform balloon embolism of vascular bleeding points or stent placement.

Acknowledgements

The authors wish to acknowledge the patient's participation in this study.

Authors' contributions

LJ wrote the case report. ZJ took care of the patient. CX revised the manuscript and reviewed the final manuscript. All authors read and approved the final version of the manuscript.

Declaration of conflicting interest

The authors declare that there is no conflict of interest.


Ethics statement

The Institutional Review Board of Capital Medical University Beijing Tongren Hospital approved this study. The patient provided verbal consent for treatment and publication.

Funding

This research received no specific grant from any funding agency in the public, commercial, or not-for-profit sectors.

ORCID iD

Jianfeng Li  <https://orcid.org/0000-0003-2786-9112>

References

1. Younes MN and Myers JN. Melanoma of the head and neck: current concepts in staging, diagnosis, and management. *Surg Oncol Clin N Am* 2004; 13: 201–229.
2. Larson DL and Larson JD. Head and neck melanoma. *Clin Plast Surg* 2010; 37: 73–77.
3. Ascierto PA, Accorona R, Botti G, et al. Mucosal melanoma of the head and neck. *Crit Rev Oncol Hematol* 2017; 112: 136–152.
4. Liu J, Pinheiro-Neto CD, Fernandez-Miranda JC, et al. Eustachian tube and internal carotid artery in skull base surgery: An anatomical study. *Laryngoscope* 2014; 124: 2655–2664.
5. Sylvester PT, Moran CJ, Derdeyn CP, et al. Endovascular management of internal carotid artery injuries secondary to endonasal surgery: Case series and review of the literature. *J Neurosurg* 2016; 125: 1256–1276.
6. Pepper JP, Wadhwa AK, Tsai F, et al. Cavernous carotid injury during functional endoscopic sinus surgery: case presentations and guidelines for optimal management. *Ann J Rhinol* 2007; 21: 105–109.
7. Christopherson K, Malyapa RS, Werning JW, et al. Radiation therapy for mucosal melanoma of the head and neck. *Am J Clin Oncol* 2015; 38: 87–89.