

CASE REPORT

Anosmia caused by ischaemic olfactory infarction: false alert for COVID-19 infection

D.J. Theodorou¹, S.J. Theodorou², V. Tsaggou¹ and N. Tsifetaki³

From the ¹Department of Radiology, General Hospital of Ioannina, Makrygianni Avenue, Ioannina 45001, Greece, ²Department of Radiology, University Hospital of Ioannina, University Avenue Stavros Niarchos, Ioannina 45500, Greece and ³Department of Internal Medicine, General Hospital of Ioannina, Greece Makrygianni Avenue, Ioannina 45001, Greece

Address correspondence to D.J. Theodorou, MD, PhD, Chief, MRI-CT Unit, Department of Radiology, General Hospital of Ioannina, Greece, 13 Papadopoulos Street, Ioannina 45444 Greece. email: daphne_theodorou@hotmail.com

Learning points for clinicians

Anosmia is increasingly recognized as a complication of SARS-CoV-2 infection, or a clinical symptom that can merely mimic virus-induced olfactory dysfunction. Magnetic resonance imaging can play a major role in the detection of underlying abnormalities of the olfactory system, excluding the possibility of COVID-19-induced anosmia. This case indicates that the cause of anosmia needs to be carefully investigated, particularly in those patients who are at an increased risk for CoV-2 infection to eliminate overall diagnosis of the disease.

Case report

A 68-year-old female patient, living in a nursing home, presented to the emergency room of our hospital with sudden onset of anosmia (loss of smell), and a 3-day history of paroxysmal dry cough, headache and malaise. Comorbidities included a history of type-2 diabetes and chronic gastritis, while no previous neurologic history or head trauma was recorded. Her body temperature was 100.04°F (37.8°C) and blood pressure was normal. Mild dyspnoea, with no nasal congestion was present at the time of admission. Neurologic examination showed normal consciousness, with normal vision and auditory functions, and unaffected taste sense. The patient complained of total anosmia that was confirmed by failure to identify odours presented on both sides of her nose, while keeping her eyes closed. Laboratory studies showed iron-deficiency anaemia, and normal white blood cell, neutrophil and lymphocyte count.

C-reactive protein was elevated. In light of the ongoing COVID-19 pandemic, intimidating clinical presentation of the patient with complete loss of smell was alarming for coronavirus infection insulating CN-I (olfactory nerve). As such, sputum analysis using real-time reverse transcriptase fluorescence polymerase chain reaction was performed that yielded negative results for infection. Chest radiography and CT scans obtained at admission showed no significant findings. Brain CT revealed bilateral, hypodense lesions involving the straight gyri at the inferior frontal lobe. Magnetic resonance imaging (MRI) was then scheduled that depicted abnormal high-signal-intensity lesions adjacent to the olfactory sulci on the T2-weighted and FLAIR MR images, consistent with ischaemic infarcts (Figure 1). Interestingly, the site of infarcts correlated closely with the known anatomic distribution of the olfactory tract in the rhinencephalon (smell brain), a finding offering a plausible explanation for anosmia. The patient was informed accordingly and was subsequently discharged, with dietary/nutrition modification guidelines.

Discussion

As of October 2020, global spread of the newly discovered Coronavirus SARS-CoV-2 causing COVID-19 infection has taken a huge toll on human lives, with over a million of deaths and severe morbidity. Because of the rapidly increasing numbers of infected patients, the COVID-19 infection outbreak was promptly declared by the World Health Organization (WHO) as a pandemic.¹ Reportedly, the major clinical manifestations of

Submitted: 5 October 2020

© The Author(s) 2020. Published by Oxford University Press on behalf of the Association of Physicians. All rights reserved.

For permissions, please email: journals.permissions@oup.com

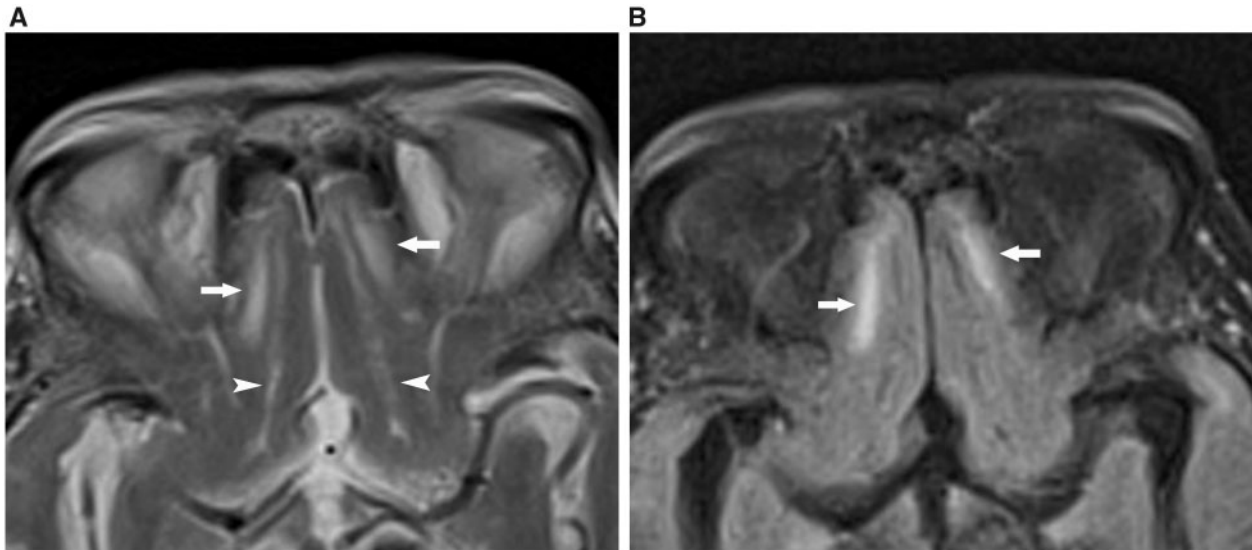


Figure 1. MR images in a 68-year-old woman with anosmia undergoing evaluation for COVID-19 infection. (A) Axial T2-weighted brain MR image shows bilateral areas of high signal intensity (arrows) in rhinobase adjacent to the olfactory sulci (arrowheads). (B) Corresponding axial FLAIR image shows high-signal-intensity infarcts (arrows), in distribution of the olfactory tract.

CoV-2 infection are fever, cough and dyspnoea, resuming in pneumonia of a variable severity. With continued and widespread transmission of the coronavirus and an increasing gain in clinical experience of the health providers, other manifestations of this dreaded infection came to light as well. Among the additional symptoms and signs encountered within the spectrum of COVID-19 infection, olfactory (sense of smell) decline (anosmia/hyposmia) that may be associated with altered taste perception (ageusia/dysgeusia) are recorded, implying underlying neurosensory dysfunction.^{2–4} Of course, mucosal congestion and nasal obstruction may as well be the cause of conductive olfactory loss (anosmia) that appears to resolve with clinical improvement of the patient. Recent evidence, however, indicates that anosmia may relate to CoV-2-mediated neuronal damage to the olfactory apparatus.⁵ In that same vein, Galougahi et al.⁶ were first to address the need for dedicated MRI examination of the olfactory bulb to investigate anosmia, in a single patient with COVID-19 infection. The MRI findings in our case with high clinical suspicion for coronavirus infection efficaciously ruled out COVID-19-induced anosmia, which conceivably should not be deemed a universal diagnosis. The words of the WHO director-general,¹ however, indicate that misuse of the term ‘pandemic’ can cause ‘unreasonable fear’ describing a global threat that needs to be confronted cautiously. In this regard, recognition of abnormal MRI findings related to the olfactory apparatus can prevent misdiagnosis in cases resembling viral olfactory neuropathy. Correct diagnosis of the cause of olfactory deficit may indeed have important implications for the prediction of the natural course of current galloping COVID-19 infection. This teaching case comes in support of previous recommendations⁶ for MRI investigation of ‘isolated’ olfactory dysfunction (specifically, in the absence of congestion of the peripheral pathway of

olfaction) in those clinical cases suspected for COVID-19 infection.

Conflict of interest. None declared.

References

1. World Health Organization. WHO Director-General’s opening remarks at the media briefing on COVID-19. 11 March 2020. <https://www.who.int/dg/speeches/detail/who-director-general-s-opening-remarks-at-the-media-briefing-on-covid-19—11-march-2020> (3 October 2020, date last accessed).
2. Centers for Disease Control and Prevention. Coronavirus disease 2019 (COVID-19). Symptoms and testing. Anosmia. National Center for Immunization and Respiratory Diseases (NCIRD), division of viral diseases, March 20, 2020. Updated April 17, 2020.
3. Kaye R, Chang C W D, Kazahaya K, Brereton J, Denneny J C. COVID-19 Anosmia Reporting Tool: Initial Findings. *Otolaryngology-Head and Neck Surgery* 2020; **163**:132–4. [10.1177/0194599820922992](https://doi.org/10.1177/0194599820922992)
4. Villalba NL, Maouche Y, Ortiz MBA, Sosa ZC, Chahbazian JB, Syrovatkova A. Anosmia and dysgeusia in the absence of other respiratory diseases: should COVID-19 infection be considered? *Eur J Case Rep Intern Med* 2020; **7**:001641.
5. Aragao MFV, Leal M, Filho O, Fonseca TM, Valenca MM. Anosmia in COVID-19 associated with injury to the olfactory bulbs evident on MRI. *AJNR Am J Neuroradiol* 2020; **41**:1703–6.
6. Galougahi MK, Ghorbani J, Bakhshayeshkaram M, Naeini AS, Haseli S. Olfactory bulb magnetic resonance imaging in SARS-CoV-2-induced anosmia: the first report. *Academ Radiol* 2020; **27**:892–3.

