



## JAK2 mutation–positive polycythaemia vera associated with IgA vasculitis and nephrotic syndrome: a case report

Hinako Kondo, Ryu Watanabe, Soshi Okazaki, Kaori Kuriyama, Tetsuro Ochi, Gen Yamada, Akira Sugiura, Hiromu Chiba, Akira Tsukada, Shinji Taniuchi, Takehiko Igarashi, Masataka Kudo, Hideo Harigae & Hiroshi Fujii

To cite this article: Hinako Kondo, Ryu Watanabe, Soshi Okazaki, Kaori Kuriyama, Tetsuro Ochi, Gen Yamada, Akira Sugiura, Hiromu Chiba, Akira Tsukada, Shinji Taniuchi, Takehiko Igarashi, Masataka Kudo, Hideo Harigae & Hiroshi Fujii (2020): JAK2 mutation–positive polycythaemia vera associated with IgA vasculitis and nephrotic syndrome: a case report, Modern Rheumatology Case Reports, DOI: [10.1080/24725625.2020.1728061](https://doi.org/10.1080/24725625.2020.1728061)

To link to this article: <https://doi.org/10.1080/24725625.2020.1728061>



Published online: 13 Feb 2020.



Submit your article to this journal [↗](#)



Article views: 13

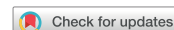

View related articles [↗](#)




View Crossmark data [↗](#)

CASE REPORT



## JAK2 mutation–positive polycythaemia vera associated with IgA vasculitis and nephrotic syndrome: a case report

Hinako Kondo<sup>a</sup>, Ryu Watanabe<sup>a,b</sup> , Soshi Okazaki<sup>a</sup>, Kaori Kuriyama<sup>a</sup>, Tetsuro Ochi<sup>b</sup>, Gen Yamada<sup>c</sup>, Akira Sugiura<sup>c</sup>, Hiromu Chiba<sup>d</sup>, Akira Tsukada<sup>d</sup>, Shinji Taniuchi<sup>e</sup>, Takehiko Igarashi<sup>f</sup>, Masataka Kudo<sup>c</sup>, Hideo Harigae<sup>b</sup> and Hiroshi Fujii<sup>b</sup>

<sup>a</sup>Department of Rheumatology, Osaki Citizen Hospital, Osaki, Japan; <sup>b</sup>Department of Hematology and Rheumatology, Tohoku University Graduate School of Medicine, Sendai, Japan; <sup>c</sup>Department of Nephrology and Endocrinology, Osaki Citizen Hospital, Osaki, Japan; <sup>d</sup>Department of Dermatology, Osaki Citizen Hospital, Osaki, Japan; <sup>e</sup>Department of Pathology, Osaki Citizen Hospital, Osaki, Japan; <sup>f</sup>Department of Gastroenterology, Osaki Citizen Hospital, Osaki, Japan

### ABSTRACT

We report a case of polycythaemia vera (PV) associated with IgA vasculitis. A 45-year-old man was admitted for evaluation of abdominal pain and palpable purpura. IgA vasculitis was diagnosed, and oral prednisolone therapy (30 mg/day) was initiated. On day 6, the patient developed left hemiparesis, and magnetic resonance imaging revealed acute cerebral infarction. Bone marrow biopsy results and the identification of a Janus kinase 2 (*JAK2*) mutation led to the diagnosis of PV. Despite steroid therapy, urine protein levels increased to 15 g/g-Cre. Renal biopsy demonstrated mild mesangial proliferation with IgA deposits, but immunosuppressive therapy was partially effective. This case suggests that PV can be a complication of IgA vasculitis and that preventive measures for thrombosis should be taken in such cases.

### ARTICLE HISTORY

Received 22 November 2019  
Accepted 3 February 2020

### KEYWORDS

IgA vasculitis; Janus kinase 2 (*JAK2*); myeloproliferative neoplasms; nephrotic syndrome; polycythaemia vera

### Introduction

IgA vasculitis, which is formerly known as Henoch-Schönlein purpura, is one of the systemic vasculitides and is categorised as small-vessel vasculitis [1]. IgA vasculitis often affects the skin, joints, gastrointestinal tract, and the kidneys. The pathogenesis of this disease remains unclear. However, it is characterised by the presence of IgA1-dominant immune complexes deposited in the vessel walls and renal glomeruli [2]. IgA vasculitis was thought to mainly occur in children, but recent studies show that it also affects adults. The prognosis of IgA vasculitis in adults is not always favourable; patients with adult onset have a higher risk of hypertension, chronic kidney disease, and increased mortality [3,4].

Myeloproliferative neoplasms (MPNs) are haematopoietic disorders characterised by an overproduction of differentiated haematopoietic cells [5]. MPN includes three major diseases: polycythaemia vera (PV), essential thrombocythemia (ET), and primary myelofibrosis (PMF) [6]. Patients with MPN are at increased risk of thrombotic and cardiovascular events, as well as progression to acute leukaemia or bone marrow failure [6]. Recent advances in the understanding of the molecular basis underlying MPN have led to the development of novel targeted

therapies. For example, a single-point mutation in *Janus kinase 2 (JAK2)* was identified in 2005 [7]. *JAK2* V167F mutations constitutively activate intracellular downstream signalling *via* signal transducers and activators of transcription (STATs), and this leads to increased risk of thrombosis [7]. More than 90% of patients with PV and approximately half of patients with ET and PMF have *JAK2* mutations [8]. Ruxolitinib, which is a *JAK1/2* inhibitor, is currently approved and provides clinical benefits to patients with MPN [9,10].

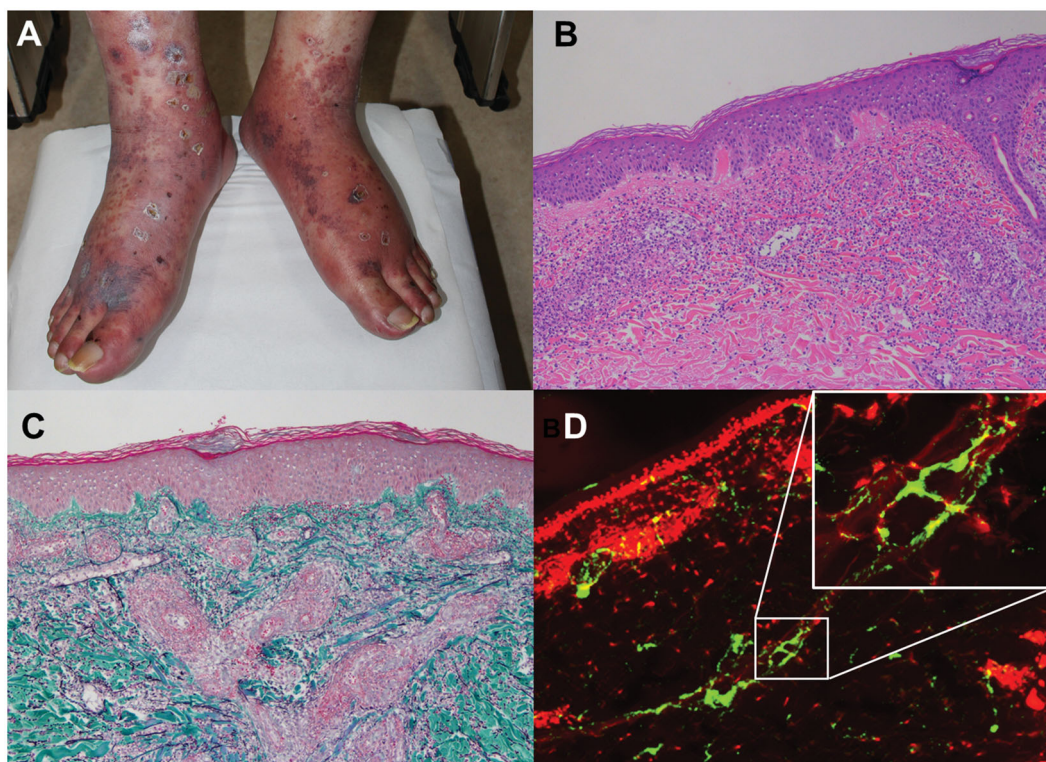
MPN sometimes develops into glomerulonephritis, including focal segmental glomerulosclerosis (FSGS), membranoproliferative glomerulonephritis (MPGN), and membranous nephropathy (MN) [11]. Several cases of IgA nephropathy that are associated with MPN, particularly PV, have also been reported [12–14]. However, the simultaneous diagnosis of IgA vasculitis and PV is extremely rare; to the best of our knowledge, there is only one reported case of this simultaneous diagnosis, which was published in 1994 without any descriptions of gene mutations [15]. In the present study, we report the case of a 45-year-old man who was diagnosed with IgA vasculitis and *JAK2* mutation–positive PV. The patient developed acute cerebral infarction and nephrotic

syndrome under steroid therapy. This case illustrates that PV can be a complication of IgA vasculitis and that preventive measures for thrombosis should be taken in such cases.

### Case presentation

A 45-year-old Japanese man was referred to our department for evaluation and therapy owing to persistent fever, abdominal pain, and palpable purpura. When he was 26 years old, he was diagnosed as a hepatitis B virus (HBV) carrier. He also had a medical history of panic disorder, hypertension, hyperlipidaemia, diabetes mellitus, and hyperuricaemia treated with amlodipine, febuxostat, and teneligliptin for 2 years. In the past 10 years, mild increases in serum haemoglobin level and platelet counts have been observed without treatment. Two months before admission, his serum haemoglobin level and platelet count were 18.6 g/dL and  $38.8 \times 10^4/\mu\text{L}$ . On admission, body height was 173.6 cm, body weight was 62.7 kg, and body mass index was 20.8. Body temperature was 38.0°C, blood pressure was 138/84 mmHg, heart rate was 114 beats/min, and oxygen saturation level (SpO<sub>2</sub>) was 95%. Physical examination revealed palpable purpura with small ulcers throughout the body, including on the lower legs, waist, back and forearms (Figure 1(A)). The patient was conscious and had no neurological deficits. Laboratory tests showed an elevated C-reactive protein (CRP) level (10.0 mg/dL)

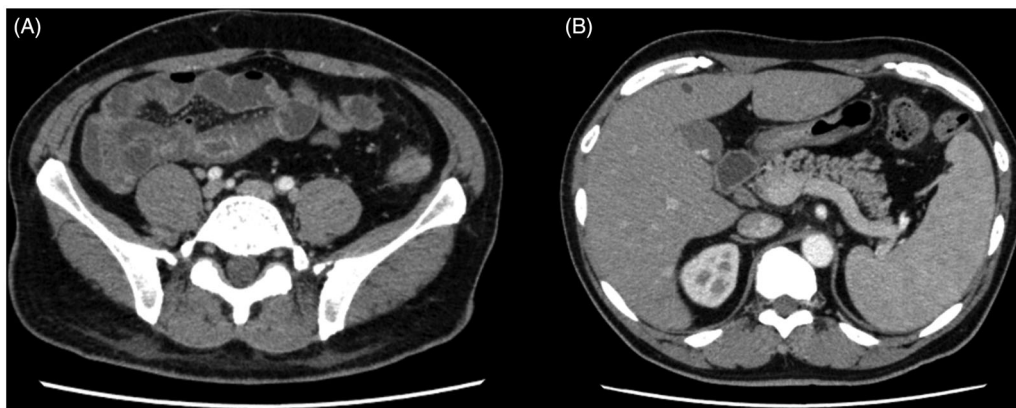
and increased haemoglobin (18.1 g/dL) and platelet counts ( $83.3 \times 10^4/\mu\text{L}$ ). The urine protein level on admission was 0.31 g/g·Cre (Table 1). Cryoglobulin test and antineutrophil cytoplasmic antibodies were negative. Other microbiological tests were negative. An enhanced computed tomography (CT) scan showed extensive oedema of the small intestine (Figure 2(A)) and splenomegaly (Figure 2(B)). Skin biopsy from the right lower leg revealed inflammatory cell infiltration into the dermis, particularly around the small-sized vessels, and was compatible with leukocytoclastic vasculitis (Figure 1(B,C)). IgA deposits were observed in the small-vessel walls (Figure 1(D)). These findings led to a diagnosis of IgA vasculitis [16], and 30 mg/day of oral prednisolone (PSL) was initiated. On day 6, the patient suddenly developed left hemiparesis, and magnetic resonance imaging (MRI) revealed high-intensity signals in his right frontal and parietal lobes (Figure 3(A)). CT angiography did not indicate any abnormality (Figure 3(B)). We could not exclude the possibility that acute cerebral infarction was due to cerebral involvement in IgA vasculitis. However, we assumed that stroke was caused by a hematological disorder because of the high haemoglobin level and platelet counts and consulted to a haematologist. A bone marrow biopsy was hypercellular without fibrotic change. All lineages of granulocytes, erythroblasts, and megakaryocytes were proliferated. Enlarged megakaryocytes were particularly increased (Figure 4). The genetic screening of peripheral blood revealed a *JAK2*



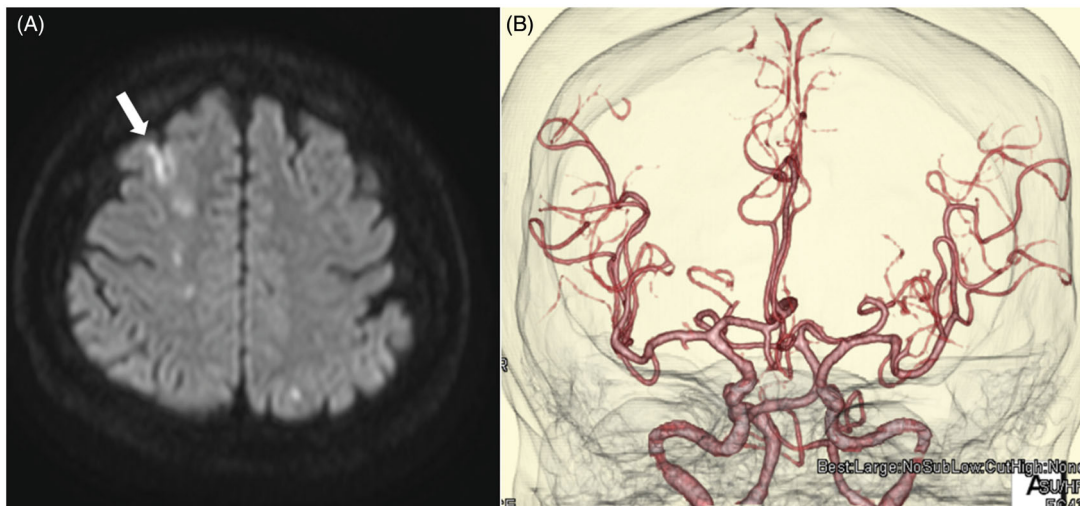
**Figure 1.** Skin lesions on the patient. (A) Palpable purpura in the lower legs. (B, C) Skin biopsy showing leukocytoclastic vasculitis in the dermis (haematoxylin and eosin staining (B) and Elastica–Masson staining (C),  $\times 200$ ). (D) IgA immunofluorescent staining ( $\times 200$ ). Green fluorescent indicates IgA, and red fluorescent indicates propidium iodide for nuclear stain.

**Table 1.** Laboratory tests of the patient.

Complete blood cell counts			Urinalysis					
WBC	8,920	/μL	Protein	(1+)		BUN	16.9	mg/dL
Band	22	%		0.31	g/g Cre	Cr	0.72	mg/dL
Seg	53	%	Urinary sugar	(2+)		CRP	10.0	mg/dL
Lym	9	%	RBC	0–1	/HPF	Glu	265	mg/dL
Mon	10	%	WBC	0–1	/HPF	HbA1c	8.0	%
Eos	3	%				IgG	1,097	mg/dL
Bas	1	%	Biochemistry			IgA	522	mg/dL
RBC	634 × 10 <sup>4</sup>	/μL	T.Bil	0.82	mg/dL	IgM	39	mg/dL
Hb	18.1	g/dL	D.Bil	0.35	mg/dL	ANA	<40	fold
MCV	78.7	fl	ALP	357	IU/L	PR-3ANCA	<1.0	U/mL
Hct	49.9	%	γ-GTP	56	IU/L	MPO-ANCA	<1.0	U/mL
Plt	83.3 × 10 <sup>4</sup>	/μL	AST	20	IU/L	HBs antigen	56.22	IU/mL
			ALT	36	IU/L	HbC antibody	8.1	S/CO
Coagulation			LDH	230	IU/L	HBs antibody	5.8	mIU/mL
PT	72.6	%	TP	5.5	g/dL	HBV-DNA	<1.0	LC/mL
APTT	31.6	sec	Alb	2.3	g/dL			
Fbg	330	mg/dL	Na	126	mEq/L	Microbiology		
D-Dimer	28.1	μg/mL	K	7.1	mEq/L	β-D glucan	(-)	
Factor XIII	35	%	Cl	95	mEq/L	T-SPOT	(-)	



**Figure 2.** Enhanced CT of the abdomen. CT scan showed extensive oedema of the small intestine (A) and splenomegaly (B).

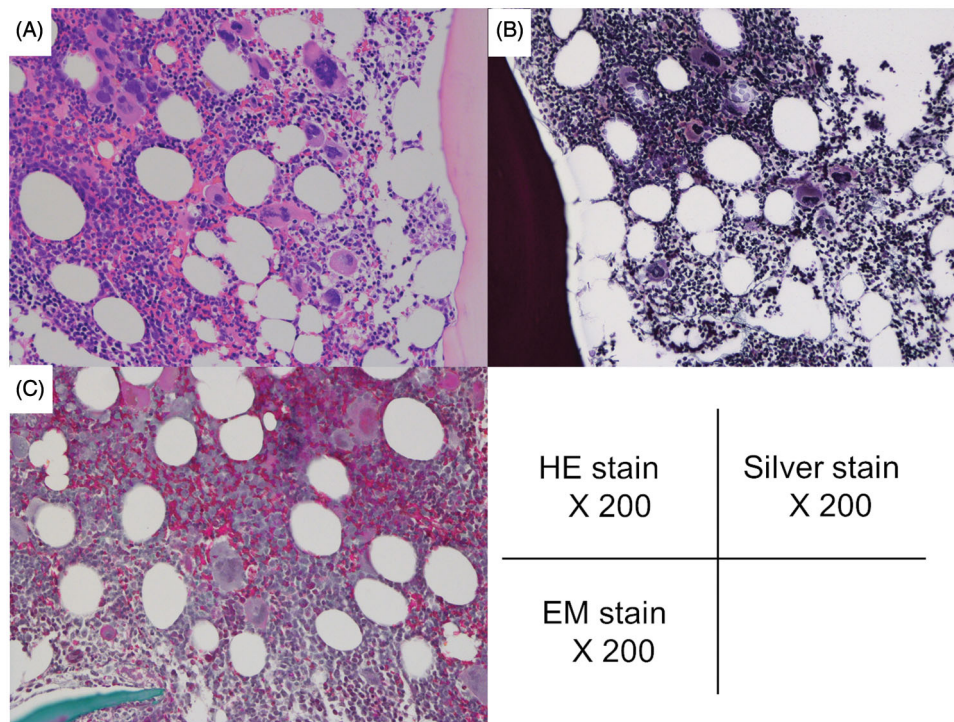


**Figure 3.** MRI of the head. (A) Diffusion-weighted imaging. High-intensity signals were observed in the right frontal and parietal lobes (arrow). (B) CT angiography did not show any abnormality.

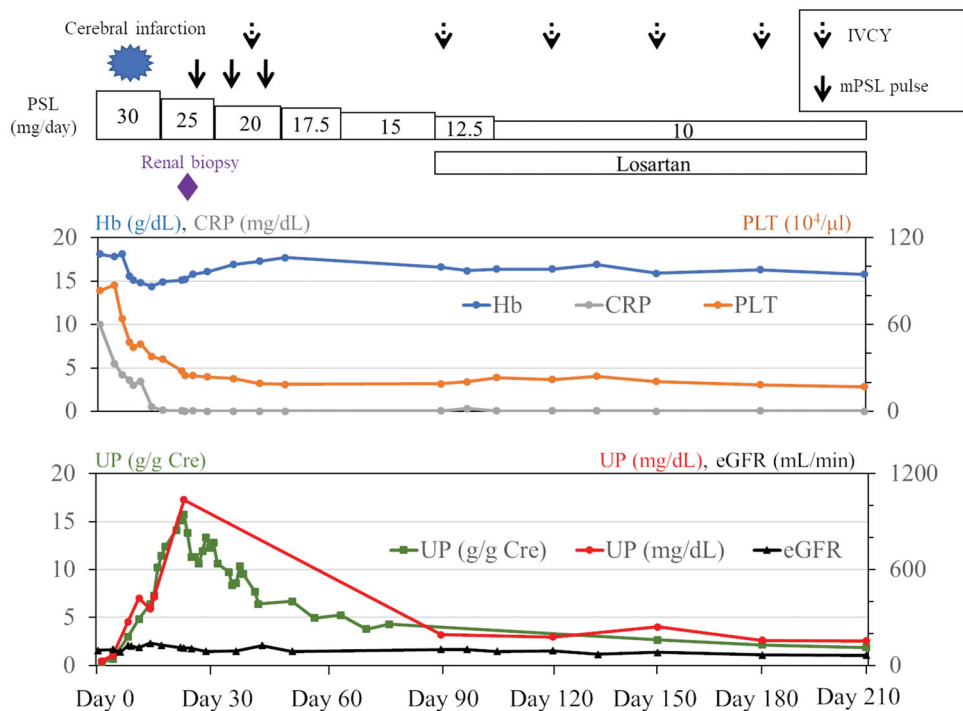
V617F mutation ( $5.5 \times 10^3$  copies, 20.9%). Neutrophil *BCR-ABL1* translocation (9; 22) was not detected. On the basis of the World Health Organisation (WHO) criteria [17], a diagnosis of PV was made, and low dose aspirin was added to the therapy.

Skin lesions, serum CRP level, and platelet counts improved with oral steroid therapy and the left

hemiparesis resolved within three weeks; however, the urine protein level increased gradually and reached 15 g/g·Cre (Figure 5). Haematuria (50–99 per high-power field) was also observed. Renal biopsy showed mild mesangial proliferation and tubular atrophy (Figure 6). Among the seven glomeruli, none was globally sclerosed, but small crescent formations



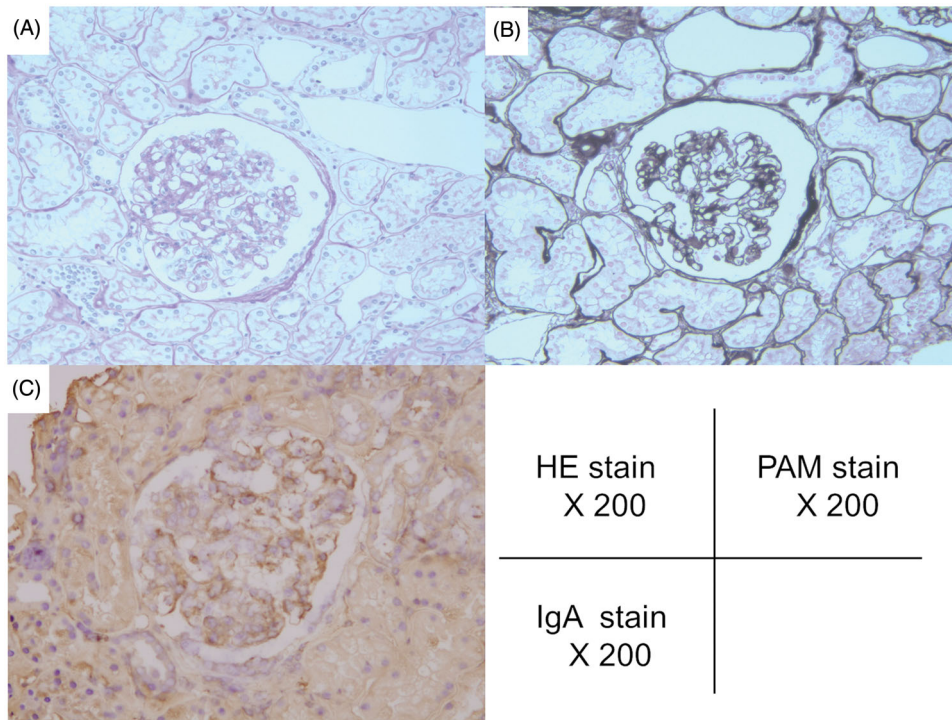
**Figure 4.** Bone marrow biopsy of the patient. Bone marrow was hypercellular and fibrosis was not observed. All lineages of granulocytes, erythroblasts, and megakaryocytes were proliferated. Megakaryocytes were particularly increased. (A) Haematoxylin and eosin staining ( $\times 200$ ), (B) silver staining ( $\times 200$ ) and (C) Elastica–Masson staining ( $\times 200$ ).



**Figure 5.** Clinical course of the patient. CRP, C-reactive protein; eGFR, estimated glomerular filtration rate; Hb, haemoglobin; IVCY, intravenous cyclophosphamide therapy; mPSL, methylprednisolone; PLT, platelet; PSL, prednisolone; UP, urine protein.

were observed in two glomeruli. IgA was deposited in the mesangial matrix (Figure 6). These findings were consistent with IgA vasculitis, and no other causes of nephrotic syndrome, such as FSGS and MPGN, were found in the biopsy. Urine protein levels were partially reduced after three courses of

methylprednisolone (mPSL) pulse therapy (1 g/day for three days), intravenous cyclophosphamide (IVCY) pulse therapy (500 mg/day), and losartan, an angiotensin II blocker (Figure 5). The estimated glomerular filtration rate was maintained, but the patient's urine protein levels still measured approximately 2 g/g·Cre.



**Figure 6.** Renal biopsy findings. Mild mesangial proliferation, tubular atrophy, and IgA deposits in the mesangial matrix were observed. (A) Haematoxylin and eosin staining ( $\times 200$ ), (B) PAM staining ( $\times 200$ ), and (C) IgA staining ( $\times 200$ ). (B) IgA deposition in the mesangial matrix.

## Discussion

We describe a very rare case of PV associated with IgA vasculitis and nephrotic syndrome. IgA vasculitis was diagnosed, and oral steroid therapy was initiated immediately. However, the patient developed cerebral infarction within a week, thus prompting the diagnosis of PV. Urine protein level was elevated to well above the nephrotic range under steroid therapy. Renal biopsy only demonstrated mild mesangial proliferation, but intensive immunosuppressive therapy including mPSL pulse and IVCY pulse therapy was not able to induce clinical remission.

Stroke is rare but sometimes occurs in adult IgA vasculitis [18]. Elderly patients aged over 65 years old have a higher incidence of stroke than age-matched healthy individuals [18]. IgA vasculitis with childhood onset also has neurologic manifestations in 2% to 8% of patients, including seizure, cerebral oedema, haemorrhage, encephalopathy and cerebral vein thrombosis [19]. Patients with PV are also at increased risk of thrombotic events, and arterial and venous thromboembolism is the major cause of morbidity and mortality in patients with PV [20]. The risk factors for thrombosis in PV include age of 60 years or over, past history of thrombosis, high-haematocrit value, presence of *JAK2* mutation, and leukocytosis [20,21]. The 10-year incidence rate of thrombosis in patients possessing the *JAK2* mutation is 21% [20]. A recent molecular study showed that the *JAK2* V617F mutation leads to the aberrant activation of integrins

and adhesion molecules expressed on leukocytes [22]. In our case, there was a possibility that the cerebral involvement of IgA vasculitis caused acute cerebral infarction. However, we now believe that *JAK2*-mutated blood cells, as well as dehydration, past medical history such as diabetes mellitus, initiation of steroid therapy, and enhanced coagulation associated with nephrotic syndrome, contributed to the onset of stroke. We also regret not taking actions to prevent thrombosis on admission, such as hydration, bloodletting, or low dose aspirin.

We initially believed that this patient had ET because of high platelet counts ( $83.3 \times 10^4/\mu\text{L}$ ) and the results of a bone marrow biopsy, which showed a particular increase in megakaryocytes (Figure 4). However, if the patient fulfils the criteria for PV, they cannot be diagnosed with ET according to the WHO classification (17). The WHO classification for PV includes three major criteria; (1) haemoglobin level  $> 16.5$  g/dL, (2) hypercellular bone marrow associated with triple lineage expansion, and (3) *JAK2* V617F mutation or *JAK2* exon 12 mutation. One minor criterion is low serum erythropoietin level [17]. In our patient, serum erythropoietin level was 2.0 mIU/mL (where the normal range is from 4.2 to 23.7 mIU/mL). Therefore, our patient fulfilled the criteria for PV, excluding the diagnosis of ET. It is known that patients with *JAK2* mutation-positive ET have multiple features that resemble PV, such as high haematocrit [23]. However, after immunosuppressive therapy, the platelet count normalised, but

the haemoglobin level remained slightly elevated (Figure 5); this also supported our diagnosis.

The prevalence of renal involvement in IgA vasculitis is 30%–50% [18,24]. The most commonly observed urinary finding is microscopic haematuria and/or mild proteinuria. However, some patients progress to renal failure or end-stage renal disease. A recent meta-analysis showed that complications of nephrotic syndrome in IgA vasculitis are associated with unfavourable renal outcomes in children [24]. In our patient, renal biopsy demonstrated mild mesangial cell proliferation, which was compatible with IgA vasculitis, but it was difficult to explain the massive proteinuria. Furthermore, intensified immunosuppressive therapy was not sufficiently effective. Considering that PV is complicated by FSGS, MPGN, and MN [11], steroid-refractory glomerular diseases may exist in our case. Kanauchi et al. reported a case of IgA vasculitis associated with PV that developed during ranimustine therapy for PV [15]. The first renal biopsy showed MPGN, and the second biopsy revealed crescentic formation with IgA deposition [15]. Therefore, proteinuria should be closely monitored, and a second renal biopsy should be considered if the patient relapses.

The reason for the development of nephrotic syndrome in the patient under steroid therapy may be that the initial dose of PSL (30 mg/day) was not enough for inducing clinical remission. Regarding the treatment of IgA vasculitis, there is insufficient evidence on the initial dose of steroid [25]. In addition, the patient was a current HBV carrier and hepatitis B is a serious concern not only for current HBV carriers but also for resolved HBV carriers under immunosuppressive therapy [26]. That is why we chose medium dose of PSL (30 mg/day) and started entecavir simultaneously. Fortunately, HBV-DNA remains well controlled thus far.

Currently, the JAK-STAT pathway is an attractive therapeutic target in autoimmune disease [27]. Interleukin (IL)–2, IL-4, IL-7, IL-6, IL-9, IL-15, granulocyte macrophage colony-stimulating factor, and other cytokines transduce signals *via* the JAK-STAT pathway [27]. JAK inhibitors have been found to be effective not only in rheumatoid arthritis but also in systemic lupus erythematosus, ulcerative colitis, psoriasis, and other diseases [28]. Data from a mouse model also indicate that JAK inhibitors show promise in the treatment of vasculitis [29]. In our case, the haematocrit level remains high (>45%), and it is possible that *JAK2*-mutated blood cells are still causing glomerular injury. Therefore, ruxolitinib, which is a JAK1 and JAK2 inhibitor, may provide a benefit to our patient. However, ruxolitinib was not used in this case because of the patient's financial circumstances.

The mechanism underlying simultaneous development of PV and IgA vasculitis is unclear. It has been reported that patients with *JAK2* mutation sometimes develop vasculitis or vasculitis-like symptom [30,31]. However, coexistence of PV and IgA vasculitis is extremely rare and there have been no reports showing that IgA is involved in the pathogenesis of MPN and *JAK2* is associated with class-switching of IgA. Therefore, we cannot conclude that the disease mechanism is shared in these diseases.

In conclusion, we present a case report of *JAK2* mutation-positive PV associated with IgA vasculitis. Coexistence of these diseases is rare, but we believe that patients having both diseases do exist. In such cases, actions should be taken to prevent thrombosis as soon as possible because it can be fatal.

### Patient consent

Written informed consent to publish this case report was obtained from the patient.

### Conflict of interest

None.

### Ethical approval

Not applicable.

### Authors' contributions

HK, RW, SO, KK, TO, GY, AS, HC, AT, TI, and MK provided medical care for the patient in the case report. ST performed a pathological assessment of the case. HK and RW wrote the manuscript. HK, RW, HH, and HF finalised the manuscript.

### ORCID

Ryu Watanabe  <http://orcid.org/0000-0002-1089-5296>

### References

- [1] Jennette JC, Falk RJ, Bacon PA, et al. 2012 revised international chapel hill consensus conference nomenclature of vasculitides. *Arthritis Rheum.* 2013; 65(1):1–11.
- [2] Rai A, Nast C, Adler S. Henoch-Schönlein purpura nephritis. *J Am Soc Nephrol.* 1999;10(12):2637–2644.
- [3] Hocever A, Rotar Z, Jurcic V, et al. Patient age, gender and extent of purpura may suggest short-term outcomes in adults with IgA vasculitis. *Rheumatology (Oxford).* 2015;54:1330–1332.
- [4] Tracy A, Subramanian A, Adderley NJ, et al. Cardiovascular, thromboembolic and renal outcomes in IgA vasculitis (Henoch-Schönlein purpura): a retrospective cohort study using routinely

- collected primary care data. *Ann Rheum Dis.* 2019;78(2):261–269.
- [5] Nangalia J, Green AR. Myeloproliferative neoplasms: from origins to outcomes. *Blood.* 2017;130(23):2475–2483.
- [6] Spivak JL. Myeloproliferative neoplasms. *N Engl J Med.* 2017;376(22):2168–2181.
- [7] James C, Ugo V, Le Couedic JP, et al. A unique clonal JAK2 mutation leading to constitutive signaling causes polycythemia vera. *Nature.* 2005;434(7037):1144–1148.
- [8] Bazter E, Scott LM, Campbell PJ, et al. Acquired mutation of the tyrosine kinase JAK2 in human myeloproliferative disorders. *Lancet.* 2005;365:1054–1061.
- [9] Verstovsek S, Mesa RA, Gotlib J, et al. A double-blind, placebo-controlled trial of ruxolitinib for myelofibrosis. *N Engl J Med.* 2012;366(9):799–806.
- [10] Vannucchi AM, Kiladjan JJ, Griesshammer M, et al. Ruxolitinib versus standard therapy for the treatment of polycythemia vera. *N Engl J Med.* 2015;372(5):426–435.
- [11] Fujita K, Hatta K. Renal biopsy cases in myeloproliferative neoplasms (MPN). *CEN Case Rep.* 2013;2(2):215–221.
- [12] Kasuno K, Ono T, Kamata T, et al. IgA nephropathy associated with polycythemia vera: accelerated course. *Nephrol Dial Transplant.* 1997;12(1):212–215.
- [13] Chung J, Park PG, Song KI. IgA nephropathy in a patient with polycythemia vera. Clinical manifestation of chronic renal failure and heavy proteinuria. *Am J Nephrol.* 2002;22(4):397–401.
- [14] Chen H, Zhang B, Li M, et al. Polycythemia vera associated with IgA nephropathy: a case report and literature review. *Exp Ther Med.* 2015;10(2):555–560.
- [15] Kanauchi M, Dohi K, Shiiki H, et al. Henoch-Schönlein purpura nephritis associated with polycythemia vera. *Intern Med.* 1994;33(1):36–40.
- [16] Ozen S, Pistorio A, Iusan SM, et al. EULAR/PRINTO/PRES criteria for Henoch-Schönlein purpura, childhood polyarteritis nodosa, childhood Wegener granulomatosis and childhood Takayasu arteritis: Ankara 2008. Part II: final classification criteria. *Ann Rheum Dis.* 2010;69(5):798–806.
- [17] Swerdlow SH, Campo E, Harris NL, et al. WHO classification of tumours of haematopoietic and lymphoid tissues. Lyon: IARC; 2017.
- [18] Hocever A, Tomsic M, Rotar Z. IgA vasculitis in adults: few certainties and many uncertainties. *Ann Rheum Dis.* 2019;0:1.
- [19] Belman AL, Leicher CR, Moshe SL, et al. Neurologic manifestations of Schonlein-Henoch purpura: report of three cases and review of the literature. *Pediatrics.* 1985;75(4):687–692.
- [20] Marchioli R, Finazzi G, Specchia G, et al. Cardiovascular events and intensity of treatment in polycythemia vera. *N Engl J Med.* 2013;368(1):22–33.
- [21] Barbui T, Masciulli A, Marfisi MR, et al. White blood cell counts and thrombosis in polycythemia vera: a subanalysis of the CYTO-PV study. *Blood.* 2015;126(4):560–561.
- [22] Edelmann B, Gupta N, Schnoeder TM, et al. JAK2-V617F promotes venous thrombosis through  $\beta 1/\beta 2$  integrin activation. *J Clin Invest.* 2018;128(10):4359–4371.
- [23] Campbell PJ, Scott LM, Buck G, et al. Definition of subtypes of essential thrombocythemia and relation to polycythemia vera based on JAK2 V617F mutation status: a prospective study. *Lancet.* 2005;366(9501):1945–1953.
- [24] Shi D, Chan H, Yang X, et al. Risk factors associated with IgA vasculitis with nephritis (Henoch-Schönlein purpura nephritis) progressing to unfavorable outcomes: a meta-analysis. *PLoS One.* 2019;14(10):e0223218.
- [25] Audemard-Verger A, Pillebout E, Guillevin L, et al. IgA vasculitis (Henoch-Schönlein purpura) in adults: diagnostic and therapeutic aspects. *Autoimmun Rev.* 2015;14(7):579–585.
- [26] Watanabe R, Ishii T, Kobayashi H, et al. Prevalence of hepatitis B virus infection in patients with rheumatic diseases in Tohoku area: a retrospective multicenter survey. *Tohoku J Exp Med.* 2014;233(2):129–133.
- [27] Schwartz DM, Bonelli M, Gadina M, et al. Type I/II cytokines, JAKs, and new strategies for treating autoimmune diseases. *Nat Rev Rheumatol.* 2016;12(1):25–36.
- [28] Jamilloux Y, El Jammal T, Vuitton L, et al. JAK inhibitors for the treatment of autoimmune and inflammatory diseases. *Autoimmun Rev.* 2019;18(11):102390.
- [29] Zhang H, Watanabe R, Berry GJ, et al. Inhibition of JAK-STAT signaling suppresses pathogenic immune responses in medium and large vessel vasculitis. *Circulation.* 2018;137(18):1934–1948.
- [30] Koudoukpo C, Jachiet M, Zini M, et al. Urticarial vasculitis associated with essential thrombocythemia progressing to myelofibrosis. *Ann Dermatol Venereol.* 2014;141(12):773–776.
- [31] Beynon C, Huws G, Lawson T. Myeloproliferative disease: an unusual cause of Raynaud's phenomenon and digital ischemia. *Case Rep Med.* 2016;2016:1–2.