



Contrast-induced encephalopathy mimicking total anterior circulation stroke: a case report and review of the literature

Martina Vigano¹ · Vittorio Mantero¹ · Paola Basilico¹ · Christian Cordano² · Davide Sangalli¹ · Paolo Reganati³ · Alessandro Lunghi³ · Andrea Rigamonti¹ · Andrea Salmaggi¹

Received: 22 June 2020 / Accepted: 17 October 2020
© Fondazione Società Italiana di Neurologia 2020

Abstract

Introduction Contrast-induced encephalopathy is a rare and usually reversible entity due to the administration of iodinated contrast. Clinical manifestations include cortical blindness, encephalopathy, seizures and focal neurological deficits.

Methods We report the case of a 56-year-old woman who developed global aphasia and right hemiplegia after a cerebral angiography performed for a subarachnoid haemorrhage. A prompt brain MRI resulted negative, while CT scan revealed left cerebral oedema with the cerebral sulci effacement. Complete recovery was observed in 10 days.

Discussion Diagnosis of contrast-induced encephalopathy requires a temporal correlation between neurological dysfunction and administration of iodinated contrast. Usually, the symptomatology is transient with a full recovery within 48–72 h. The most common symptom is cortical blindness, while other symptoms have been rarely reported. Only 20 cases previously reported global aphasia and/or hemiplegia or mimed anterior circulation strokes. Prompt brain neuroimaging is essential in order to exclude an alternative diagnosis that requires a distinct therapeutic approach.

Keywords Contrast-induced encephalopathy · Iodinated contrast · Reversible encephalopathy · Stroke mimics · Stroke chameleons

Introduction

Contrast-induced encephalopathy (CIE) is a rare, acute and usually reversible neurological entity associated with intra-arterial administration of iodinated contrast. Risk factors seem to be hypertension and renal failure. Clinical manifestations include cortical blindness, encephalopathy, seizures and focal neurological deficits. In most reported cases, the symptoms are reversible and fatal encephalopathy has been rarely reported [1].

Herein, we describe a patient who suffered from long-lasting but fully reversible hemiplegia and global aphasia after a brain angiography.

Case report

A 56-year-old right-handed woman has admitted to our emergency department for acute onset of intense headache which started in the previous 2 days. She had a history of migraine, renal colic, smoking and previous heroin abuse 20 years earlier. The brain CT scan showed a small interhemispheric posterior-left parafalcine subarachnoid haemorrhage.

Cerebral angiography showed two small aneurysms involving the left carotid siphon, the left posterior cerebral artery and the left choroidal artery. After a collegial discussion between neurologists, neuroradiologists and neurosurgeons, these aneurysms were considered incidental, so we decided to treat them later.

Ten days after, a second cerebral angiography was performed to exclude the presence of a third aneurism in the area of the haemorrhage. A total of 70 ml of iomeprol (Iomeron®

✉ Vittorio Mantero
vittorio.mantero@hotmail.com

¹ Neurological Department, “A. Manzoni” Hospital, ASST Lecco, Via dell’Eremo 9/11, 23900 Lecco, Italy

² UCSF Weill Institute for Neurosciences, Department of Neurology, University of California, San Francisco, San Francisco, CA, USA

³ Neuroradiological Unit, “A. Manzoni” Hospital, ASST Lecco, Lecco, Italy

300 mg/ml) was administered during the procedure, and no haemorrhage or vasospasm complicated the procedure. However, at the end of the angiography, the patient developed global aphasia and right hemiplegia.

A brain MRI with T2, FLAIR and DWI sequences was immediately performed, excluding ischaemic or haemorrhagic events (Fig. 1a). No artery occlusion, dissection or reversible vasospasm was detected on the brain MRI angiography (Fig. 1d). A brain CT scan was performed 4 h later and revealed left cerebral oedema with effacement of the *cerebral sulci* (Fig. 1b, c). The absence of oedema on MRI is likely due to execution time, immediately after cerebral angiography.

The next day she was subjected to cerebrospinal fluid (CSF) examination showing 150 protein/mm³ and normal cell count, and to electroencephalography negative for epileptic seizures.

The diagnosis of CIE was performed, and the patient started dexamethasone and compound sodium chloride injection to facilitate the elimination of the contrast agent. A brain CT scan on day 2 showed resolution of cerebral oedema (Fig. 1e, f). The patient presented slow progressive neurological improvement with complete recovery in 10 days.

Discussion

CIE is a well-known complication of cerebral angiography. The diagnosis requires a temporal correlation (minutes to hours) between administering iodinated contrast and symptoms and signs of neurological dysfunction. Usually, the

symptomatology is transient with a full recovery within 48–72 h. Moreover, the diagnosis should not be attributable to other pathological processes [2]. The presentation of CIE is similar to embolic or haemorrhagic complications following angiography. A prompt brain neuroimaging is instrumental to exclude these alternative diagnoses that require a distinct therapeutic approach. DWI images on MRI are important to distinguish cytotoxic from vasogenic oedema, in which diffusion is normal or increased.

CIE's pathogenesis is not completely understood but probably related to temporary disruption of the blood-brain barrier (BBB) after injection of iodinated contrast. Consequently, hyperosmolality and direct neurotoxicity of contrast media in the extracellular space could further result in cerebral vasogenic oedema [1]. Our patient does not have any one of the known risk factor for CIE; however, the recent subarachnoid haemorrhage could have contributed to the BBB injury, causing endothelial cell damage [3].

CIE has been reported following angiography of various vascular territories (head and neck, coronary, thoracic, abdominal, spinal) and following endovascular aneurysm treatment; anyhow, it is more commonly associated with cerebral or carotid angiography.

Many types of iodinated contrast agents are used, and independently of their osmolality or ionic states can cause CIE. There is no limit dose of iodinated contrast related to CIE, but larger doses are considered a risk factor [4].

CIE's most common symptom is cortical blindness, probably due to relatively higher permeability of the BBB in the occipital cortex with respect to other areas [2]. Other

Fig. 1 Brain MRI (a) and MRA (d) showing normal findings; brain CT scan performed 4 h after symptom onset (b, c) showing left cerebral oedema with effacement of the cerebral sulci; brain CT scan performed 2 days after symptom onset showing resolution of cerebral oedema (e, f)

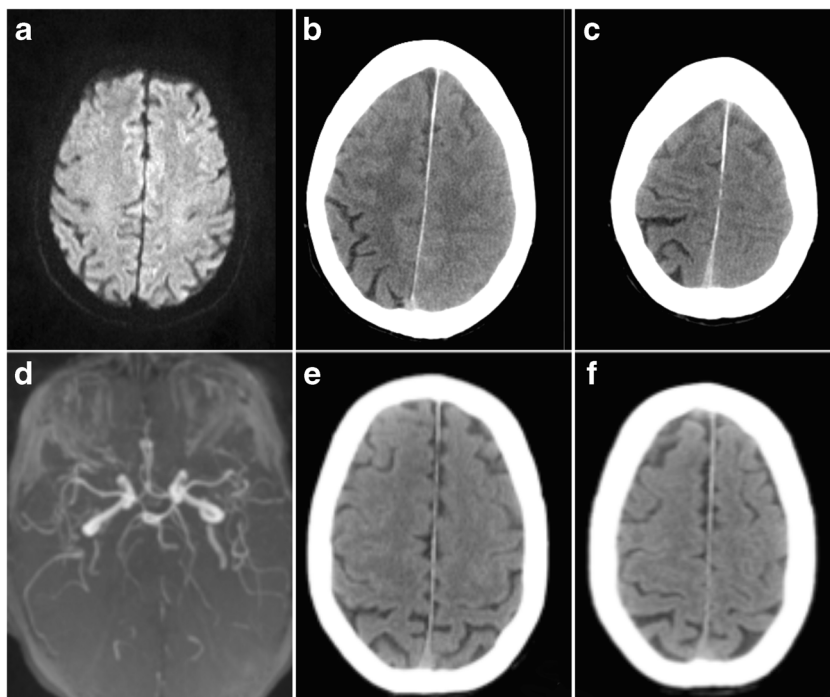


Table 1 Previously reported cases of CIE mimicking anterior circulation strokes

Study	Sex	Age	Procedure	Risk factors	Previous angiography	Contrast agent	Volume (ml)	Clinical presentation	Imaging involvement	Clinical resolution
Utz et al.	F	74	Abdominal aorta and renal artery angiography + angioplasty	Renal impairment; hypertension	No	Diatrizoate meglumine	250	Cortical blindness, left hemiparesis	CT bilateral occipital, basal ganglia alterations	4–5 days
Lantos	M	64	Carotid artery and aorta angiography	Hypertension	No	Iothalamate meglumine	12	Cortical blindness, fluent aphasia	CT left temporo-parieto-occipital alterations	3 days
Eckel et al.	F	71	Spinal angiography	-	No	Ioxaglate	360	Right-sided visual neglect and Wernicke's aphasia	CT bilateral occipital and left parietal lobe alterations	4 days
Vranckx et al.	M	68	Coronary angiography + PCI	Hypertension	Yes	Iohexol	180	Cortical blindness, aphasia, amnesia, periodic alternating gaze with nystagmus	CT contrast enhancement of occipital lobes, temporal lobes, thalami. MRI T2-hyperintensities at both thalami, occipital lobes and cerebellar hemispheres	6 days (permanence of retrograde amnesia)
Dangas et al.	M	82	Carotid artery angiography + stenting	Hypertension	Yes	Ioxaglate	50	Confusion, left hemiparesis, neglect	CT right frontoparietal cortical enhancement and oedema	2 days
Zwicker Sila	F	52	Coronary angiography + coronary stenting	-	Yes	Ioversol (Optiray)	280	Visual loss, headache, confusion, right pronator drift and aphasia	CT bilateral frontal and parieto-occipital attenuation of the cortex and mild loss of sulci. MRI DWI punctate abnormalities in the left frontal region, right frontoparietal area and cerebellum	1, 5 days
Foltys et al.	M	82	Coronary angiography + internal mammary artery graft	Chronic kidney disease; hypertension	N/A	Iopromide	130	Right-sided hemiparesis, aphasia	Cerebral oedema and extravascularly localized contrast media left hemisphere	6 h
Velden et al.	F	82	Coronary angiography + PCI	Chronic kidney disease; hypertension	N/A	Iomeprol	500	Aphasia, right-sided hemiparesis	CT hyperdensities filling the sulci of both cerebral hemispheres	40 h
Uchiyama et al.	M	72	Carotid artery angiography + coiling anterior aneurysm	-	No	Iopamidol	260	Right hemiparesis and motor aphasia	CT enhancement throughout the left cerebral cortex and left basal ganglia, diffuse swelling of the left cerebral hemisphere	7 days
Fang et al.	M	80	Carotid and coronary angiography + stenting	Hypertension	No	Iohexol	250	Right hemiparesis	CT left frontoparietal-occipital cortical enhancement	2 days
Guimaraens et al.	M	51	Carotid artery angiography + right internal carotid artery, aneurysm coiling	Hypertension	No	Iopromide	300	Gerstmann's left visual field deficit, hemiparesis, right gaze deviation	CT cortical enhancement and oedema in the right cerebral hemisphere	2 days
	F	70	Coronary angiography + PCI	Hypertension	N/A	Iopromide	N/A			72 h

Table 1 (continued)

Study	Sex	Age	Procedure	Risk factors	Previous angiography	Contrast agent	Volume (ml)	Clinical presentation	Imaging involvement	Clinical resolution
Wilezewska et al.								Left-sided hemiparesis, conjugate gaze deviation to the right	CT hyperdensity of cerebral sulci and right frontal lobe	
Gurer et al.	M	69	Coronary angiography + PCI	-	N/A	Iohexol	100	Stupor, disorientation, left hemiplegia	CT diffuse hyperdense lesion in the right frontoparietal region and two hyperdense lesions in the right parietal lobe and the right basal ganglia	6 h
Chisci et al.	F	76	Carotid and coronary angiography + PCI + carotid artery stenting	Chronic kidney disease	N/A	Iodixanol	300	Stupor, aphasia, hemiparesis	Hyperdensity of cerebral sulci and subarachnoid spaces	48 h
Liao et al.	F	76	Coronary angiography	Hypertension	No	Ioversol	150	Consciousness disturbance, global aphasia, cortical blindness, right-sided weakness	MRI hyperintensity high Frontoparietal regions	48 h
Ruiz-Salas et al.	M	69	Coronary angiography + PCI	Hypertension	N/A	N/A	N/A	Aphasia, left-sided hemiparesis	CT contrast enhancement of right cerebral hemisphere	12 h
Spina et al.	M	65	Coronary angiography	Hypertension	Yes	Iopromide	110	Global aphasia, bilateral limb weakness	Normal (CT, MRI)	24 h
Chen et al.	F	39	Intra-carotid sodium amobarbital procedure (Wada test)	-	N/A	Iopamidol	N/A	Decrease in consciousness and right hemiplegia	MRI left hemispheric oedema	14 days
Donepudi et al.	F	73	Aortic angiography + thoracic aortic aneurysm repair	Chronic kidney disease; hypertension	Yes	Iodixanol	248	Seizure and left-sided hemiplegia	CT abnormal hyperdensity and extensive enhancement of the right cortex, subarachnoid space and basal ganglia	7 days
Onishi et al.	F	67	Cerebral angiography + anterior choroïdal artery and posterior communicating artery aneurysms coil embolization	Hypertension	Yes	N/A	N/A	Right-sided hemiparesis and aphasia	CT cortical oedema of the left cerebral hemisphere and contrast agent leakage to the subarachnoid space	24 h
Present case	F	56	Cerebral angiography	-	Yes	Iomeprol	70	Global aphasia and right hemiplegia	CT left cerebral oedema with effacement of the cerebral sulci	10 days

PCI percutaneous coronary intervention

neurological symptoms, including hemiparesis or hemiplegia, speech disturbance, loss of coordination, confusion, seizure and coma, are rare [1]. Persistent deficits and fatal encephalopathy have been rarely reported [1, 5].

Utz reported the first case involving also the anterior circulation in 1988: A patient developed cortical blindness and left hemiparesis as a complication of the abdominal aorta and renal artery angiography with angioplasty [6]. To our knowledge, only 20 cases previously reported global aphasia and/or hemiplegia or mimicked anterior circulation strokes [7–26] (Table 1).

The median age of these reported cases is 68.5 years (range 39–82), without prevalence of sex. Arterial hypertension is the most common risk factor being present in 67% of patients, 24% present chronic kidney disease. In the majority of patients, aphasia, hemiparesis/hemiplegia or the combination of two symptoms are reported. Clinical resolution is variable from hours to 14 days, more frequently within 4–5 days. No patient died, and clinical sequelae are described only in one patient (retrograde amnesia).

Interestingly, recurrent CIE was described after a new exposure to iodinated contrast [23] in some patients, whereas in other cases, re-injection of contrast medium did not lead to any consequence [27, 28]. The unknown risk of recurrence may represent significant trouble in the management of such patients. Our patient has two potentially treatable aneurysms, so it is crucial to decide the adequate approach considering the risk of CIE recurrence. In our case, after a collegial discussion, we have decided to postpone the treatment of the residual aneurysms, performing a brain MRI with MR angiography in a month. Since the radiological picture was stable, we decided not to treat the patient, continuing with strict follow-up to evaluate a possible neuroradiological or surgical approach.

In conclusion, CIE is a rare complication of endovascular procedures due to iodinated contrast extravasation. The low frequency and the variable presentation of this event make the diagnosis difficult. The only way to exclude alternative diagnoses is a prompt brain imaging, crucial to recognize the treatable causes. In a few cases of CIE, permanent neurological dysfunctions may occur; the risk/benefit ratio in rechallenging patients with iodinated contrast must be carefully evaluated, in particular in patients having presented the first episode of CIE.

Author contributions All authors approved the contents of the manuscript and validated the accuracy of the data.

Compliance with ethical standards

Conflict of interest The authors declare that they have no conflict of interest.

Ethical approval Not applicable

Informed consent Not applicable

References

1. Leong S, Fanning NF (2012) Persistent neurological deficit from iodinated contrast encephalopathy following intracranial aneurysm coiling. A case report and review of the literature. *Interv Neuroradiol* 18:33–41
2. Spina R, Simon N, Markus R, Muller DWM, Kathir K (2017) Contrast-induced encephalopathy following cardiac catheterization. *Catheter Cardiovasc Interv* 90:257–268
3. Peeyush Kumar T, McBride DW, Dash PK et al (2019) Endothelial cell dysfunction and injury in subarachnoid hemorrhage. *Mol Neurobiol* 56:1992–2006
4. Yu J, Dangas G (2011) Commentary: new insights into the risk factors of contrast-induced encephalopathy. *J Endovasc Ther* 18: 545–546
5. Zhao W, Zhang J, Song Y, Sun L, Zheng M, Yin H, Zhang J, Wang W, Han J (2019) Irreversible fatal contrast-induced encephalopathy: a case report. *BMC Neurol* 19:46
6. Fischer-Williams M, Gottschalk P, Browell J (1970) Transient cortical blindness: an unusual complication of coronary angiography. *Neurology* 20:353–355
7. Utz R, Ekholm SE, Isaac L, Sands M, Fonte D (1988) Local blood-brain barrier penetration following systemic contrast medium administration. A case report and an experimental study. *Acta Radiol* 29:237–242
8. Lantos G (1989) Cortical blindness due to osmotic disruption of the blood-brain barrier by angiographic contrast material: CT and MRI studies. *Neurology* 39:567–571
9. Eckel TS, Breiter SN, Monsein LH (1998) Subarachnoid contrast enhancement after spinal angiography mimicking diffuse subarachnoid hemorrhage. *Am J Roentgenol* 170:503–505
10. Vranckx P, Ysewijn T, Wilms G, Heidbüchel H, Herregods MC, Desmet W (1999) Acute posterior cerebral circulation syndrome accompanied by serious cardiac rhythm disturbances: a rare but reversible complication following bypass graft angiography. *Catheter Cardiovasc Interv* 48:397–401
11. Dangas G, Monsein LH, laureno R, et al. (2001) Transient contrast encephalopathy after carotid artery stenting. *J Endovasc Ther* 8: 111–113
12. Zwicker JC, Sila CA (2002) MRI findings in a case of transient cortical blindness after cardiac catheterization. *Catheter Cardiovasc Interv* 57:47–49
13. Foltys H, Krings T, Block F (2003) Cerebral contrast medium extravasation after coronary angioplasty. *Nervenarzt* 74:892–895
14. Velden J, Milz P, Winkler F, Seelos K, Hamann GF (2003) Nonionic contrast neurotoxicity after coronary angiography mimicking subarachnoid hemorrhage. *Eur Neurol* 49:249–251
15. Uchiyama Y, Abe T, Hirohata M, Tanaka N, Kojima K, Nishimura H, Norbash AM, Hayabuchi N (2004) Blood brain-barrier disruption of nonionic iodinated contrast medium following coil embolization of a ruptured intracerebral aneurysm. *Am J Neuroradiol* 25: 1783–1786
16. Fang HY, Kuo YL, Wu CJ (2009) Transient contrast encephalopathy after carotid artery stenting mimicking diffuse subarachnoid hemorrhage: a case report. *Catheter Cardiovasc Interv* 73:123–126
17. Guimaraens L, Vivas E, Fonnegra A, Sola T, Soler L, Balaguer E, Medrano J, Gandolfo C, Casasco A (2010) Transient encephalopathy from angiographic contrast: a rare complication in neurointerventional procedures. *Cardiovasc Intervent Radiol* 33: 383–388

18. Wilczewska R, Kulakowska A, Korneluk-Sadzynska A et al (2010) Transient neurological deficit due to neurotoxicity of contrast medium used for coronary angiography. *Aktualn Neurol* 10:172–175
19. Gurer B, Yilmaz ER, Kahveci R, Sekerci Z (2011) Non-ionic contrast media neurotoxicity mimicking intracerebral hematoma. *Acta Neurochir* 153:419–420
20. Chisci E, Setacci F, Donato G, de Setacci C (2011) A case of contrast-induced encephalopathy using iodixanol. *J Endovasc Ther* 18:540–544
21. Liao MT, Lin TT, Lin YL et al (2013) Contrast-induced encephalopathy after percutaneous coronary intervention. *Acta Cardiol Sin* 29:277–280
22. Ruiz-Salas A, Navarro-Arce I, Sempere-Fernandez JF (2014) Contrast-induced transitory encephalopathy after coronariography that simulated a subarachnoid haemorrhage. *Rev Esp Anestesiol Reanim* 61:112–118
23. Spina R, Simon N, Markus R, Muller DWM, Kathir K (2017) Recurrent contrast-induced encephalopathy following coronary angiography. *Intern Med J* 47:221–224
24. Chen K, Obaid S, Guillon-Létourneau L, Nguyen DK (2017) Iodinated contrast encephalopathy. *Can J Neurol Sci* 44:432–433
25. Donepudi B, Trottier S (2018) A seizure and hemiplegia following contrast exposure: understanding contrast-induced encephalopathy. *Case Rep Med* 2018:9278526
26. Onishi S, Sakamoto S, Okazaki T, Kurisu K (2018) Iodinated contrast encephalopathy after coil embolisation of unruptured aneurysms. *Asian J Neurosurg* 13:858–860
27. Kinn RM, Breisblatt WM (1991) Cortical blindness after coronary angiography: a rare but reversible complication. *Catheter Cardiovasc Diagn* 22:177–179
28. Rama BN, Pagano TV, DelCore M, Knobel KR, Lee J (1993) Cortical blindness after cardiac catheterization: effect of rechallenge with dye. *Catheter Cardiovasc Diagn* 28:149–151

Publisher's note Springer Nature remains neutral with regard to jurisdictional claims in published maps and institutional affiliations.