



A unique finding of the basilar artery

Raja Gnanadev¹ · Joe Iwanaga² · Marios Loukas¹ · R. Shane Tubbs^{1,2,4,5} · Christoph J. Griessenauer³

Received: 16 September 2020 / Accepted: 20 October 2020
© Springer-Verlag France SAS, part of Springer Nature 2020

Abstract

Variants of the posterior intracranial circulation are important for surgeon, interventionalists and radiologists. Herein, a unique configuration of the basilar artery is reported. A 54-year-old man with a history of COPD, hypothyroidism, smoking, and hyperlipidemia presented to an outside institution with nausea, confusion, altered mental status, and ataxia. The patient was evaluated for stroke. Imaging revealed rotation of the basilar apex of 180 degrees, fetal configuration of the posterior communicating artery, right posterior cerebral artery filling from the left vertebral artery, and duplication of the left and right superior cerebellar arteries. The patient continued to deteriorate neurologically and MRI revealed multifocal and symmetric signal abnormalities in the brain stem, thalami, basal ganglia, and hippocampi. The differential diagnosis included acute disseminated myeloencephalitis. Despite plasma exchange and steroid therapy, the patient died a few days later. This case report demonstrates a rare variation of the basilar apex.

Keywords Posterior intracranial circulation · Basilar artery · Vertebral artery · Stroke · Anatomy

Introduction

The basilar artery is formed by the anastomosis of the vertebral arteries along the anterior midline of the brain stem at the pontomedullary border. Distally, the basilar artery gives rise to pontine branches, the anterior inferior cerebellar arteries, and the superior cerebellar artery. Although typically a branch of the anterior inferior cerebellar artery, the labyrinthine can also originate from the basilar artery [13, 15].

Most often discovered by computed tomography (CT) angiography (CTA) in patients presenting with acute

cerebrovascular problems, variants in vertebrobasilar circulation are common [2]. In Riggs and Rupp's 1963 study on arterial variants of the brain, 79% of specimens studied exhibited variation of the classic anatomy [10]. The most common variants in vertebrobasilar circulation are related to the complexity of the embryology of the intracerebral circulation, particularly at the vertebrobasilar junction [4].

In this case report, we present a patient presenting with stroke-like symptoms and found to have multiple variants of the arterial vasculature of the brain including what we believe to be a unique configuration of the basilar apex.

Case presentation

A 54-year-old man with a history of COPD, hypothyroidism, smoking, and hyperlipidemia presented to an outside institution with nausea, altered mental status, and ataxia. He rapidly deteriorated neurologically to a GCS of 6 with withdrawal of both lower extremities and subsequently, required intubation. He was transferred for concern of posterior circulation stroke and underwent emergent diagnostic digital subtraction angiography for possible mechanical thrombectomy. No large vessel occlusion was visualized. The basilar apex was found to be rotated 180 degrees. In addition, the patient had a fetal configuration of the posterior

✉ Joe Iwanaga
iwanagajoeca@gmail.com

¹ Department of Anatomical Sciences, St. George's University, St. George's, Grenada

² Department of Neurosurgery, Tulane Center for Clinical Neurosciences, Tulane University School of Medicine, 131 S. Robertson St. Suite 1300, New Orleans, LA 70112, USA

³ Neuroscience Institute, Geisinger Medical Center, Danville, PA, USA

⁴ Department of Neurosurgery and Ochsner Neuroscience Institute, Ochsner Health System, New Orleans, LA, USA

⁵ Department of Structural and Cellular Biology, Tulane University School of Medicine, New Orleans, LA, USA

communicating artery, a right posterior cerebral artery filling from the left vertebral artery, and duplication of the left and right superior cerebellar arteries (Fig. 1). The patient continued to deteriorate neurologically. MRI of the brain showed multifocal and symmetric signal abnormalities in the brain stem, thalami, basal ganglia, and hippocampi. The differential diagnosis included acute disseminated myeloencephalitis. Despite plasma exchange and steroid therapy, the patient passed away just a few days later.

Discussion

Understanding how variants in intracerebral circulation affect disease mechanisms involved in atherosclerosis, aneurysms, and multiple pathologies begins with investigating the embryology. In addition, many genes and associated proteins, many possible polymorphisms, have been found to be involved and include VEGF, VEGFR2, eNOS, HIF-1 α , MMP2, TIMP3, IL-8, CXCR2, and α v and β 3 integrins [11].

The development of cerebral circulation has been shown to begin at 24 days of fetal life (3 mm stage) with the internal carotid arteries forming from both the distal segments of the dorsal aortae and the third brachial arch. By day 28, the superior cerebellar artery, a branch of the basilar artery after development, is complete, forms as the sole source of blood supply for the primitive cerebellum. As the central nervous system continues to develop, hypoxia in the posterior segments stimulates angiogenesis beginning with minor collaterals, eventually forming the basilar artery and

vertebral arteries by day 35 (embryological stages 4–5 mm and 5–8 mm, respectively) [6].

As stated, the variation noted in this CTA include: (1) basilar apex 180 degrees rotation, (2) fetal configuration of posterior communicating artery, (3) right posterior cerebral artery filling on left vertebral artery, (4) duplication of bilateral superior cerebellar arteries. Each of these variations are explored as follows:

Basilar apex rotated 180 degrees

Basilar artery fenestrations are consistently the most common variant noted in the literature [4, 6]. A review of the literature yielded no reports of a full 180 degrees rotation of the basilar artery; however, basilar dolichoectasia and the associated clinical consequences are well documented. In particular, the risk of a cerebrovascular event is of greatest clinical significance [5, 9]. This increased risk has been shown to be related to both atherosclerosis with thrombosis and ischemia [5, 9].

Fetal configuration of the posterior communicating artery

Although typically a relatively small artery acting as a connection between the internal carotid and posterior cerebral artery; this anastomosis makes it the primary connection of the internal carotid artery system and the vertebrobasilar system [3]. Fetal configuration of the posterior communicating artery is a known variant of the Circle of Willis from in

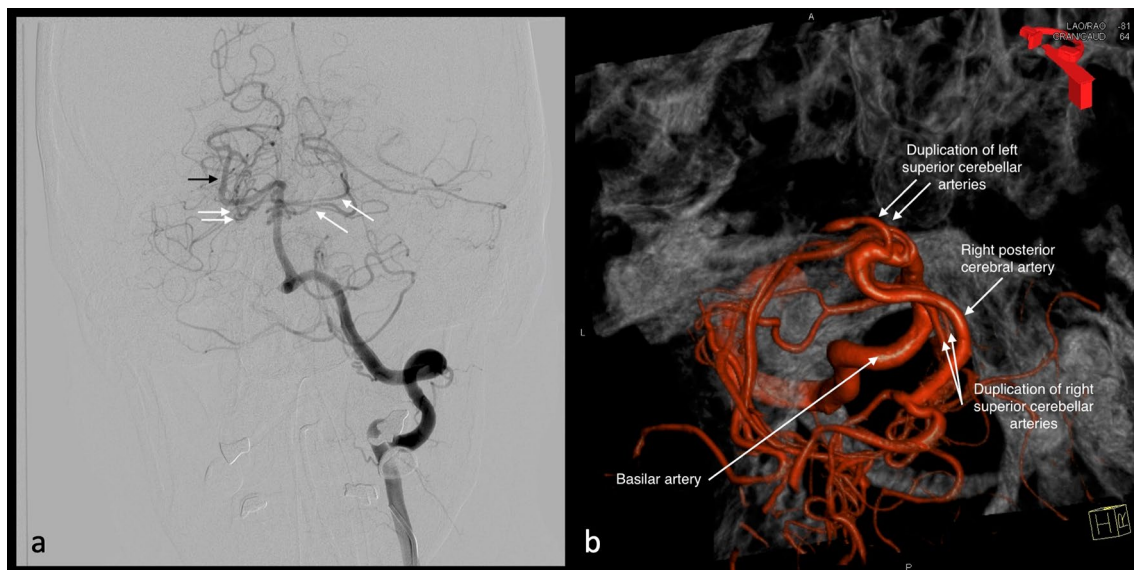


Fig. 1 Rotation of the basilar apex 180 degrees. The left posterior cerebral artery is not visualized because of a fetal configuration of the posterior communicating artery. **a** The right posterior cerebral artery

is filling on the left vertebral artery injection (black arrow). There is duplication of the bilateral superior cerebellar arteries (white arrows). **b** 3D reconstructed image

which the posterior communicating artery retains a caliber similar to the posterior cerebral artery and does not regress as seen in the adult configuration of the posterior communicating artery. Cadaveric studies have demonstrated a prevalence of 12–16.47% of the fetal configuration of the posterior communicating artery [3].

Right posterior cerebral artery filling on left vertebral artery

Typically, the posterior cerebral artery is a branch of the basilar artery from which the posterior communicating artery connects to the internal carotid artery [13]. Known variants of the posterior cerebral artery include fetal posterior cerebral artery, duplicate posterior cerebral artery, and fenestrations [1, 7, 12]. A review of the literature yielded no documented cases of the posterior cerebral artery filling on the contralateral vertebral artery. One may hypothesize; however, that this variant may have survival benefit if a patient suffers from a stroke to the distal basilar artery.

Duplication of bilateral superior cerebellar arteries

Most commonly, the superior cerebellar artery is a branch of the basilar artery that serves to supply the cerebellum [13]. Variations of the superior cerebellar artery are well documented and include both unilateral and bilateral bifurcations, reports of trifurcations, and alternate origins of the superior cerebellar artery such as the internal carotid artery [8, 14]. Previous studies have determined it is variation during embryogenesis of the basilar artery that leads to superior cerebellar artery multiplicities [8]. Superior cerebellar artery multiplicities are thought to be of no clinical significance, however are important to be aware of before any possible regional operation [14].

This case report demonstrates both well documented and rare variations found in the Circle of Willis. Individually each variant provides an opportunity for discussion and this case is remarkable for having four in a single case.

Author contributions RG: data collection, data analysis, and manuscript writing. JI: data analysis, and manuscript writing. ML: data analysis and manuscript editing. RST: protocol/project development and manuscript editing. CJG: protocol/project development, data collection, and manuscript editing.

Funding This research did not receive any specific grant from funding agencies in the public, commercial, or not-for-profit sectors.

Compliance with ethical standards

Conflict of interest The authors declare that they have no conflict of interest.

References

- Coulier B (2018) Duplication of the posterior cerebral artery (PCA) or “true fetal PCA”: an extremely rare variant. *J Belg Soc Radiol* 102:29
- Dimmick SJ, Faulder KC (2009) Normal variants of the cerebral circulation at multidetector CT angiography. *Radiographics* 29:1027–1043
- Gunnal SA, Farooqui MS, Wabale RN (2018) Anatomical variability of the posterior communicating artery. *Asian J Neurosurg* 13:363–369
- Kovač JD, Stanković A, Stanković D, Kovač B, Šaranović D (2014) Intracranial arterial variations: a comprehensive evaluation using CT angiography. *Med Sci Monit* 20:420–427
- Kumral E, Kisabay A, Atac C, Kaya C, Calli C (2005) The mechanism of ischemic stroke in patients with dolichoectatic basilar artery. *Eur J Neurol* 12:437–444
- Menshawi K, Mohr JP, Gutierrez J (2015) A functional perspective on the embryology and anatomy of the cerebral blood supply. *J Stroke* 17:144–158
- Okahara M, Kiyosue H, Mori H, Tanoue S, Sainou M, Nagatomi H (2002) Anatomic variations of the cerebral arteries and their embryology: a pictorial review. *Eur Radiol* 12:2548–2561
- Padmavathi G (2014) Study of the variations of superior cerebellar artery in human cadavers. *Int J Res Med Sci* 2:699–703
- Pico F, Labreuche J, Touboul PJ, Amarenco P (2003) Intracranial arterial dolichoectasia and its relation with atherosclerosis and stroke subtype. *Neurology* 61:1736–1742
- Riggs HE, Rupp C (1963) Variation in form of circle of Willis. The relation of the variations to collateral circulation: anatomic analysis. *Arch Neurol* 8:8–14
- Rogers MS, D’Amato RJ (2012) Common polymorphisms in angiogenesis. *Cold Spring Harb Perspect Med* 2:a006510
- Shaban A, Albright KC, Boehme AK, Martin-Schild S (2013) Circle of willis variants: fetal PCA. *Stroke Res Treat* 2013:105937
- Standring S (2016) *Gray’s anatomy: the anatomical basis of clinical practice*, 41st edn. Elsevier, London
- Uchino A, Sawada A, Takase Y, Kudo S (2003) Variations of the superior cerebellar artery: MR angiographic demonstration. *Radiat Med* 21:235–238
- Wankhede HA, Nimje DA, Hosmani PB (2015) Variations in the branches of basilar artery in adult human cadavers. *J Heal Sci* 2:161–166

Publisher’s Note Springer Nature remains neutral with regard to jurisdictional claims in published maps and institutional affiliations.