

Case Report

Recurrent Cerebral Venous Thrombosis Treated with Direct Oral Anticoagulants in a Japanese Man with Hereditary Protein C Deficiency

Kazuyuki Saito, MD, PhD,* Kazuyuki Ishii, MD,† Konosuke Furuta, MD, PhD,‡
Masaki Kobayashi, MD, PhD,* Yoshiaki Wada, MD, PhD,* and
Eriko Morishita, MD, PhD§

We herein report a case involving a 32-year-old Japanese man with recurrent cerebral venous thrombosis due to hereditary protein C deficiency. He was admitted to our hospital with impaired consciousness. Brain magnetic resonance imaging demonstrated high intensities diffusely along the bilateral sulci and magnetic resonance venography revealed left transverse sinus and superior sagittal sinus stenoses. His father had a history of cerebral infarction and venous thrombosis. The protein C activity level examined by chromogenic synthetic substrate assay was markedly reduced. He was diagnosed with protein C deficiency, and a genetic analysis revealed a heterozygous mutation at exon 3 c.199G>A,p.Glu67Lys on the protein C gene. Four months later, at his second admission, he had transient aphasia, and his protein C activity was under 10%. We switched warfarin to the direct oral anticoagulants edoxaban. He remains fully recovered with no adverse events after the administration of edoxaban for a year. Direct oral anticoagulants may be a new tool for treating cerebral venous thrombosis due to hereditary protein C deficiency.

Key Words: Protein C deficiency—Cerebral venous thrombosis—Magnetic resonance imaging—Direct oral anticoagulants

© 2020 Elsevier Inc. All rights reserved.

Case report

A 32-year-old Japanese man was admitted to our hospital with impaired consciousness. His father had a history of cerebral infarction and venous thrombosis. Brain

From the *Department of Neurology, Nissan Tamagawa Hospital, Seta 4-8-1, Setagaya, Tokyo 158-0095, Japan; †Department of Emergency, Nissan Tamagawa Hospital, Setagaya, Tokyo, Japan; ‡Department of Neurology, Kokura Memorial Hospital, Kitakyushu, Fukuoka, Japan; and §Department of Clinical Laboratory Sciences, Graduate School of Medical Science, Kanazawa University, Kanazawa, Japan.

Received July 29, 2020; revision received September 8, 2020; accepted September 10, 2020.

Address correspondence to Kazuyuki Saito, MD, PhD, Department of Neurology, Nissan Tamagawa Hospital, Seta 4-8-1, Setagaya, Tokyo 158-0095, Japan. E-mail: kaz_saito228@yahoo.co.jp.

1052-3057/\$ - see front matter

© 2020 Elsevier Inc. All rights reserved.

<https://doi.org/10.1016/j.jstrokecerebrovasdis.2020.105320>

magnetic resonance imaging (MRI) demonstrated high intensities along the bilateral sulci on diffusion-weighted imaging and on fluid-attenuated inversion recovery imaging (Fig. 1A, B). Gadolinium contrast T1-weighted imaging demonstrated empty delta sign (Fig. 1C). MR angiography showed right middle cerebral artery occlusion (Fig. 1D), and MR venography revealed defects in the left transverse sinus and superior sagittal sinus (SSS; Fig. 1E). We diagnosed him with cerebral venous thrombosis (CVT) and started heparin sodium and warfarin. The protein S activity (102%; 67-164%) and protein C (PC) antigen (72%; 70-150%) levels were all within normal ranges, although the PC activity level was low at 49% (64-146%) examined by chromogenic synthetic substrate assay. A genetic analysis revealed a heterozygous single-base mutation (G>A) in the codon 199 (glutamic acid to lysine) in the 3rd exon portion of PC gene (*PROC*; Fig. 1I) which was first reported by Reitsma et al. in 1995.¹ MR

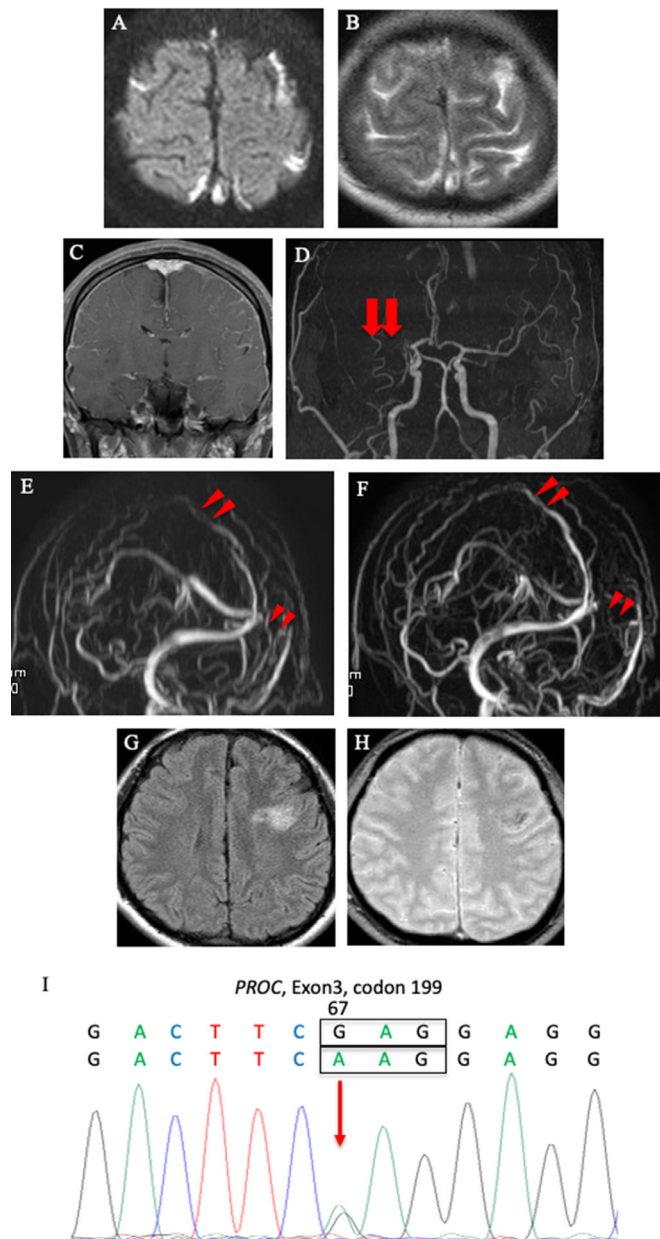


Fig. 1. Brain magnetic resonance imaginings (MRI) (A-E on admission, F at day 20th and G and H at four months from first discharge) and a genetic analysis (I). (A) Diffusion-weighted imaging (DWI) demonstrated high intensities diffusely along the bilateral sulci. (B) Similar findings were found on fluid-attenuated inversion recovery (FLAIR) imaging. (C) Gadolinium contrast enhanced T1-WI demonstrated empty delta sign. (D) MR angiography showed chronic right middle cerebral artery occlusion (MCA) with collateral circulation (arrows). (E) MR venography revealed defect in the left transverse sinus and SSS (arrowheads). (F) Re-examination of MR venography showed improvement in the SSS blood flow but not in the left transverse sinus at day 20th (arrowheads). A new lesion appeared in the left frontal lobe with the edematous change and hemorrhagic change on FLAIR imaging (G) and T2* (H) at 2nd admission. (I) A genetic analysis revealed heterozygous mutation at exon 3c.199G>A, p.Glu67Lys on PROC.

venography showed improvement in the SSS blood flow at day 20th (Fig. 1F). Transient aphasia appeared four months later. Brain MRI showed edematous hemorrhagic change in the left frontal lobe (Fig. 1G, H) and the PC activity level revealed under 10%. We switched warfarin to a direct oral anticoagulants (DOACs), edoxaban (60 mg/day). He remains fully recovered after the administration of edoxaban for a year.

Discussion

Heterozygous PC deficiency occurs in 0.14-0.50% of the general population and in up to 9% of patients (<70 years old) with VT.² The 2016 guidelines on antithrombotic therapy for the acute treatment of VT prefer DOACs to vitamin K antagonist.³ Positive outcomes have been reported for the use of DOACs, especially Xa inhibitors in

inherited thrombophilia.^{4–9} A four-year old male with PC deficiency was switched warfarin to edoxaban (mg/kg) in the development of purpura fulminans. He was successfully managed over two years.⁹ Edoxaban was noninferior to warfarin for the treatment with VT, but the existence of PC deficiency patients was unknown.¹⁰ It is well known that PC activity show falsely raised even in the method of synthetic substrate assay treated with DOACs, careful consideration is needed. Further evidence supporting the widespread use of DOACs for VT with inherited thrombophilia is needed.

In conclusion, DOACs may be a new tool for the treatment of CVT due to PC deficiency.

Declaration of Competing Interest

The authors state that they have no conflicts of interest (COIs).

References

1. Reitsma PH, Bernardi F, Dolg RG, Gandrille S, Greengard JS, et al. Protein C deficiency: a database of mutations, 1995 update. On behalf of the subcommittee in plasma coagulation inhibitors of the scientific and standardization committee of the ISTH. *Thromb Haemost* 1995;73: 876-889.
2. Khor B, Cott MV. Laboratory tests for protein C deficiency. *Am J Hematol* 2010;85:440-442.
3. Kearon C, Akl EA, Ornelas J, Blaivas A, et al. Antithrombotic therapy for VTE disease. CHEST guideline and expert panel report. *Chest* 2016;149:315-352.
4. Skelley JW, White CW, Thomason AR. The use of oral anticoagulants in inherited thrombophilia. *J Thromb Thrombol* 2017;43:24-30.
5. Martinelli I, Mannucci PM, De Stefano V, et al. Different risks of thrombosis in four coagulation defects associated with inherited thrombophilia: a study of 150 families. *Blood* 1998;92:2353-2358.
6. Hermans C, Eeckhoudt S, Lambert C. Dabigatran etexilate (Pradaxa®) for preventing warfarin-induced skin necrosis in a patient with severe protein C deficiency. *Thromb haemost* 2012;107:1189-1191.
7. Wypasek E, Potaczek DP, Alhenc-Gelas M, et al. PROS1 mutations associated with protein S deficiency in Polish patients with residual vein obstruction on rivaroxaban therapy. *Thromb Res* 2014;134:199-201.
8. Cook RM, Rondina MT, Horton DJ. Rivaroxaban for the long-term treatment of spontaneous ovarian vein thrombosis caused by factor V leiden homozygosity. *Ann Pharm* 2014;48:1055-1060.
9. Watanabe K, Arakawa Y, Yanagi M, et al. Management of severe congenital protein C deficiency with a direct oral anticoagulant, edoxaban: a case report. *Pediatr Blood Cancer* 2019;66:e27686.
10. Buller HR, Decousus H, Grosso MA, et al. Edoxaban versus warfarin for venous thromboembolism. *N Engl J Med* 2013;369:1406-1415.