



# Fabry disease: *GLA* deletion alters a canonical splice site in a family with neuropsychiatric manifestations

Patrícia Varela<sup>1</sup> · Gerson Carvalho<sup>2</sup> · Renan Paulo Martin<sup>1,3</sup> · João Bosco Pesquero<sup>1</sup> 

Received: 12 August 2020 / Accepted: 30 October 2020  
© Springer Science+Business Media, LLC, part of Springer Nature 2020

## Abstract

Fabry disease (FD) is a rare X-linked glycosphingolipidosis caused by mutations in *GLA*, a gene responsible for encoding  $\alpha$ -galactosidase A, an enzyme required for degradation of glycosphingolipids, mainly globotriaosylceramide (Gb3) in all cells of the body. FD patients present a broad spectrum of clinical phenotype and many symptoms are shared with other diseases, making diagnosis challenging. Here we describe a novel *GLA* variant located in the 5' splice site of the intron 3, in four members of a family with neuropsychiatric symptoms. Analysis of the RNA showed the variant promotes alteration of the wild type donor site, affecting splicing and producing two aberrant transcripts. The functional characterization showed absence of enzymatic activity in cells expressing both transcripts, confirming their pathogenicity. The family presents mild signs of FD, as angiokeratoma, cornea verticillata, acroparesthesia, tinnitus, vertigo, as well as accumulation of plasma lyso-Gb3 and urinary Gb3. Interestingly, the man and two women present psychiatric symptoms, as depression or schizophrenia. Although psychiatric illnesses, especially depression, are frequently reported in patients with FD and studies have shown that the hippocampus is an affected brain structure in these patients, it is not clear whether the Gb3 accumulation in the brain is responsible for these symptoms or they are secondary. Therefore, new studies are needed to understand whether the accumulation of Gb3 could produce neuronal alterations leading to psychiatric symptoms.

**Keywords** Fabry disease · Splice site mutation ·  $\alpha$ -Galactosidase A · Psychiatric symptoms, *GLA* gene · Neurological manifestations · Depression · Schizophrenia

## Introduction

Fabry Disease (FD, OMIM # 301500) is a rare and progressive X-linked glycosphingolipidosis. The origin of the disease is attributed to pathogenic mutations in the *GLA*, a gene responsible for encoding the  $\alpha$ -galactosidase A enzyme ( $\alpha$ -Gal A; EC 3.2.1.22). The deficiency or absence of the  $\alpha$ -Gal A results in progressive accumulation of globotriaosylceramide

(Gb3) and other sphingolipids in the lysosomes, mainly in kidney, skin, eyes, heart, and brain (Oliveira and Ferreira 2019). The *GLA* gene spans 12 kb of genomic DNA and is divided into seven coding exons; most pathogenic mutations are located within the exons; however, many variants are also described in introns and splice site regions. Variants located in splice site regions could cause diseases due to change the RNA processing, producing an RNA decay (Sterne-Weiler and Sanford 2014) or a nonfunctional protein, leading to FD (Abramowicz and Gos 2018).

FD presents a broad spectrum of clinical phenotype, classified as classical and non-classical or atypical (Arends et al. 2017). In the classical form, the most common symptoms are acroparasthesia, angiokeratomas, abdominal pain, gastrointestinal, cardiac, renal, and cerebrovascular involvement. The non-classical phenotype usually promotes late onset symptoms and affects only one organ (Oliveira and Ferreira 2019).

Central and peripheral nervous system manifestation, as neuropathic pain, hearing loss, recurrent headache, and as the disease progresses, cerebrovascular symptoms, are

---

Patrícia Varela and Gerson Carvalho contributed equally to this work.

✉ João Bosco Pesquero  
jbpesquero@gmail.com

<sup>1</sup> Center for Research and Molecular Diagnostic of Genetic Diseases – Department of Biophysics, Universidade Federal de São Paulo, Rua Pedro de Toledo, 669 - 9o andar, São Paulo 04039-032, Brazil

<sup>2</sup> Medical Genetics Unit, Hospital de Apoio de Brasília, Brasília, DF, Brazil

<sup>3</sup> McKusick-Nathans Department of Genetic Medicine, Johns Hopkins University School of Medicine, Baltimore, MD, USA

described in FD patients. Stroke is a common manifestation in FD patients, and several mechanisms could be involved in brain vasculopathy, as Gb3 accumulation in the blood vessels endothelium (Moore et al. 2007), changes in blood flow, prothrombotic state (Hilz et al. 2004) and increased reactive oxygen species (Moore et al. 2004).

In addition to cerebrovascular symptoms, neuropsychiatric symptoms are often described in FD, with depression being the most reported disorder, affecting 15 to 62% of patients (Wang et al. 2007; Crosbie et al. 2009; Schermuly et al. 2011; Laney et al. 2013; Bolsover et al. 2014; Löhle et al. 2015; Körver et al. 2020). Other disorders, such as psychoses, although rare, are also reported in patients with FD (Liston et al. 1973; Shen et al. 2007; Segal et al. 2010; Schermuly et al. 2011; Sawada et al. 2015).

Studies have shown that in the brain, the accumulation of Gb3 is not restricted to vessels, but also occurs in brain regions as the dorsal motor nucleus of the vagus, substantia nigra, neocortex, hippocampus (Okeda and Nisihara 2008), brainstem, amygdala, hypothalamus and entorhinal cortex (deVeber et al. 1992). Furthermore, a study with (include),  $\alpha$ -Gal A deficient mice showed a neuropathological and neurodegenerative phenotype associated with the disruption of the autophagy-lysosome pathway, in cerebellum, pons, hippocampus and cortex (Nelson et al. 2014). Some of these areas are known to be affected in neurodegenerative and neuropsychiatric diseases (Wise et al. 2017; Kalmady et al. 2017; Santos et al. 2018; Barch et al. 2019; Chen et al. 2019), indicating that neuropsychiatric symptoms found in patients with FD may be due to the accumulation of Gb3 in specific regions of the brain. However, the pathophysiological basis of FD in the central nervous system are poorly understood and it is a matter of debate whether psychiatric symptoms are caused by the disease or if are a causality. In this study, we report the molecular and functional analysis of a novel *GLA* mutation found in two-generation family present neuropsychiatric manifestations, such as depression and schizophrenia.

## Methods

### Patients

We analyzed four members of a two-generation family, three women (22, 51, 49 years old) and a young man (18 years old) with suspicion of FD after the identification of cornea verticillata in the index case (Fig. 1a). The Medical Research and Ethical Committee of Universidade Federal de São Paulo approved the research protocols and consent forms used in this study (0585/07 and 0354/18). Written information consent was obtained from all individuals included in this study.

### Sequencing

DNA and RNA were analyzed by Sanger sequencing. To the DNA isolation, peripheral blood samples were collected and genomic DNA was extracted using QIAamp DNA Blood Mini (Qiagen, Hilden, Germany), according to the manufacturer's conditions. The seven exons of *GLA* gene were amplified by polymerase chain reaction (PCR) and each amplicon was purified and sequenced. Sequences were compared with the DNA reference (NG\_007119), confirmed by reverse strand sequencing and analyzed as described by Turaça et al. (2012).

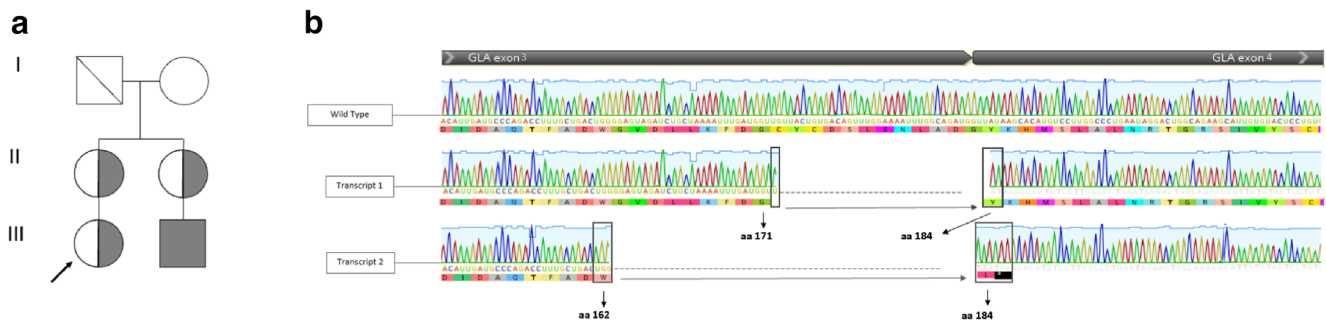
Total RNA was isolated from peripheral blood sample. The extracted RNA was subjected to reverse transcription, and the cDNA was amplified by PCR using specific sense and anti-sense primers. The fragments were purified and sequencing as described by Varela et al. (2019).

### In vitro characterization of the novel mutation

The in vitro characterization was conducted as described by Varela et al. (2020a). Briefly, the human cervical cancer cell line (HeLa, ATCC<sup>®</sup> CCL-2<sup>TM</sup>) were used to the transfection of full-length cDNA sequence encoding human  $\alpha$ -Gal A (NM\_000169) and the mutants. The mutant plasmids were constructed using specific primers (Exxtend Biotechnology, Paulínia, Brazil) for the human *GLA* gene (Transcript 1 - forward 5' TGG GGA GTA GAT CTG CTA AAA TTT GAT GGT TAT AAG CAC ATG TCC TTG GCC CTG AAT AGG A 3' and reverse 5' TCC TAT TCA GGG CCA AGG ACA TGT GCT TAT AAC CAT CAA ATT TTA GCA GAT CTA CTC CCC A 3' / Transcript 2 - forward 5' CGA TTG ATG CCC AGA CCT TTG CTG ACT GGT TAT AAG CAC ATG TCC TTG GCC CTG AAT AG 3' and reverse 5'CTA TTC AGG GCC AAG GAC ATG TGC TTA TAA CCA GTC AGC AAA GGT CTG GGC ATC AAT GTC G 3'). The transfection confirmation was performed by *GLA* expression using quantitative real-time PCR, as described previously by Varela et al. (2020a).

### $\alpha$ -Galactosidase A activity measurement

The protein extraction and enzyme measurement were performed as described by Lukas et al. (2013). The released 4-methylumbelliferone was determined by fluorescence measurement using a fluorometer SpectraMax M2 (Molecular Devices), fluorescence readings were corrected by blanks, and the results were compared to a 4-methylumbelliferone calibration curve (Muller et al. 2010). Enzymatic activities were expressed as micromoles of hydrolyzed substrate per liter of blood per hour ( $\mu\text{mol/L blood/h}$ ).



**Fig. 1** Pedigree and molecular analysis of the RNA. **a** Pedigree of a family with the novel variant c.547 + 1\_547 + 6GTAATG. **b** cDNA sequencing from a wild-type *GLA* transcript and two aberrant transcripts found in the individuals with the mutation found in the intron 3, which produces mRNAs with deletions of part of exon 3. The figure shown, in

the transcript 1 were deleted 36pb, corresponding to amino acids 172 to 183, promoting the shortening of the protein without generate frame-shift (p.Cys172\_Gly183del). In the transcript 2, 62 pb were deleted from the exon 3, the figure shows alteration of the open reading frame, promoting formation of a premature stop codon (p.Trp162\_Gly163insLeufs\*)

## Statistical analysis

All experiments were performed in four separate duplicates in order to confirm the consistency of the results. Statistical evaluation utilized was one-way analyses of variance (ANOVA) with Turkey as *post-hoc*, performed using IBM SPSS® software (version 18). The level of significance was set at  $p < 0.05$ .

## Results

### Clinical features and genetic analysis

The index case was a 22-year-old female patient referred to a geneticist for presenting cornea verticillata. At the clinical evaluation, the presence of mild FD signs as acroparesthesia, tinnitus and vertigo were detected. Laboratory analysis of substrate accumulation was performed and showed accumulation of lyso-Gb3 (6.1 ng/mL – reference <1.8 ng/mL) and urinary Gb3 (60.6 µg/mg – reference <15 µg Gb3/mg creatinine). Clinical and laboratorial data are shown in Table 1.

After clinical and laboratory results, the molecular investigation showed a novel *GLA* deletion in the intron 3 (c.547 + 1\_547 + 6GTAATG); this mutation deleted the canonical donor 5'ss of the intron 3. This variant was not described in the literature and is absent in the consulted population genetic database (gnomAD and ABraOM) (Karczewski et al. 2020; Naslavsky et al. 2017). Therefore, the *in-silico* analysis used to identify splicing motif alteration predicted this variant as probably affecting the splicing (Desmet et al. 2009).

After finding the mutation in the index patient, the family was also analyzed by DNA sequencing, lyso-Gb3, urinary Gb3, and enzymatic assays (for male individual). The mutation, as well as accumulation of lyso-Gb3 and urinary Gb3, was found in the patient's mother, an aunt and a male cousin. The affected male showed  $\alpha$ -Gal A deficiency, presenting an

enzyme activity of 0.06 µmol/L/h (reference >2.2 µmol/L/h). The Fig. 1a show the family pedigree. The index case's mother presents acroparesthesia and major depression since adolescence. Her sister, the index case's aunt, was diagnosed with schizophrenia at the second decade of life; she also presents acroparesthesia; her son was 18 years old at the diagnosis and presents angiokeratoma, acroparaesthesia, and depressed mood. Renal dysfunction and nephrotic proteinuria were not detected. Brain and heart magnetic resonance imaging (MRI) were performed in all individuals and no changes were detected. The family's clinic and laboratorial data are shown in the Table 1.

### RNA analysis

In order to confirm the impact of the novel mutation c.547 + 1\_547 + 6delGTAATG in the mRNA processing, the cDNA from the male affected patient was sequenced. The sequencing showed two transcripts produced from the mutated *GLA*. The transcript 1 presented a deletion of 36 bp (p.Cys172\_Gly183del), this deletion promotes shortening of twelve amino acids in the  $\alpha$ -Gal A protein, without formation of a frame-shift and a premature stop codon (Fig. 1b). In the second transcript (transcript 2) 62 pb were deleted between the amino acids 163 and 183 (p.Trp162\_Gly163insLeu\*). In this transcript, the glycine 163 was exchanged for a leucine and after that, a premature stop codon was formed (Fig. 1b).

### Functional characterization

It is possible to observe that the absence of the canonical 5'ss of intron 3 promoted the formation of two new splice donor sites into exon 3 (Fig. 2a). Even though the shortening of transcript 1 does not change the reading frame, in both transcripts the Cys172 was deleted; this amino acid forms a disulfide bond with Cys142 and both amino acids are part of the  $\alpha$ -Gal A active site (Fig. 2b). Therefore, the deletion of the

**Table 1** Clinical and laboratory characteristics of individuals with novel *GLA* variant

General Information / Symptoms	Patient	Index Case	Mother	Aunt	Cousin
Gender		Female	Female	Female	Male
Age at diagnosis		22 y	51 y	49 y	18 y
Lyso-Gb3		6.1 ng/mL <sup>#</sup>	4.1 ng/mL <sup>#</sup>	3.6 ng/mL <sup>#</sup>	101 ng/mL <sup>##</sup>
Urinary Gb3*		60.6 µg/mg	49.3 µg/mg	33.7 µg/mg	522.8 µg/mg
Enzyme activity (µmol/h/L) **		NA	NA	NA	0.06
Angiokeratoma		+	+	+	+
Cornea verticillata		+	–	–	–
Neurological Symptoms					
Tinnitus		+	–	–	–
Vertigo		+	–	–	–
Acroparaesthesia		+	+	+	+
Depression		–	+	–	+
Psychiatric Symptoms		–	Major Depression	Schizophrenia	Depressed mood

Legend: y = years; (+) presence of symptom; (–) absence of symptom; NA = Not applicable; Lyso-Gb3 analysis were performed in two different laboratories, for <sup>#</sup> the reference value is <1.8 ng/mL and for <sup>##</sup> the reference value is <5.0 ng/mL; \* reference value <15 µg Gb3 / mg creatinine; \*\* reference value: >2.2 µmol/L/h

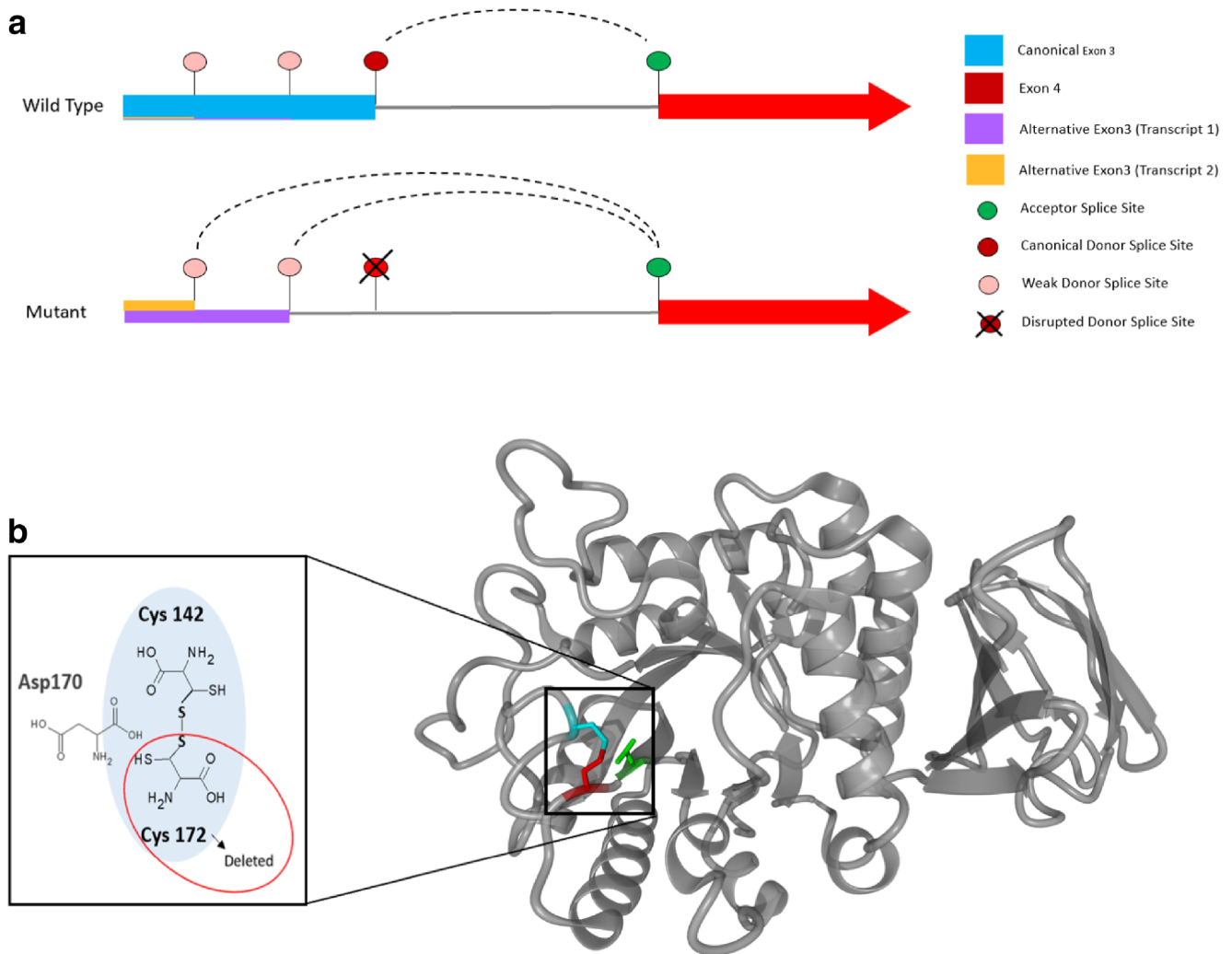
Cys172 could impact the enzymatic function. To confirm the impact on the enzyme, the functional characterization was performed. Both transcripts generated from the mutated mRNA resulting from the splicing error caused by variant c.547 + 1\_547 + 6delGTAATG were produced in vitro by a site directed mutagenesis protocol. *GLA* mRNA levels were measured in the transfected HeLa cells (WT  $\alpha$ -Gal A, transcript 1 and transcript 2) and shown to be increased at least tenfold, when compared to the endogenous *GLA* expression in HeLa cells. We did not observe significant difference between the expression of the *GLA* WT mRNA when compared with the first transcript. However, the second transcript showed higher *GLA* mRNA expression when compared to transcript 1 and WT (Fig. 3a).

The  $\alpha$ -Gal A activity was also evaluated in the HeLa transfected cells (WT, transcript 1 and transcript 2), as well as in cells without transfection. The overexpression of WT *GLA* mRNA led to a sevenfold increase in the  $\alpha$ -Gal A enzymatic activity compared to endogenous  $\alpha$ -Gal A. No difference in  $\alpha$ -Gal A activity was observed in the cells transfected with the transcripts 1 and 2, when compared with endogenous  $\alpha$ -Gal A in HeLa cells. The  $\alpha$ -Gal A activity resulting from transcripts 1 and 2 was normalized to the activity of the wild-type  $\alpha$ -Gal A and did not present any residual activity (Fig. 3b).

## Discussion

Pathogenic mutations in *GLA* gene cause  $\alpha$ -Gal A deficiency and consequently, Gb3 accumulation leading to FD, a rare and multisystemic disorder. To date, the Human Gene Mutation Database described over a thousand variants in the *GLA* of

patients with presumed FD. Several *GLA* variants occur only in one family (Turaça et al. 2012) and even in mutations found in more than one family the pathogenicity of some are still controversial (Varela et al. 2020b). Thus, functional characterization of novel variants is essential to confirm their pathogenicity. In this study, we present a novel splice site mutation found in four members of a family. The mRNA sequencing showed that the deletion of six bases in the 5'ss of the intron 3 created two aberrant transcripts with partial deletion of exon 3. The functional characterization was used to confirm the pathogenicity. The mRNA expression of the transfected cells showed that all plasmids either containing WT *GLA* sequence or both mutated transcripts were super expressed in HeLa cells. However, although transcript 2 had a significantly increased expression in relation to the transcript 1 and WT, the in vitro test showed increase of the  $\alpha$ -Gal A activity only in the WT transfected cells and absence of residual activity in the cells transfected with the two mutated transcripts, confirming alternative transcripts pathogenicity. The disruption of the canonical donor site due to the aforementioned intronic mutation might lead the transcription machinery to use preferentially weak donor splice sites, both located 5' to the canonical one, leading to an exon shrinkage and the formation of these two novel alternative transcripts. Transcript 1 presents a deletion of 36 pb comprising part of exon 3 and two bases of exon 4 (residues 172 to 184). This deletion does not generate a frameshift and premature stop codon, however, the cysteine 172 form a disulfide bond with cysteine 142, the disruption of this bond could lead to an improper formation of the catalytic site, due to their spatial proximity along with the missing of additional residues deleted with the alternative transcript. Variants affecting cysteines that form disulfide bonds are associated



**Fig. 2** The deletion of 5'ss promotes shortening of the exon 3, through the formation of new splicing donor sites. **a** The new variant c.547 + 1\_547 + 6delGTAATG deletes a canonical splicing site; the interruption of the canonical donor site leads the transcription machinery to use preferably weak donor splice sites, located within exon 3, promoting

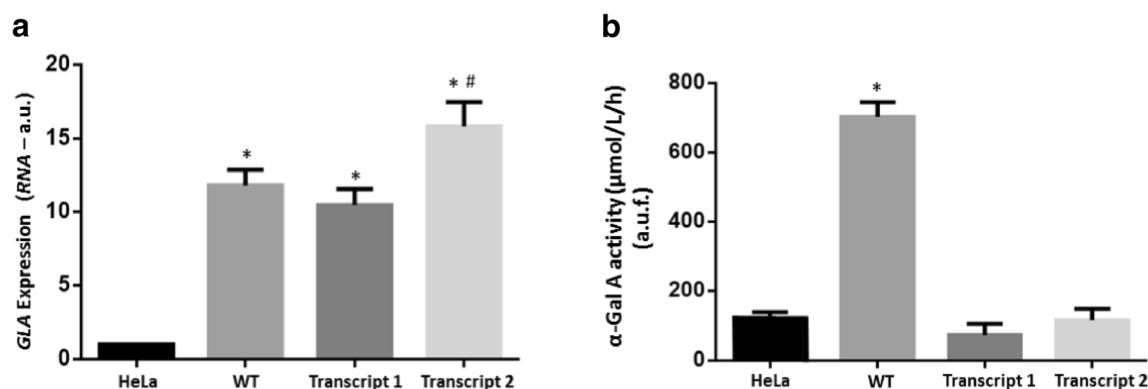
the shortening of the two transcripts. **b** The figure highlights the active site of  $\alpha$ -Gal A enzyme. It is possible to note that the amino acid Cys172, deleted in the two transcripts, is part of the active site of the enzyme and forming a disulfide bond with Cys142

with the classic FD phenotype promoting undetectable or very low residual activity (Ploos van Amstel et al. 1994; Okumiya et al. 1995; Schafer et al. 2005; Shabbeer et al. 2005; Filoni et al. 2010). Transcript 2 (p.Trp162\_Gly163insLeu \*) deletes 62 bp, referring to amino acids 163 to 183. This deletion promotes frame-shift and the formation of a premature stop codon at position 164.

Despite the functional characterization showed that the transcripts formed by the mutation c.547 + 1\_547 + 6delGTAATG do not produce  $\alpha$ -Gal A residual activity, the main signs found in this family were acroparesthesia, tinnitus, cornea verticillata, and psychiatric symptoms; symptoms as renal, heart, or cerebrovascular were not present. In women, mild symptoms could be explained by the random inactivation of the X chromosome that creates a mosaic of cells expressing both the normal or mutant alleles in variable proportions. The

more non-mutated cells are prevalent, the milder and delayed the symptoms will be presented; on the other hand, severe symptoms are more frequent when more mutated cells are prevalent (Juchniewicz et al. 2018). This new variant leads to the absence of enzyme activity and, consequently, to the accumulation of Gb3, therefore men with this mutation will show classic symptoms of FD. Classical phenotype was not observed in this family because the only hemizygote affected is an 18-year-old, and in men the most symptoms as renal and cardiac occur between the second and third decades of life, therefore, he is being monitored periodically.

Interestingly, three members of this family present neuropsychiatric symptom as follows: mother presents depression; aunt presents schizophrenia; and cousin presents depressed mood. It is known that the accumulation of Gb3 found in patients with FD leads to lysosomal dysfunction. According



**Fig. 3** Functional characterization of the transcripts formed from the variant c.547 + 1\_547 + 6delGTAATG. **a** *GLA* mRNA expression in HeLa cells sixty hours after transfection. *GAPDH* gene was used to normalize the expression of *GLA* mRNA. Data are expressed as mean  $\pm$  S.E.M. of  $2^{-\Delta\Delta Ct}$ , which represents the relative expression between *GLA* and *GAPDH*. The figure shows the comparison of the *GLA* expression in HeLa cells (endogenous expression) and the expression in *GLA* WT and *GLA* mutant (Transcript 1 and 2). \* $P < 0.0001$  WT ( $12.1 \pm 0.5$ ,  $N = 4$ ) vs. HeLa ( $1 \pm 0$ ,  $N = 4$ ); Transcript 1 ( $10.5 \pm 0.5$ ,  $N = 4$ ) vs. HeLa;

Transcript 2 ( $15.8 \pm 0.8$ ,  $N = 4$ ) vs. HeLa; # $P = 0.0014$  Transcript 2 vs. Transcript 1; a. u. = arbitrary unit. **b** Enzymatic activity of the  $\alpha$ -Gal A endogenous of HeLa cells compared to the enzymatic activity of WT, transcript 1 and transcript 2 overexpressed HeLa cells. Data are expressed as mean  $\pm$  S.E.M. of the hydrolysis of the fluorescent substrate 4-MU- $\alpha$ -D-galactopyranoside; \* $P < 0.0001$  WT ( $703.2 \pm 18.5$ ,  $N = 4$ ) vs. HeLa ( $120.3 \pm 9.6$ ,  $N = 4$ ), WT vs. Transcript 1 ( $73.9 \pm 15.9$ ,  $N = 4$ ) and WT vs. Transcript 2 ( $116.5 \pm 16.4$ ,  $N = 4$ ). There was no difference between HeLa, Transcript 1 and Transcript 2; u.a.f. = arbitrary unit of fluorescence

to McKenna et al. (2019), lysosomal dysfunction in the brain could change the neurotransmitter homeostasis or promote neurons damage, implicating in the pathophysiology of neurological disease. In fact, neuropsychiatric symptoms, as depression (Wang et al. 2007; Crosbie et al. 2009; Schermuly et al. 2011; Laney et al. 2013; Bolsover et al. 2014; Löhle et al. 2015; Körver et al. 2020), psychosis, hallucinations, delusions, mental confusion, dementia, schizophrenia, behavioral difficulties, and psychomotor retardation are reported in patients with FD (Liston et al. 1973; Shen et al. 2007; Okeda and Nisihara 2008; Segal et al. 2010; Gairing et al. 2011; Schermuly et al. 2011; Sawada et al. 2015).

As reported by the World Health Organization, depression is the most common psychiatric disorder, affecting 322 million people worldwide, which is equivalent to 4.4% of the world population. In contrast, the incidence of schizophrenia is lower, affecting approximately 15 people per 100,000 (McGrath et al. 2004). In FD, depression affects 15 to 62% of patients (Bolsover et al. 2014; Crosbie et al. 2009; Laney et al. 2013; Löhle et al. 2015; Schermuly et al. 2011; Wang et al. 2007); however, the incidence of other psychiatric disorders has not yet been studied. Although frequent, depression has not been a recognized symptom in primary care in at least half of FD patients (Cole et al. 2007). As depression is associated with other medical conditions, it can be neglected, since physicians focus on the primary disease (Hamilton 2006, Cole et al. 2007). Therefore, cases of depression and other psychiatric disorders may be underestimated in patients with FD.

Furthermore, depression has not been seen as a symptom of FD, but as a predictable consequence in patients with an incurable disease, and it has been explained as a response to chronic pain (Cole et al. 2007; Bolsover et al. 2014; Körver et al. 2020) and/or impaired quality of life (Cole et al. 2007; Crosbie et al.

2009). However, some studies have established a relationship between brain involvement and psychiatric symptoms in FD. It is known that the hippocampus is a structure involved in psychiatric illnesses; for example, hippocampal volume deficit is an established finding in both depression and schizophrenia (Wise et al. 2017; Kalmady et al. 2017; Santos et al. 2018; Barch et al. 2019; Chen et al. 2019). Curiously, studies have shown that the hippocampus is an affected structure in FD. A post-mortem study showed the Gb3 accumulation was present in neurons in selective brain areas, including hippocampus (Okeda and Nisihara 2008). Another studied described a disruption of the autophagy-lysosome pathway associated to neuropathology and axonal degeneration in the brain regions, as hippocampus, of  $\alpha$ -Gal A knockout mice (Nelson et al. 2014). In addition, hippocampal atrophy was found in patients with FD (Fellgiebel et al. 2012; Lelieveld et al. 2015). A longitudinal study showed that over a period of eight years there was a decline of approximately 11% in the hippocampal volume in FD patients (Lelieveld et al. 2015). Interestingly, the hippocampal atrophy cannot be explained by the vascular pathology of the disease, suggesting a probable manifestation of neuronal involvement (Fellgiebel et al. 2012; Lelieveld et al. 2015).

In the present family, it was not possible to state that FD is the cause of the psychiatric symptoms. However, as these symptoms are described with more frequency in FD patients and studies point to changes in their hippocampus, further studies are needed to confirm whether the accumulation of Gb3 in neurons could cause neuropsychiatric symptoms.

In summary, here we report a novel *GLA* mutation found in four members of a family. The mutation at the 5'ss produces two alternative non-functional transcripts, leading to accumulation of Lyso-Gb3 and urinary Gb3 in both women and men. The family presents mild neurological symptoms along with

neuropsychiatric symptoms, as depression and schizophrenia, which have not been confirmed as primary or secondary to FD. New in vitro or in vivo studies with neurons and other brain cells are needed to understand if the Gb3 accumulation promotes lysosomal dysfunction in the cells leading to changes in the neurotransmitter homeostasis or neurons damage, causing psychiatric symptoms.

**Acknowledgments** This work was supported by grants from Fundação de Amparo à Pesquisa do Estado de São Paulo (FAPESP 2014/27198-8) and Coordenação de Aperfeiçoamento de Pessoal de Nível Superior - Brasil (CAPES) - Finance Code 001.

**Authors' contributions** PhD. Patricia Varela: conceptualized and designed the study, designed the data collection experiments, drafted the initial manuscript, carried out the analyses, reviewed and revised the manuscript and approved the final manuscript as submitted.

MD. Gerson Carvalho: providing the samples analyzed in this work, analyzed the clinical symptoms of patients, reviewed and revised the manuscript, and approved the final manuscript as submitted.

PhD. Renan Paulo Martin: carried out the initial analyses, reviewed and revised the manuscript and approved the final manuscript as submitted.

PhD. Joao Bosco Pesquero: conceptualized and designed the study, drafted the initial manuscript, carried out the initial analyses, reviewed and revised the manuscript and approved the final manuscript as submitted. Corresponding author and guarantor for the article.

**Funding** This work was supported by grants from Fundação de Amparo à Pesquisa do Estado de São Paulo (FAPESP 2014/27198-8) and Coordenação de Aperfeiçoamento de Pessoal de Nível Superior - Brasil (CAPES) - Finance Code 001.

**Data availability** All data generated or analyzed during this study are included in this published article.

## Compliance with ethical standards

**Competing interests** The authors declare no conflict of interest and confirm independence from the sponsors. The sponsors have not influenced the content of the article.

**Ethical approval and patient consent statement** The Research Ethics Committee of the Federal University of São Paulo, Brazil approved this protocol (0585/07 and 0354/18). All procedures were followed in accordance with the ethical standards of the responsible committee on human experimentation (institutional and national) and with the Helsinki Declaration of 1975, as revised in 2013. All subjects involved in this study were older than 16 year at the time of the study. All four patients gave written informed consent agreeing to participate in the study and for the publication of their clinical cases. The consent was in accordance with the Declaration of Helsinki.

**Code availability** Not applicable.

## References

Abramowicz A, Gos M (2018) Splicing mutations in human genetic disorders: examples, detection, and confirmation. *J Appl Genet* 59: 253–268. <https://doi.org/10.1007/s13353-018-0444-7>

- Arends M, Wanner C, Hughes D, Mehta A, Oder D, Watkinson OT et al (2017) Characterization of classical and nonclassical Fabry disease: a multicenter study. *J Am Soc Nephrol* 28(5):1631–1164. <https://doi.org/10.1681/ASN.2016090964>
- Barch DM, Tillman R, Kelly D, Whalen D, Gilbert K, Luby JL (2019) Hippocampal volume and depression among young children. *Psychiatry Res Neuroimaging* 288:21–28. <https://doi.org/10.1016/j.psychres.2019.04.012>
- Bolsover FE, Murphy E, Cipolotti L, Werring DJ, Lachmann RH (2014) Cognitive dysfunction and depression in Fabry disease: a systematic review. *J Inher Metab Dis* 37(2):177–187. <https://doi.org/10.1007/s10545-013-9643-x>
- Chen F, Bertelsen AB, Holm IE, Nyengaard JR, Rosenberg R, Dorph-Petersen KA (2019) Hippocampal volume and cell number in depression, schizophrenia, and suicide subjects. *Brain Res* 1727: 146546. <https://doi.org/10.1016/j.brainres.2019.146546>
- Cole AL, Lee PJ, Hughes DA, Deegan PB, Waldek S, Lachmann RH (2007) Depression in adults with Fabry disease: a common and under-diagnosed problem. *J Inher Metab Dis* 30(6):943–951. <https://doi.org/10.1007/s10545-007-0708-6>
- Crosbie TW, Packman W, Packman S (2009) Psychological aspects of patients with Fabry disease. *J Inher Metab Dis* 32(6):745–753. <https://doi.org/10.1007/s10545-009-1254-1>
- Desmet FO, Hamroun D, Lalande M, Colod-Beround G, Claustre M, Beround C (2009) Human splicing finder: an online bioinformatics tool to predict splicing signals. *Nucleic Acids Res* 37(9):e67. <https://doi.org/10.1093/nar/gkp215>
- deVeber GA, Schwarting GA, Kolodny EH, Kowall NW (1992) Fabry disease: immunocytochemical characterization of neuronal involvement. *Ann Neurol* 31(4):409–415. <https://doi.org/10.1002/ana.410310410>
- Fellgiebel A, Wolf DO, Kolodny E, Müller MJ (2012) Hippocampal atrophy as a surrogate of neuronal involvement in Fabry disease. *J Inher Metab Dis* 35(2):363–367. <https://doi.org/10.1007/s10545-011-9390-9>
- Filoni C, Caciotti A, Carraresi L, Cavicchi C, Parini R, Antuzzi D et al (2010) Functional studies of new GLA gene mutations leading to conformational Fabry disease. *Biochim Biophys Acta* 1802:247–252. <https://doi.org/10.1016/j.bbdis.2009.11.003>
- Gairing S, Wiest R, Metzler S, Theodoridou A, Hoff P (2011) Fabry's disease and psychosis: causality or coincidence? *Psychopathology* 44(3):201–204. <https://doi.org/10.1159/000322794>
- Hamilton B (2006) State of depression in America. *Depression and Bipolar Support Alliance (DBSA)*. Available online at: <https://www.dbsaalliance.org/pdfs/wpsearchable.pdf>. Accessed 04/11/20
- Hilz MJ, Kolodny EH, Brys M, Stemper B, Haendl T, Marthol H (2004) Reduced cerebral blood flow velocity and impaired cerebral autoregulation in patients with Fabry disease. *J Neurol* 251(5):564–570. <https://doi.org/10.1007/s00415-004-0364-9>
- Juchniewicz P, Kloska A, Tylki-Szymańska A, Jakóbkiewicz-Banecka J, Węgrzyn G et al (2018) Female Fabry disease patients and X-chromosome inactivation. *Gene* 641:259–264. <https://doi.org/10.1016/j.gene.2017.10.064>
- Kalmady SV, Shivakumar V, Arasappa R, Subramaniam A, Gautham S, Venkatasubramanian G et al (2017) Clinical correlates of hippocampus volume and shape in antipsychotic-naïve schizophrenia. *Psychiatry Res Neuroimaging* 263:93–102. <https://doi.org/10.1016/j.psychres.2017.03.014>
- Karczewski KJ, Francioli LC, Tiao G et al (2020) The mutational constraint spectrum quantified from variation in 141,456 humans. *Nature* 581:434–443. <https://doi.org/10.1038/s41586-020-2308-7>
- Körver S, Geurtsen GJ, Hollak CEM, van Schaik IN, Longo MGF, Lima MR et al (2020) Depressive symptoms in Fabry disease: the importance of coping, subjective health perception and pain. *Orphanet Journal of Rare Diseases* 15(1):28. <https://doi.org/10.1186/s13023-020-1307-y>

- Laney DA, Bennett RL, Clarke V, Fox A, Hopkin RJ, Johnson J et al (2013) Fabry disease practice guidelines: recommendations of the National Society of genetic counselors. *J Genet Couns* 22(5):555–564. <https://doi.org/10.1007/s10897-013-9613-3>
- Lielieveld IM, Böttcher A, Hennermann JB, Beck M, Fellgiebel A (2015) Eight-year follow-up of neuropsychiatric symptoms and brain structural changes in Fabry disease. *PLoS One* 10(9):e0137603. <https://doi.org/10.1371/journal.pone.0137603>
- Liston EH, Levine MD, Philippart M (1973) Psychosis in Fabry disease and treatment with phenoxybenzamine. *Arch Gen Psychiatry* 29(3):402–403. <https://doi.org/10.1001/archpsyc.1973.04200030090014>
- Löhle M, Hughes D, Milligan A, Richfield L, Reichmann H, Mehta A et al (2015) Clinical prodromes of neurodegeneration in Anderson-Fabry disease. *Neurology* 84(14):1454–1464. <https://doi.org/10.1212/WNL.0000000000001450>
- Lukas J, Giese AK, Markoff A, Grittner U, Kolodny E, Mascher H et al (2013) Functional characterization of alpha-galactosidase a mutation as a basis for a new classification system in fabry disease. *PLoS Genet* 9(8):e1003632. <https://doi.org/10.1371/journal.pgen.1003632>
- McGrath J, Saha S, Welham J et al (2004) A systematic review of the incidence of schizophrenia: the distribution of rates and the influence of sex, urbanicity, migrant status and methodology. *BMC Med* 2:13. <https://doi.org/10.1186/1741-7015-2-13>
- Mckenna MC, Schuck PF, Ferreira GC (2019) Fundamentals of CNS energy metabolism and alterations in lysosomal storage diseases. *J Neurochem* 148(5):590–599. <https://doi.org/10.1111/jnc.14577>
- Moore DF, Ye F, Brennan ML, Gupta S, Barshop BA, Steiner RD, Rhead WJ, Brady RO et al (2004) Ascorbate decreases Fabry cerebral hyperperfusion suggesting a reactive oxygen species abnormality: an arterial spin tagging study. *J Magn Reson Imaging* 20(4):674–683. <https://doi.org/10.1002/jmri.20162>
- Moore DF, Kaneski CR, Askari H, Schiffmann R (2007) The cerebral vasculopathy of Fabry disease. *J Neurol Sci* 257(1–2):258–263. <https://doi.org/10.1016/j.jns.2007.01.053>
- Muller KB, Rodrigues MDB, Pereira VG, Martins AM, D’Almeida V (2010) Reference values for lysosomal enzyme activities using dried blood spots samples – a Brazilian experience. *Diagn Pathol* 5:65. <https://doi.org/10.1186/1746-1596-5-65>
- Naslavsky MS, Yamamoto GL, de Almeida TF, Ezquina ASM, Sunaga DY, Pho N et al (2017) Exomic variants of an elderly cohort of Brazilians in the ABraOM database. *Hum Mutat* 38(7):751–763. <https://doi.org/10.1002/humu.23220>
- Nelson MP, Tse TE, O’Quinn DB, Percival SM, Jaimes EA, Warnock DG, et al. (2014). Autophagy-lysosome pathway associated neuropathology and axonal degeneration in the brains of alpha-galactosidase A-deficient mice. *Acta Neuropathol Commun*. 2:20. doi: <https://doi.org/10.1186/2051-5960-2-20>
- Okeda R, Nishihara M (2008) An autopsy case of Fabry disease with neuropathological investigation of the pathogenesis of associated dementia. *Neuropathology*. 28(5):532–540. <https://doi.org/10.1111/j.1440-1789.2008.00883.x>
- Okumiya T, Ishii S, Kase R, Kamei S, Sakuraba H, Suzuki Y (1995) Alpha-galactosidase gene mutations in Fabry disease: heterogeneous expressions of mutant enzyme proteins. *Hum Genet* 95:557–561. <https://doi.org/10.1007/BF00223869>
- Oliveira JP, Ferreira S (2019) Multiple phenotypic domains of Fabry disease and their relevance for establishing genotype–phenotype correlations. *Appl Clin Genet* 12:35–50. <https://doi.org/10.2147/TACG.S146022>
- Ploos van Amstel JK, Jansen RP, de Jong JG, Hamel BC, Wevers RA (1994) Six novel mutations in the alpha-galactosidase a gene in families with Fabry disease. *Hum Mol Genet* 3:503–505. <https://doi.org/10.1093/hmg/3.3.503>
- Santos MAO, Bezerra LS, Carvalho A, Brainer-Lima AM (2018) Global hippocampal atrophy in major depressive disorder: a meta-analysis of magnetic resonance imaging studies. *Trends Psychiatry Psychother* 40(4):369–378. <https://doi.org/10.1590/2237-6089-2017-0130>
- Sawada J, Katayama T, Kano K, Asanome A, Takahashi K, Saito T et al (2015) A sporadic case of Fabry disease involving repeated fever, psychiatric symptoms, headache, and ischemic stroke in an adult Japanese woman. *Intern Med* 54(23):3069–3074. <https://doi.org/10.2169/intermalmedicine.54.4719>
- Schafer E, Baron K, Widmer U, Deegan P, Neumann HP, Sunder-Plassmann G et al (2005) Thirty-four novel mutations of the GLA gene in 121 patients with Fabry disease. *Hum Mutat* 25:412. <https://doi.org/10.1002/humu.9327>
- Schemuly I, Müller MJ, Müller KM, Albrecht J, Keller I, Yakushev I et al (2011) Neuropsychiatric symptoms and brain structural alterations in Fabry disease. *Eur J Neurol* 18(2):347–353. <https://doi.org/10.1111/j.1468-1331.2010.03155.x>
- Segal P, Kohn Y, Pollak Y, Altarescu G, Galili-Weisstub E, Raas-Rothschild A (2010) Psychiatric and cognitive profile in Anderson-Fabry patients: a preliminary study. *J Inherit Metab Dis* 33(4):429–436. <https://doi.org/10.1007/s10545-010-9133-3>
- Shabbeer J, Robinson M, Desnick RJ (2005) Detection of alpha galactosidase a mutations causing Fabry disease by denaturing highperformance liquid chromatography. *Hum Mutat* 25(3):299–305. <https://doi.org/10.1002/humu.20144>
- Shen YC, Haw-Ming L, Lin CC, Chen CH (2007) Psychosis in a patient with Fabry's disease and treatment with aripiprazole. *Prog Neuro-Psychopharmacol Biol Psychiatry* 31(3):779–780. <https://doi.org/10.1016/j.pnpbp.2006.11.017>
- Sterne-Weiler T, Sanford JR (2014) Exon identity crisis: disease-causing mutations that disrupt the splicing code. *Genome Biol* 15(1):201. <https://doi.org/10.1186/gb4150>
- Turaça LT, Pessoa JG, Motta FL, Muñoz Rojas MV, Müller KB et al (2012) New mutations in the GLA gene in Brazilian families with Fabry disease. *J Hum Genet* 57(6):347–351. <https://doi.org/10.1038/jhg.2012.32>
- Varela P, Caldas MM, Pesquero JB (2019) Novel GLA mutation promotes intron inclusion leading to Fabry disease. *Front Genet* 10:783. <https://doi.org/10.3389/fgene.2019.00783>
- Varela P, Mastroianni-Kirsztajn G, Ferrer H, Aranda C, Wallbach K, Ferreira da Mata G et al (2020a) Functional characterization and pharmacological evaluation of a novel GLA missense mutation found in a severely affected Fabry disease family. *Nephron*. 144(3):147–155. <https://doi.org/10.1159/000503998>
- Varela P, Mastroianni-Kirsztajn G, Motta FL, Martin RP, Turaça LT, Ferrer HLF et al (2020b) Correlation between GLA variants and alpha-galactosidase a profile in dried blood spot: an observational study in Brazilian patients. *Orphanet J Rare Dis* 15(1):30. <https://doi.org/10.1186/s13023-019-1274-3>
- Wang, R.Y., Lelis, A., Mirocha, J., Wilcox, W.R. (2007). Heterozygous Fabry women are not just carriers, but have a significant burden of disease and impaired quality of life. *Genet Med*:9(1):34–45. doi: <https://doi.org/10.1097/gim.0b013e31802d8321>
- Wise T, Radua J, Via E, Cardoner N, Abe O, Adams TM et al (2017) Common and distinct patterns of grey-matter volume alteration in major depression and bipolar disorder: evidence from voxel-based meta-analysis. *Mol Psychiatry* 22:1455–1463. <https://doi.org/10.1038/mp.2016.72>

**Publisher's note** Springer Nature remains neutral with regard to jurisdictional claims in published maps and institutional affiliations.