

A Rare Case of Capgras Syndrome in Moyamoya Disease

Kazuma Koda, MD, Yoshihisa Otsuka, MD, Yukihiro Yoneda, MD,
Ryo Tsukamoto, MD, and Yasufumi Kageyama, MD

Moyamoya disease is a rare cerebrovascular disorder with unknown etiology and psychiatric symptoms occasionally manifest initially. Capgras syndrome is a unique neuropsychiatric symptom that is a delusional misidentification of a familiar person replaced by an identical imposter. We report the case of a 51-year-old woman with frontal lobe ischemic stroke caused by moyamoya disease, presenting with Capgras syndrome. Dysfunction of frontal areas may be attributable to development of Capgras syndrome.

Key Words: Capgras syndrome—Moyamoya disease—Stroke—Ischemic
© 2020 Elsevier Inc. All rights reserved.

Case description

A 51-year-old woman without past psychiatric history was admitted to our hospital with headache and difficulty in speaking. Neurological examination revealed a transcortical motor aphasia, left-right disorientation, and finger agnosia. There were no motor and sensory deficits. Blood test showed no remarkable findings. Brain diffusion-weighted magnetic resonance imaging and fluid-attenuated inversion recovery imaging demonstrated an acute ischemic lesion in the left frontal area (Fig. 1A,B). Magnetic resonance angiography showed occlusive lesions of bilaterally distal internal carotid arteries (Fig. 1C) and abnormal vascular network in the basal ganglia (Fig. 1D). Brain single-photon emission computed tomography revealed extensive hypoperfusion in the bilateral frontal areas (Fig. 1E). After definite diagnosis of an ischemic stroke in moyamoya disease, anti-thrombotic medication was commenced with oral aspirin and intravenous

argatroban. On the third day, her aphasia began improving. The patient suddenly claimed that her mother had previously died. When the patient listened to her mother's voices on the telephone and met her in the hospital, she repeatedly and consistently described her mother's voice and face as "recording" and "dummy", respectively. Capgras syndrome was diagnosed by a psychiatrist. Anti-psychotic medication with oral quetiapine was commenced, and her symptoms resolved over the next week. Six months after her stroke, left superficial temporal artery-middle cerebral artery bypass surgery was performed.

Discussion

To our knowledge, this is the first case of Capgras syndrome due to moyamoya disease. In adult moyamoya disease¹⁻³ psychiatric symptoms manifest initially, representing 14% of patients.¹ Furthermore, 66% of moyamoya disease patients had widespread cognitive impairments such as memory disturbance, executive dysfunction, and aphasia.¹ Capgras syndrome occurs in functional disorders such as schizophrenia, schizoaffective and bipolar affective disorders, and psychotic depression. In 43% of Capgras syndrome patients, the syndrome develops in organic diseases including dementia, traumatic brain injury, drug related and cerebrovascular diseases.⁴⁻⁸

Neuroanatomical mechanisms of Capgras syndrome have yet to be elucidated. Among 28 patients with organic Capgras syndrome, including 17 with cerebrovascular

From the Department of Neurology, Hyogo Prefectural Amagasaki General Medical Center, Amagasaki City, Japan.

Received June 15, 2020; revision received October 20, 2020; accepted October 25, 2020.

Financial Disclosures: None.

Grant Support: None.

Address correspondence to Yoshihisa Otsuka, MD, Department of Neurology, Hyogo Prefectural Amagasaki General Medical Center 2-17-77 Higashi Naniwa, Amagasaki City, 660-8550, Japan. Tel: +81-6-6480-7000; Fax: +81-6-6480-7001. E-mail: yotsuka@hp.pref.hyogo.jp.

1052-3057/\$ - see front matter

© 2020 Elsevier Inc. All rights reserved.

<https://doi.org/10.1016/j.jstrokecerebrovasdis.2020.105432>

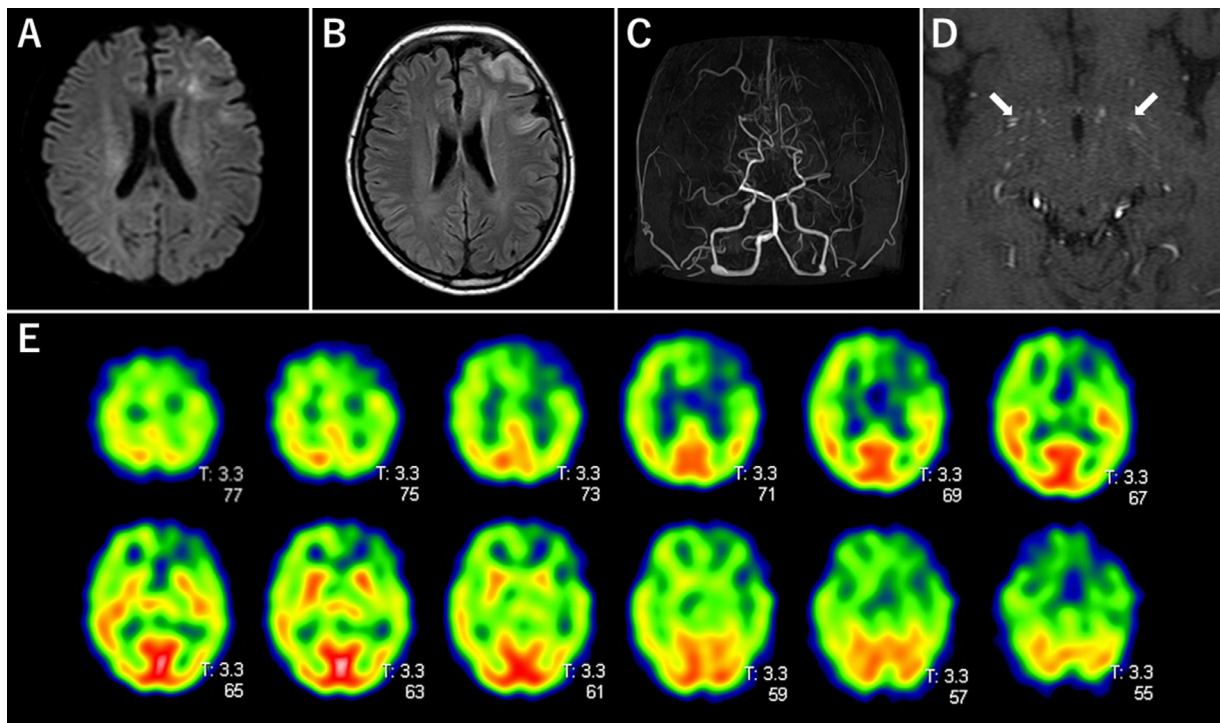


Fig. 1. (A, B) Diffusion-weighted magnetic resonance imaging and fluid-attenuated inversion recovery imaging revealing high-intensity lesions in the left frontal lobe. (C, D) Magnetic resonance angiography showing occlusions of bilateral distal internal carotid arteries and abnormal vascular network in the basal ganglia (arrow). (E) Brain single-photon emission computed tomography revealing left-sided dominant hypoperfusion of bilateral frontal lobes.

accidents,⁷ 18 (64%) patients had right-sided frontal lobe damage. However, some cases with damage on the left have also been reported.⁹ Nagahama et al. found that hypoperfusion of the left hippocampus, insula, ventral striatum, and bilateral inferior frontal gyri is related to misidentification syndromes in Lewy-body dementia, including Capgras syndrome.¹⁰ Thus, they suggested that impaired memory and emotional function—associated with limbic-paralimbic system dysfunction—might explain the misidentification in said dementia.¹⁰ In our patient, direct ischemic damage of the left frontal area and hemodynamic hypoperfusion of bilateral frontal areas due to moyamoya disease may explain the symptoms. Capgras syndrome is commonly treated with antipsychotic or antidepressant medications, with 65% showing a good response,⁴ including our patient who was administered oral quetiapine.

Declarations of Competing Interest

None

References

1. Festa JR, Schwarz LR, Pliskin N, et al. Neurocognitive dysfunction in adult moyamoya disease. *J Neurol* 2010;257:806-815.
2. Araki Y, Takagi Y, Ueda K, et al. Cognitive function of patients with adult moyamoya disease. *J Stroke Cerebrovasc Dis* 2014;23:1789-1794.
3. Richards M, Grzenda A, Nelson E, et al. Psychiatric comorbidity in moyamoya disease and preliminary guidelines for treatment. *Am J Psychiatry* 2019;176:269-274.
4. Pandis C, Agrawal N, Poole N. Capgras' delusion: a systematic review of 255 published cases. *Psychopathology* 2019;52:161-173.
5. Spiegel DR, Laroia R, Samuels D. A possible case of Capgras syndrome after a right anterior cerebral artery cerebrovascular accident treated successfully with mirtazapine. *J Neuropsychiatry Clin Neurosci* 2008;20:494.
6. Sottile F, Bonanno L, Finzi G, et al. Cotard and Capgras syndrome after ischemic stroke. *J Stroke Cerebrovasc Dis* 2015;24:e103-e104.
7. Darby R, Sashank P. Lesion-related delusional misidentification syndromes: a comprehensive review of reported cases. *J Neuropsychiatry Clin Neurosci* 2016;28(3):217-222.
8. Garcha M, Sivakumar K, Leary M, et al. Transient Capgras syndrome secondary to bilateral ischemic stroke: A case report. *Cogn Behav Neurol* 2018;31:96-98.
9. Durani S, Ford R, Sajjad S. Capgras syndrome associated with a frontal lobe tumor. *Ir J Psychol Med* 1991;8:135-136.
10. Nagahama Y, Okina T, Suzuki N, et al. Neural correlates of psychotic symptoms in dementia with Lewy bodies. *Brain* 2010;133:557-567.