

Palliative ketamine: the use of ketamine in central post-stroke pain syndrome—a case report

Rachel Angstadt, Shawn Esperti, Andrew Mangano, Stephen Meyer

Department of Internal Medicine, Grand Strand Health, Myrtle Beach, South Carolina, USA

Correspondence to: Rachel Angstadt, DO (ORCID: 0000-0002-4862-8556). Grand Strand Medical Center, 809 82nd Parkway, Myrtle Beach, South Carolina 29572, USA. Email: Rachel.Angstadt@HCAHealthcare.com.

Abstract: Ketamine has played a versatile role in medicine due to its wide spectrum of uses in history including use in sedation, catalepsy, somatic analgesia, bronchodilation, and recent trial in complex chronic pain syndromes. There is very little, if any, discussion in the literature of ketamine use in stroke, particularly in improving symptoms of pain after stroke. We present a case of a 40-year-old female with a past medical history of right-sided thalamic ischemic stroke complicated by Central post-stroke pain syndrome (CPSP) presented for refractory severe diffuse pain causing debility and immobility. The patient failed outpatient medical therapy consisting of anxiolytics, serotonin, and norepinephrine reuptake inhibitors. This led to increased opioid use which resulted in dependence and opioid-hyperalgesia. Upon admission, the patient was unable to sit still, with severe, sharp 10/10 pain localized to her left lower extremity. Palliative medicine was consulted for management of refractory central neuropathic pain. Inpatient oral ketamine was initiated, and titrated over the patient's hospital course. During this time, the patient showed marked improvement in GAD-7, PHQ-9, and Short McGill pain scores while significantly decreasing opioid requirements. We present this case to demonstrate how oral ketamine usage in centrally mediated neuropathic pain such as in CPSP can lead to pain control, decreased opioid usage, and overall improved quality of life.

Keywords: Central post-stroke pain syndrome (CPSP); case report; ketamine; palliative medicine; thalamic pain syndrome

Submitted Apr 16, 2020. Accepted for publication Aug 28, 2020.

doi: 10.21037/apm-20-972

View this article at: <http://dx.doi.org/10.21037/apm-20-972>

Introduction

Neuropathic pain is the result of disease or injury to the peripheral or central nervous system leading to aberrant activation of pain centers. Over the last decade, there has been an increase in patients debilitated by centrally-mediated chronic neuropathic pain (1). The current mechanism of neuropathic pain is unclear but it is proposed that aberrant nociceptive stimulation leads to upregulation of the NMDA receptor at neuronal synapses (2). This results in amplified and enhanced pain signals manifesting as allodynia, hyperalgesia, and spontaneous pain (2). Medical therapy for chronic neuropathic pain consisting of antidepressants, antiepileptics, and opioids merely masks the pain, with treatment efficacies reportedly around

30–40% (3). We present the following article in accordance with the CARE reporting checklist (available at <http://dx.doi.org/10.21037/apm-20-972>).

Ketamine has played a versatile role in medicine due to its wide spectrum of uses sedation, catalepsy, somatic analgesia, bronchodilation, and recent trial in complex chronic pain syndromes (4,5). Ketamine (CI-581), which was first used in 1965 as general sedation, has gained attention for its potential role in targeted treatment of chronic neuropathic pain through noncompetitive (NMDA) receptor antagonism (4). Case reports have shown successful usage of ketamine for neuropathic pain control while decreasing the need for opioid analgesia and its adverse side effects (2). What is not well documented in the literature is the use of ketamine in post stroke pain. We present a

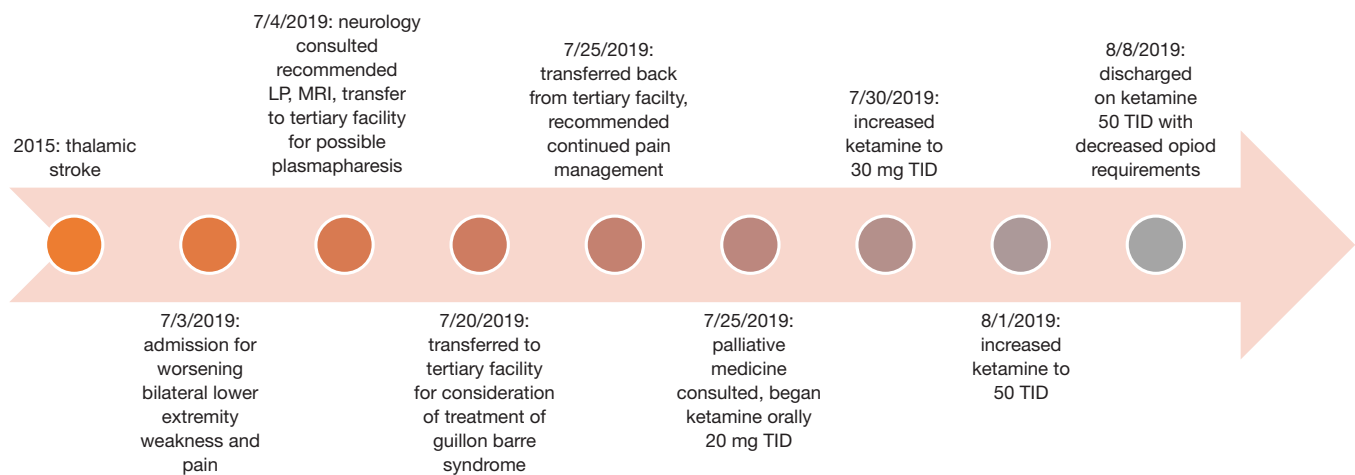


Figure 1 Original created timeline of events.

case of successful utilization of oral ketamine in a patient hospitalized for severe pain crisis from central post-stroke pain syndrome (CPSP).

Case presentation

A 49-year-old female with a 4-year history of chronic pain from (CPSP) after suffering a right thalamic ischemic stroke was admitted to the hospital for acute on chronic pain crisis (*Figure 1*). She had a past medical history of Guillain-Barre Syndrome prior to her stroke. Attempts at physical therapy after her thalamic stroke were limited due to her inability to attend office visits because of debilitating bilateral lower extremity pain. Shortly after her stroke, and with increasing difficulty controlling her chronic neuropathic pain, she was referred to pain management. Pain was inadequately controlled which resulted in frequent pain crisis exacerbations. She developed polypharmacy side effects consisting of sedation, fatigue, and constipation, which resulted in significant functional regression. Baseline functional status declined to a bedridden state with the exception of walker assistance to the bathroom. The patient subsequently developed a pulmonary embolism due to her immobility and was managed with Apixaban 5 mg BID. This functional status continued for four years up to the current admission. Her home pain management regimen at the time of admission included: Alprazolam 1 mg twice daily, Amitriptyline 25 mg at bedtime, Pregabalin 225 mg daily, Baclofen 5 mg daily, Duloxetine 60 mg twice daily, Oxycodone 30 mg every four hours as needed, and a fentanyl transdermal patch 100 mcg/hour every 48 hours and

25 mcg/hour every 72 hours.

Upon this admission to the hospital, the patient complained of bilateral lower extremity weakness and left sided pain greater than right. Differential diagnoses included new CVA, Guillain-Barre syndrome, and recurrent pain crisis flare. The pain was described as constant, burning, 10/10, and most severe in the left lower extremity causing significant debility and inability to ambulate. Physical exam revealed a tearful and distressed woman due to her chronic pain. Neurological exam exhibited 3/5 muscle strength in bilateral lower extremities and 3/5 muscle strength in left upper extremity which was at her baseline. The remainder of the physical exam was unremarkable. MRI of the brain revealed areas of encephalomalacia and chronic infarct of the right thalamus (*Figure 2*). MRI of the lumbar spine revealed previous discectomy and graft placement at the L5–S1 level. There was facet hypertrophy but no significant stenosis or nerve impingement. Lumbar puncture was performed to rule out developing chronic inflammatory demyelinating polyneuropathy. CSF studies revealed a glucose 57 mg/dL, CSF IgG 6.5 mg/dL, with negative herpes PCR, CMV PCR, cryptococcus Ag, and VDRL. CSF protein was slightly elevated at 51 mg/dL with normal range of 15–45 mg/dL.

On day two, after new structural lesions were ruled out and essentially normal CSF studies, Palliative Medicine was consulted to help with symptom management. Ketamine was recommended, as her symptoms were felt to be progression of central post stroke pain syndrome. Initial PHQ9, GAD7, and Short McGill pain scores were obtained. Ketamine was initiated and successful titration was achieved

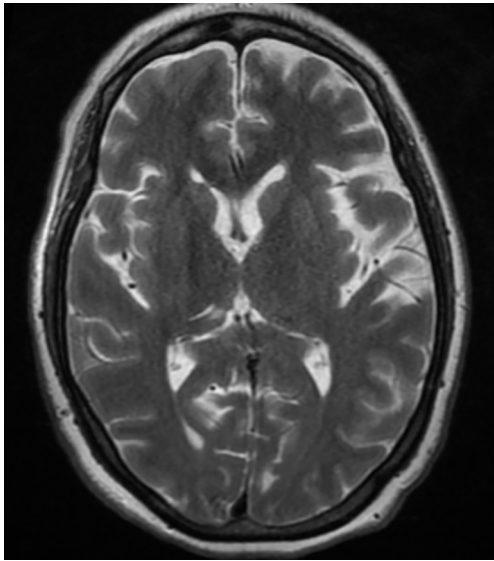


Figure 2 Axial T2 weighted image shows chronic right thalamic infarct.

with the following: 20 mg three times per day for three days, then 30 mg three times a day for three days, then 40 mg three times a day for three days, then a final dose of 50 mg three times a day. The titration time period of three days was used to measure pain relief as well as monitor for over-sedation.

On hospital day 13, the patient was discharged after significant functional improvement was achieved. Subjectively, the patient described pain improving from excruciating to uncomfortable. Objectively, she was able to walk out of her room and to her mother's car on the day of discharge without assistance (est 20 ft). PHQ9 improved from a score of 13/27 on initial encounter to 6/27 after ketamine. GAD7 improved from an initial score of 19/21 to 7/21. Short acting opioid de-escalation was observed with a 33% reduction in short-acting opioids from 30 mg every 4 hours to 20 mg every 4 hours. Long-acting opioids were reduced 20%, and the patient remained only on 100 mcg Fentanyl patch every 48 hours. The patient had significant improvement in fatigue and overall weakness upon weaning from opioids. She was continued on oral ketamine 50 mg three times a day at discharge. All procedures performed in studies involving human participants were in accordance with the ethical standards of the institutional and/or national research committee(s) and with the Helsinki Declaration (as revised in 2013). Written informed consent was obtained from the patient for publication of this study

and any accompanying images. The discharge plan of care was discussed with her outpatient pain management specialist, with a plan to continue weaning from her chronic opioids over the next several weeks.

Discussion

This case demonstrates a new role for the use of oral ketamine in the treatment of central pain, such as in cases of CPSP. Central Post Stroke Pain syndrome was first identified in 1903 in France (6,7). Formerly termed thalamic pain syndrome, CPSP can be described as post CVA pain that is not found to be due to peripheral mechanisms (8). The onset of symptoms can be immediately after ischemic insult, or take months to years to present (6,8). The symptoms include but are not limited to: abnormal thermal sensation, hyperalgesia, touch allodynia, and dysesthesia (8,9). The mechanism of CPSP was initially thought to be due to insult to the thalamus, however recent studies have identified CPSP as a result of injury to many different areas of the nervous system (10). There are yet to be definitive studies identifying the exact pathophysiology of CPSP, and this leads to limited data on treatment. One theory, as mentioned above, is NMDA receptor involvement (2). The patient in this case report was trialed on all medications previously studied for CPSP without much improvement (11). Because of this, ketamine was suggested as a potential treatment option in this patient population.

Ketamine has multiple mechanisms which are useful in the management of chronic pain, including its ability to act on the muscarinic, nicotinic, and opioid receptors throughout the body. The focus of the use in chronic central pain is ketamine's antagonism of the NMDA receptors (12). The mechanism of action of ketamine that supports this theory is two-fold. First, ketamine is a non-competitive antagonist of NMDA receptors. It decreases the channel opening time and therefore decreases the central response of pain to a stimulus (13,14). Additionally, ketamine is a useful tool against opioid hyperalgesia due to its antagonism of the NMDA receptors (2). Because opioid use has been found to cause upregulation of NMDA receptors, the antagonism of these receptors with ketamine is proposed to decrease opioid hyperalgesia. Due to this mechanism, ketamine has not yet been shown to cause the tolerance build up as seen with opioid use.

Historically, ketamine's routes of administration for use in chronic pain included subcutaneous, oral, and intravenous, but in more recent years additional routes

of administration include intramuscular, epidural, intra-articular, topical, intranasal, and sublingual (12). In our patient, oral ketamine was used due to inpatient drug availability and outpatient attainability. Dosing for this case was modeled on the recommendations from the European Journal of pain where authors recommend dosing of ketamine for chronic pain (12). A starting dose of 0.5 mg/kg in divided doses three times a day for ketamine naive patients, with a maximum total daily dose of 800 mg/kg is recommended (12,15).

Palliative care guidelines recommend avoiding ketamine in patients with a history of psychosis, epilepsy, history of increased intracranial pressure, or uncontrolled hypertension, as this could worsen their symptoms (15). Ketamine should be used with caution in patients that are already using long-acting opioids, due to the risk of sedation (15). In patients with underlying cardiac disease or history of arrhythmia, ketamine should be used with caution due to potential QTc prolongation (16). Additionally, ketamine can lower the seizure threshold; therefore, it should not be used in any patients with known seizure disorder or with risk factors for seizure development (15).

This case report displays a single patient that had improvement of her symptoms by using oral ketamine for treatment of Central Post Stroke Pain Syndrome. Additional studies are warranted to evaluate a larger population and establish agreed upon dosing, risks, and benefits of ketamine use in this patient population.

Acknowledgments

This research was supported (in whole or in part) by HCA and/or an HCA affiliated entity. The views expressed in this publication represent those of the authors and do not necessarily represent the official views of HCA or any of its affiliated entities.

Funding: None.

Footnote

Reporting Checklist: The authors have completed the CARE reporting checklist. Available at <http://dx.doi.org/10.21037/apm-20-972>

Conflicts of Interest: All authors have completed the ICMJE uniform disclosure form (available at <http://dx.doi.org/10.21037/apm-20-972>). The authors have no conflicts of interest to declare.

Ethical Statement: The authors are accountable for all aspects of the work in ensuring that questions related to the accuracy or integrity of any part of the work are appropriately investigated and resolved. All procedures performed in studies involving human participants were in accordance with the ethical standards of the institutional and/or national research committee(s) and with the Helsinki Declaration (as revised in 2013). Written informed consent was obtained from the patient for publication of this study and any accompanying images.

Open Access Statement: This is an Open Access article distributed in accordance with the Creative Commons Attribution-NonCommercial-NoDerivs 4.0 International License (CC BY-NC-ND 4.0), which permits the non-commercial replication and distribution of the article with the strict proviso that no changes or edits are made and the original work is properly cited (including links to both the formal publication through the relevant DOI and the license). See: <https://creativecommons.org/licenses/by-nc-nd/4.0/>.

References

- O'Donnell M, Diener H, Sacco R, et al. Chronic Pain Syndromes after Ischemic Stroke: PRoFESS trial. *Stroke* 2013;44:5.
- Petrenko AB, Yamakura T, Baba H, et al. The Role of N-Methyl-d-Aspartate (NMDA) Receptors in Pain: A Review. *Anesth Analg* 2003;97:1108-16.
- Lee M, Silverman S. A Comprehensive Review of Opioid Induced Hyperalgesia. *Pain Physician* 2011;14:145-61.
- Domino EF, Chidiff P, Corssen G. Pharmacologic effects of CI-581, a new dissociative anesthetic in human. *Clin Pharmacol Ther* 1965;6:279-91.
- Kohrs R, Durieux ME. Ketamine: Teaching an Old Drug New Tricks. *Anesth Analg* 1998;87:1186-93.
- Akyuz G, Kuru P. Systemic review of central post stroke Pain. *Am J Phys Med Rehabil* 2016;95:618-27.
- Wilkins RH, Brody IA. The Thalamic Syndrome. *Arch Neurol* 1969;20:559.
- Henry JL, Laloo C, Yashpal K. Central Post Stroke Pain: An Abstruse outcome. *Pain Res Manag* 2008;13:41-9.
- Andersen G, Vestergaard K, Ingeman-Nielsen M, et al. Incidence of central post-stroke pain. *Pain* 1995;61:187-93.
- Boivie J, Leijon G, Johansson I. Central post-stroke pain – a study of the mechanisms through analyses of the sensory abnormalities. *Pain* 1989;37:173-85.
- Mulla SM, Wang L, Khokhar R, et al. Management

- of Central Poststroke Pain: Systematic Review of Randomized Controlled Trials. *Stroke* 2015;46:2853-60.
12. Blonk MI, Koder BG, van den Bemt PM, et al. Use of Oral Ketamine in chronic pain management: A review. *Eur J Pain* 2010;14:466-72.
 13. Mion G, Villeveille T. Ketamine Pharmacology: An Update (Pharmacodynamics and Molecular Aspects, Recent Findings). *CNS Neurosci Ther* 2013;19:370-80.
 14. Effect of Ketamine on Opioid-Induced Hyperalgesia. Available online: <https://clinicaltrials.gov/ct2/show/NCT00833755>
 15. Twycross R, Wilcock A, Charlesworth S, et al. *Palliative Care Formulary*. Nottingham, UK: Radcliffe Medical Press, 2002.
 16. Singh TSS, Elahi F, Cheney B. Ketamine-induced QTc interval prolongation. *J Anaesthesiol Clin Pharmacol* 2017;33:136-8.

Cite this article as: Angstadt R, Esperti S, Mangano A, Meyer S. Palliative ketamine: the use of ketamine in central post-stroke pain syndrome—a case report. *Ann Palliat Med* 2020. doi: 10.21037/apm-20-972