

# Rare case of bilateral carotid artery dissection presenting with Foix-Chavany-Marie syndrome

Rajveer Singh , Alex Rebello , Nandita Prabhat, Dheeraj Khurana

Neurology, Post Graduate  
Institute of Medical Education  
and Research, Chandigarh, India

**Correspondence to**  
Professor Dheeraj Khurana;  
dherajk@yahoo.com

Accepted 8 November 2020

## SUMMARY

Carotid artery dissection is one of the most common causes of ischaemic stroke in young and middle-aged population. We report a case of bilateral carotid artery dissection presenting with opercular syndrome or Foix-Chavany-Marie syndrome. This 46-year-old obese and hypertensive man with a history of fall from bike 1 week prior, presented with sudden onset of anarthria, dysphagia and deviation of angle of mouth. His speech and dysphagia gradually improved over 10 days to normal, but he developed pseudobulbar affect and difficulty in calculations 4 weeks later. MRI showed acute infarcts in bilateral operculum. CT angiography showed dissection in bilateral cervical ICAs. He was managed conservatively with oral anticoagulation, given for 6 months. Probability of dissection must be considered in patients with a history of trauma or falls developing focal neurological deficits. To our knowledge, this is the first case report of bilateral ICA dissection presenting with Foix-Chavany-Marie syndrome.

## BACKGROUND

Carotid artery dissection, a significant aetiology of ischaemic stroke is commoner in young and middle aged people as compared with older.<sup>1</sup> Internal carotid artery dissection can be intracranial or extracranial, depending on aetiology and predisposing factors. It is a multifactorial disease, with causes being either traumatic or spontaneous. Predisposing factors include hypertension, hyperhomocysteinemia, connective tissue diseases, such as Ehler-Danlos syndrome and fibromuscular dysplasia.<sup>2,3</sup> High index of suspicion is warranted when carotid dissection is suspected particularly whenever a patient presents with focal neurologic signs and symptoms along with a history of major or minor neck trauma. We present a patient with opercular syndrome and pseudobulbar affect caused by dissection of bilateral Internal Carotid Arteries and Middle Cerebral Arteries. Opercular syndrome is a rare pseudobulbar palsy caused by insult to bilateral operculum, the most frequent cause being ischemia.

## CASE PRESENTATION

A 46-year-old obese man with essential hypertension diagnosed 3 years ago, developed sudden onset of loss of speech, dysphagia and deviation of angle of mouth to the right side. He was a chronic smoker and had alcohol use disorder. He had a history of fall from motorbike while riding under the influence of alcohol 1 week prior to the onset of these symptoms. He did not have headache, neck pain, vomiting, bleeding from ear, nose or mouth and

loss of consciousness. He did not have any visual disturbance, sensory deficits or limb weakness. His verbal output and dysphagia gradually improved over 10 days to normal. However, he developed uncontrollable outbursts of laughter and difficulty in calculations for which he visited the outpatient department after 4 weeks of initial presentation. His clinical presentation fitted into bilateral opercular syndrome or Foix-Chavany-Marie syndrome. On examination, he had no stigmata of connective tissue disorders or of hypercholesterolemia. His pulse was normal and felt equally in both the sides. Cardiac system examination was normal. His Mini-Mental State Examination score was 22/30. He had impairment in attention, calculation and recall. There was also left seventh nerve palsy and pseudobulbar affect. His power was normal in all the limbs, but he had brisk deep tendon reflexes and flexor plantar response. The examination of sensory, cerebellar and extrapyramidal systems was normal.

## INVESTIGATIONS

Routine haematological and biochemical investigations including lipid profile and HbA1c were normal. ECG did not show any atrial fibrillation. 2D echocardiogram showed concentric left ventricular hypertrophy with grade 1 diastolic dysfunction and normal ejection fraction. Renal artery Doppler did not show any stenosis. MRI brain showed acute to subacute infarcts in bilateral frontoparietal lobes in the water-shed zones (figure 1C-F). MR angiography (MRA) was suggestive of dissection in bilateral cervical internal carotid arteries with significant luminal narrowing extending up to bilateral middle cerebral arteries. CT angiography (CTA) also revealed similar findings (figure 1A,B).

## DIFFERENTIAL DIAGNOSIS

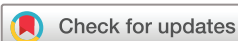We evaluated for secondary causes of dissection like connective tissue disorders, but could not find any underlying cause in our patient.

## TREATMENT

He was managed conservatively with oral anticoagulation, which was given for 6 months and antihypertensive drugs were optimised. He was also given dextromethorphan for his pseudobulbar affect.

## OUTCOME AND FOLLOW-UP

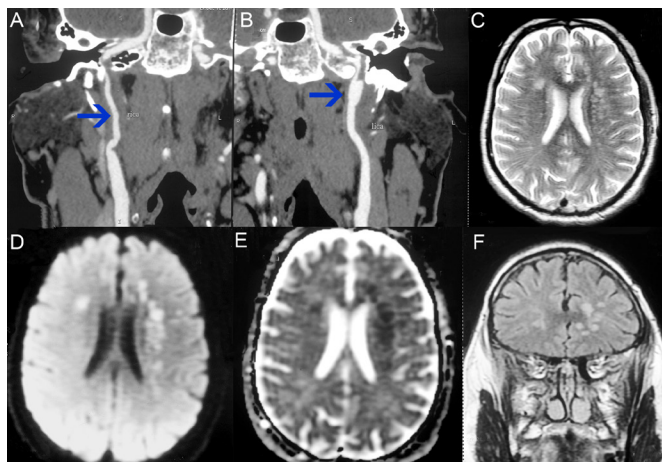
On follow-up at 6 months, his pseudobulbar affect and memory disturbance remained the same without any new symptoms. His anticoagulation was stopped after 6 months.



© BMJ Publishing Group Limited 2020. No commercial re-use. See rights and permissions. Published by BMJ.

**To cite:** Singh R, Rebello A, Prabhat N, et al. *BMJ Case Rep* 2020;**13**:e239080. doi:10.1136/bcr-2020-239080

## Case report



**Figure 1** CT angiography showing dissection in bilateral cervical ICA extending up to bilateral MCA with significant luminal narrowing (A,B). MRI of brain showing acute infarcts in bilateral operculum (C–F).

## DISCUSSION

Arterial dissection is one of the most common causes of stroke in young and middle-aged population. It accounts for 1%–2% of all ischaemic strokes. In younger patients, it contributes to 10%–24% of the total strokes.<sup>4–6</sup> In an Indian study of young strokes, arterial dissection was the cause in 7% of the cases.<sup>7</sup> The pathophysiology of cervical artery dissection is not yet well understood. It has a multifactorial aetiology which includes trauma and connective tissue disorders which have risk for spontaneous dissection, such as Ehlers-Danlos syndrome. Trauma is an important cause of dissection. Traumatic dissection can occur as a result of non-penetrating or penetrating neck trauma.<sup>2</sup> Our patient had a history of fall from bike 1 week prior to the onset of his symptoms. A diagnosis of carotid artery dissection should be considered in patients presenting with stroke and a history of headache, facial pain, neck pain, Horner's syndrome, tinnitus and/or cranial nerve palsies. These symptoms may present immediately after dissection, within minutes to hours or up to 1 month after the dissection. Pain is usually the most common initial symptom. Some patients may remain asymptomatic for a prolonged period, like our patient who was asymptomatic for 1 week after trauma.<sup>2 8</sup> Pathologically, carotid dissection is associated with haematoma in the wall of the artery resulting in stenosis, aneurysmal dilatation and cerebral ischaemia due to embolism or haemodynamic infarction.<sup>9</sup> Cerebral ischemia resulting in transient ischaemic attacks or strokes was seen in 56% of the cases of cervical artery dissection in a study.<sup>10</sup> There can be bilateral involvement as in our case in around 5%–10% of the carotid artery dissections.<sup>11</sup> However, bilateral opercular syndrome due to bilateral carotid artery dissection and the resulting cerebral ischemia has not been reported in the literature before.

Opercular syndrome or Foix-Chavany-Marie syndrome is characterised by dissociation of automatic and voluntary movements. The voluntary control of face, tongue and the pharyngeal muscles is provided by primary motor cortex and pyramidal tract, whereas the spontaneous and the emotional control is sub-served by the thalamus, hypothalamus and extrapyramidal tract.<sup>12</sup> In opercular syndrome, volitional control of the lingual, pharyngeal, facial and the masticatory musculature is lost with preserved automatic movements. Clinical manifestations include difficulty in opening mouth, protruding tongue, chewing, swallowing and speech impairment.<sup>12</sup> Opercular syndrome is caused

by bilateral opercular cortex lesions, surrounding the insula although sometimes unilateral lesion may also present with similar signs and symptoms.<sup>13</sup>

Opercular syndrome can be acquired (as in our patient) or congenital, intermittent or persistent. The causes of opercular syndrome include vascular diseases, bilateral perisylvian cortical dysplasia, CNS infection, neurodegenerative disorder or sometimes epilepsy. Most commonly reported cases, including our case, are attributed to occlusion of middle cerebral artery branches which supply the operculum, by thrombosis or embolism.<sup>14</sup> Our patient had bilateral carotid artery dissection extending up to bilateral middle cerebral artery which led to opercular syndrome and recent memory loss. He improved partially with residual deficits which included pseudobulbar affect and memory loss.

Carotid dissection can be diagnosed non-invasively with MRA, CTA or carotid ultrasound. MRA and CTA are found to be similar in terms of diagnosing carotid dissection, with CTA being often preferred. CTA is becoming gold standard for patients with symptomatic cervical artery dissection.<sup>13 15</sup>

## Learning points

- ▶ There has to be a high index of suspicion of carotid dissection in patients presenting with neurological dysfunction after trauma despite the absence of definite neck pain or headache.
- ▶ Bilateral ICA dissection is a rare cause of bilateral opercular syndrome, also known as Foix-Chavany-Marie syndrome.
- ▶ Opercular syndrome is characterised by dissociation of automatic and voluntary movements of lingual, pharyngeal, facial and the masticatory musculature.

**Contributors** RS and AR drafted the manuscript. NP had a role in critical review of the manuscript. RS and DK managed the patient and had a role in conception, organisation and execution of the report.

**Funding** The authors have not declared a specific grant for this research from any funding agency in the public, commercial or not-for-profit sectors.

**Competing interests** None declared.

**Patient consent for publication** Obtained.

**Provenance and peer review** Not commissioned; externally peer reviewed.

## ORCID iDs

Rajveer Singh <http://orcid.org/0000-0001-7173-8035>

Alex Rebello <http://orcid.org/0000-0002-0954-5475>

## REFERENCES

- 1 Schievink WI. Spontaneous dissection of the carotid and vertebral arteries. *N Engl J Med* 2001;344:898–906.
- 2 Debette S, Leys D. Cervical-Artery dissections: predisposing factors, diagnosis, and outcome. *Lancet Neurol* 2009;8:668–78.
- 3 Blum CA, Yaghi S. Cervical artery dissection: a review of the epidemiology, pathophysiology, treatment, and outcome. *Arch Neurosci* 2015;2:e26670.
- 4 Giroud M, Fayolle H, André N, et al. Incidence of internal carotid artery dissection in the community of Dijon. *J Neurol Neurosurg Psychiatry* 1994;57:1443.
- 5 Prasad K, Singhal KK. Stroke in young: an Indian perspective. *Neurol India* 2010;58:343–50.
- 6 Nedeltchev K, der Maur TA, Georgiadis D, et al. Ischaemic stroke in young adults: predictors of outcome and recurrence. *J Neurol Neurosurg Psychiatry* 2005;76:191–5.
- 7 Lipska K, Sylaja PN, Sarma PS, et al. Risk factors for acute ischaemic stroke in young adults in South India. *J Neurol Neurosurg Psychiatry* 2007;78:959–63.
- 8 Robertson JJ, Koyfman A. Cervical artery dissections: a review. *J Emerg Med* 2016;51:508–18.
- 9 Lucas C, Moulin T, Deplanque D, et al. Stroke patterns of internal carotid artery dissection in 40 patients. *Stroke* 1998;29:2646–8.
- 10 Lee VH, Brown RD, Mandrekar JN, et al. Incidence and outcome of cervical artery dissection: a population-based study. *Neurology* 2006;67:1809–12.
- 11 Mellion ML, Rizvi S. Spontaneous bilateral carotid artery dissection and posterior reversible encephalopathy syndrome. *Neurology* 2005;65:1990.

- 12 Milanlioglu A, Aydın MN, Gökgül A, *et al.* Ischemic bilateral opercular syndrome. *Case Rep Med* 2013;2013:1–3.
- 13 Kutluay E, Colakoğlu Z, Dirlik A, *et al.* Brain SPECT in anterior opercular syndrome due to a unilateral lesion. *J Neurol* 1996;243:427–9.
- 14 Praveen-Kumar S, Pramod K. Bi-opercular syndrome: a case report and minireview. *J Clin Diagn Res* 2014;8:MD03-MD4.
- 15 Patel RR, Adam R, Maldjian C, *et al.* Cervical carotid artery dissection: current review of diagnosis and treatment. *Cardiol Rev* 2012;20:145–52.

Copyright 2020 BMJ Publishing Group. All rights reserved. For permission to reuse any of this content visit <https://www.bmj.com/company/products-services/rights-and-licensing/permissions/>  
BMJ Case Report Fellows may re-use this article for personal use and teaching without any further permission.

Become a Fellow of BMJ Case Reports today and you can:

- ▶ Submit as many cases as you like
- ▶ Enjoy fast sympathetic peer review and rapid publication of accepted articles
- ▶ Access all the published articles
- ▶ Re-use any of the published material for personal use and teaching without further permission

#### Customer Service

If you have any further queries about your subscription, please contact our customer services team on +44 (0) 207111 1105 or via email at [support@bmj.com](mailto:support@bmj.com).

Visit [casereports.bmj.com](http://casereports.bmj.com) for more articles like this and to become a Fellow