

Title: Vessel Wall Imaging of Basilar Artery Perforator Disease

Authors: Jae W. Song, MD<sup>1</sup>; Sahily Reyes-Esteves, MD, PhD<sup>2</sup>; Brett L. Cucchiara, MD<sup>2</sup>

1. Department of Radiology, Hospital of the University of Pennsylvania, 3400 Spruce Street, Philadelphia, PA 19104
2. Department of Neurology, Hospital of the University of Pennsylvania, 3400 Spruce Street, Philadelphia, PA 19104

Corresponding Author:

Jae W Song, MD, MS

Hospital of the University of Pennsylvania

Department of Radiology

3400 Spruce Street

Philadelphia, PA 19104

Phone: 215-662-6865

Fax: 215-662-3283

Email: [jae.song@pennmedicine.upenn.edu](mailto:jae.song@pennmedicine.upenn.edu)

Running Head: VWI and Basilar Artery Perforator Disease

Manuscript Length

Title: 57 characters spaces included 8 words

Running Head: 41 characters spaces included 6 words

Figure caption: 404

References: 4

Figures: 1

Keywords: Stroke, Vessel wall MRI, Atherosclerosis

This article has been accepted for publication and undergone full peer review but has not been through the copyediting, typesetting, pagination and proofreading process which may lead to differences between this version and the [Version of Record](#). Please cite this article as doi: [10.1002/ana.25980](https://doi.org/10.1002/ana.25980)

Figure Caption:

A 58-year-old male with hypertension, hyperlipidemia, diabetes mellitus, and obesity had abrupt left leg weakness and gait imbalance. Four hours later, left arm weakness and numbness and dysarthria developed and he presented to the hospital. Computed tomographic angiogram of the head and neck showed no acute hemorrhage, large vessel occlusion, or significant stenosis of the intracranial or extracranial arteries. He was treated with aspirin and clopidogrel. Thirteen hours later, he developed double vision with a new right 6<sup>th</sup> nerve palsy and dysconjugate gaze. Brain magnetic resonance (MR) imaging showed an acute right basal paramedian pontine infarction without hemorrhage (Fig 1A). Intracranial vessel wall MR imaging was performed using time-of-flight magnetic resonance angiography (MRA) and pre- and post-contrast black-blood imaging optimized to visualize the vessel walls. The basilar artery at the level of the pontine infarction showed subtle irregularity of the lumen with low-grade stenosis (<30% stenosis) (Fig 1B). Vessel wall MR imaging showed eccentric vessel wall thickening and enhancement along the right basilar artery wall ipsilateral to the side of infarction as shown in the coronal and sagittal planes (Fig 1C-D). Orthogonal planes of the pre- and postcontrast imaging confirmed an enhancing plaque along the right lateral surface of the basilar artery (Fig 1E-F). No other intracranial arteries, including the dominant right intradural vertebral artery, showed stenosis, vessel wall thickening or wall enhancement. Taken together, the imaging findings implicate a mid-basilar atherosclerotic plaque occluding right pontine perforators as the stroke etiology. This is also consistent with the patient's stuttering, stepwise deterioration over the initial 24 hours. Perforator disease, also known as branch atheromatous disease, is a common mechanism for paramedian pontine infarctions with plaque occluding the perforator ostia.<sup>1, 2</sup> Due to the ability of the vessel wall to accommodate plaque formation by outwardly remodeling, the artery may not show significant luminal stenosis on lumen-based imaging. Vessel wall MR imaging highlights vessel wall pathology such as atherosclerotic plaque that is not otherwise detected by conventional CT or MR angiography. The technique may be of particular diagnostic value for stroke sub-typing by identifying non-stenotic plaque, as shown in this illustrative case.<sup>3</sup> As up to 20% of cardiac emboli can flow antegrade into the posterior circulation, cardioembolism could be considered a cause of this stroke.<sup>4</sup> Upon the exclusion of other potential sources of stroke mechanism, such as cardioembolism,

vessel wall MR imaging can be used to support intracranial atherosclerotic plaque as the underlying cause of stroke and provide greater precision in diagnostic care.

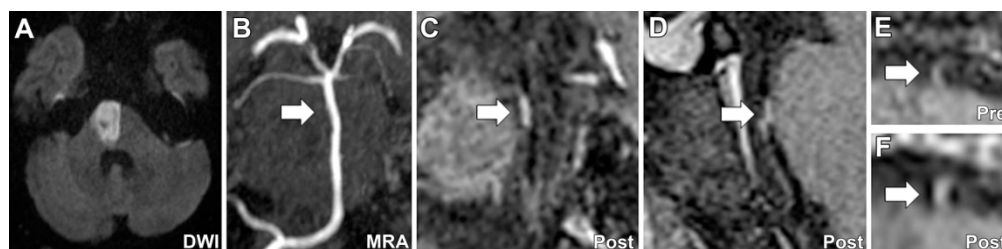
## REFERENCES

1. Fisher CM, Caplan LR. Basilar artery branch occlusion: A cause of pontine infarction. *Neurology* 1971;21(9):900-905.
2. Yu J, Li M-, Xu Y- et al. Plaque distribution of low-grade basilar artery atherosclerosis and its clinical relevance. *BMC Neurology* 2017;17(1).
3. Klein IF, Lavallée PC, Mazighi M et al. Basilar artery atherosclerotic plaques in paramedian and lacunar pontine infarctions: A high-resolution MRI study. *Stroke* 2010;41(7):1405-1409.
4. Caplan LR, Wityk RJ, Glass TA et al. New England Medical Center posterior circulation registry. *Ann Neurol* 2004;56(3):389-398.

**Acknowledgements:** None.

**Author Contributions:** JWS, SRE, and BLC contributed to the conception and design of the study; BLC and JWS contributed to acquisition and analysis of the data. JWS, SRE, and BLC contributed to drafting of the text. JWS contributed to preparing the figures.

**Potential Conflicts of Interests:** Nothing to report.



A 58-year-old male with hypertension, hyperlipidemia, diabetes mellitus, and obesity had abrupt left leg weakness and gait imbalance. Four hours later, left arm weakness and numbness and dysarthria developed and he presented to the hospital. Computed tomographic angiogram of the head and neck showed no acute hemorrhage, large vessel occlusion, or significant stenosis of the intracranial or extracranial arteries. He was treated with aspirin and clopidogrel. Thirteen hours later, he developed double vision with a new right 6th nerve palsy and dysconjugate gaze. Brain magnetic resonance (MR) imaging showed an acute right basal paramedian pontine infarction without hemorrhage (Fig 1A). Intracranial vessel wall MR imaging was performed using time-of-flight magnetic resonance angiography (MRA) and pre- and post-contrast black-blood imaging optimized to visualize the vessel walls. The basilar artery at the level of the pontine infarction showed subtle irregularity of the lumen with low-grade stenosis (<30% stenosis) (Fig 1B). Vessel wall MR imaging showed eccentric vessel wall thickening and enhancement along the right basilar artery wall ipsilateral to the side of infarction as shown in the coronal and sagittal planes (Fig 1C-D). Orthogonal planes of the pre- and postcontrast imaging confirmed an enhancing plaque along the right lateral surface of the basilar artery (Fig 1E-F). No other intracranial arteries, including the dominant right intradural vertebral artery, showed stenosis, vessel wall thickening or wall enhancement. Taken together, the imaging findings implicate a mid-basilar atherosclerotic plaque occluding right pontine perforators as the stroke etiology. This is also consistent with the patient's stuttering, stepwise deterioration over the initial 24 hours. Perforator disease, also known as branch atheromatous disease, is a common mechanism for paramedian pontine infarctions with plaque occluding the perforator ostia.<sup>1, 2</sup> Due to the ability of the vessel wall to accommodate plaque formation by outwardly remodeling, the artery may not show significant luminal stenosis on lumen-based imaging. Vessel wall MR imaging highlights vessel wall pathology such as atherosclerotic plaque that is not otherwise detected by conventional CT or MR angiography. The technique may be of particular diagnostic value for stroke sub-typing by identifying non-stenotic plaque, as shown in this illustrative case.<sup>3</sup> As up to 20% of cardiac emboli can flow anterograde into the posterior circulation, cardioembolism could be considered a cause of this stroke.<sup>4</sup> Upon the exclusion of other potential sources of stroke mechanism, such as cardioembolism, vessel wall MR imaging can be used to support intracranial atherosclerotic plaque as the underlying cause of stroke and provide greater precision in diagnostic care.

170x40mm (300 x 300 DPI)