

Cerebral Vasospasm after Posterior Fossa Tumor Surgery: A Case Report and Literature Review

Selcuk Gocmen^a Gokhan Acka^a Kutlay Karaman^b Serdar Kahraman^a

^aDepartment of Neurosurgery, Anadolu Medical Center, Kocaeli, Turkey; ^bDepartment of Radiology, Anadolu Medical Center, Kocaeli, Turkey

Established Facts

- Cerebral vasospasms are a possible complication of cerebral tumor surgery.
- Only 6 pediatric cases of cerebral vasospasm following tumor resection have been reported in the literature till date.

Novel Insights

- Delayed neurological deterioration may be seen after pediatric posterior fossa tumor surgery.
- Symptomatic vasospasms following posterior fossa tumor resection should be included in the differential diagnoses for delayed and unexpected neurological decline in patient status.
- This is the first reported case of cerebral vasospasm following resection of a medulloblastoma located in the vermis of the cerebellum and fourth ventricle.

Keywords

Cerebral vasospasm · Brain tumor · Posterior fossa · Medulloblastoma · Pediatric age

Abstract

Introduction: This report presents an unusual case of symptomatic vasospasm following resection of posterior fossa tumor in a 9-year-old female patient. To the best of our knowledge, only 6 pediatric cases of vasospasms as a complication of brain tumor surgery have been reported in the literature previously. **Case Presentation:** After an uneventful 12 days

postoperatively, the patient suddenly presented with acute neurological deterioration on the 13th day and MR angiography showed bilateral narrowing of the supraclinoid segments of the internal carotid artery and the proximal parts of the A1 and M1 segments. Hypervolemia and vasospasm treatments were administered, and the patient exhibited no neurological deficit at the time of discharge, confirmed via normal MRI. **Conclusion:** Early diagnosis and intervention in case of suspected symptomatic cerebral vasospasm after pediatric posterior fossa tumor surgery are essential in order to achieve favorable outcomes.

© 2020 S. Karger AG, Basel

Introduction

Symptomatic cerebral vasospasms, although fairly well documented in patients with aneurysmal subarachnoid hemorrhage (SAH) and traumatic brain injuries [1–4], are relatively uncommon in individuals undergoing brain tumor resection. They contribute significantly to morbidity and mortality in patients of all ages and may easily be confused with cerebral edema and surgical injury, leading to misdiagnosis and incorrect treatment [4]. They are most commonly associated with pituitary tumors and sellar meningiomas and are rarely observed in relation to posterior fossa tumors [1, 3].

Resection of posterior fossa tumors, which are frequently detected in childhood, may be associated with an unexpected and rare complication, cerebral vasospasm. Therefore, neurological deterioration and suspected vasospasms in the delayed postoperative period should be immediately treated using relevant anti-vasospasm therapy, including medical management and/or endovascular interventions (e.g., angioplasty, intra-arterial vasodilators) in order to ensure favorable outcomes. Furthermore, daily transcranial Doppler examinations may be used for follow-up of pediatric patients.

This case report summarizes the mechanisms, diagnostic evaluations, and prompt treatment measures used to achieve a favorable outcome following occurrence of symptomatic vasospasm after surgical removal of a posterior fossa tumor.

Case Report

A female patient, aged 9 years, was admitted to our department with a complaint of headache, vomiting, double vision, and ataxia for a period of 3 months. Neurological examination showed cerebellar ataxia, impaired tandem gait, Romberg sign (+), horizontal nystagmus, and diplopia without cranial nerve palsy. Gadolinium-enhanced MRI showed the presence of a tumor that originated from the vermis of the cerebellum and extended into the fourth ventricle. Additionally, supratentorial hydrocephalic changes and transependymal permeation of cerebrospinal fluid (CSF) were also observed. The medulloblastoma often presents as a heterogeneous mass on T2-weighted images, with hypo- and hyperintense regions representing cysts, necrosis, and calcifications (shown in Fig. 1a). Contrast enhancement may also be observed in a significant majority (shown in Fig. 1b). High cellularity and nuclear-cytoplasmic ratios of the medulloblastoma can lead to restricted diffusion of water particles in the tumor and low apparent diffusion coefficient values, resulting in the tumor exhibiting a characteristically high signal in diffusion-weighted MR images (shown in Fig. 1c) and low signals on apparent diffusion coefficient maps.

In the current case, the tumor was completely removed by carrying out median suboccipital craniotomy in the concorde posi-

tion using neuro-navigation, intraoperative neuro-monitoring, and fluorescent microscopy. External ventricular drainage was not inserted after tumor resection as normal CSF circulation was observed during surgery. The surgical duration was 5 h, including 2 h for tumor resection, and total intraoperative bleeding was 300 mL. Blood loss due to tumor resection per se was approximately 100 mL, and histopathological examination showed a diagnosis of classical medulloblastoma.

Since she was an abroad patient, her prolonged hospitalization period was selected as the patient was from overseas, and she was fully conscious and exhibited no further neurological deficits during the first 12 days after surgery. However, neurological examination on the 13th day showed lethargy, increase of cerebellar ataxia, and impaired tandem gait. Her metabolic and infectious parameters were within the normal range, and bright intravascular signal intensity consistent with slow flow in both middle cerebral artery (MCA) branches was observed in the FLAIR sequence (shown in Fig. 2a). Diffusion-weighted-MRI, T2-weighted, and FLAIR series showed no acute ischemic changes in the brain, while 3D time-of-flight MR angiographic (MRA) examinations (performed secondary to these findings and on both sides) showed findings consistent with bilateral narrowing of the ICA supraclinoid segments and proximal parts of A1 and M1 segments (shown in Fig. 2b). Coronal MR angiogram may exhibit the all part of ICA better than axial images in these cases. The vertebrobasilar system was normal, no evidence of intra- or extra-axial hemorrhage was detected, and the supratentorial ventricular enlargement was seen to be diminished in comparison with the preoperative MR images.

The patient was moved to the pediatric critical care unit for 4 days, and nimodipine (15 mcg/kg/h, 2 mL/h IV infusion for 5 days), steroids (dexamethasone 0.6 mg/kg/day, 4 × 4 mg IV for 1 week), intravenous piracetam (Nootropil 800 mg, 4 × 1 IV for 1 week), and hyperdynamic therapy (H therapy) were started to reduce the severity of cerebral vasospasm and improve long-term outcomes. The aim was to achieve 95 percentile (113/75 mm/Hg) or higher blood pressure, as appropriate for the patient age (9-year old), sex (female), height (130 cm), and weight (26 kg). Additionally, 1,500 cc/day fluid therapy was administered for 4 days to achieve euvolemia. The efficacy of treatment was monitored using periodic neurological examination, and the patient's condition was seen to improve gradually within 4 days. Her symptoms and MRI findings improved drastically within 10 days, and no neurological deficits were observed at the time of discharge. The patient completed chemotherapy and radiotherapy treatment, and MRI investigation at the 2-year postsurgical follow-up showed that the patient was still stable (shown in Fig. 3).

Discussion

Previous evidence suggests that delayed cerebral ischemia caused by vasospasms after intracranial tumor resection are rare in adult and pediatric patients, and even more so following posterior fossa tumor resection (incidence rate: 1.9%) [5, 6]. In their systematic review, Alo-taibi et al. [1] identified 40 reported cases of cerebral vasospasms following tumor resection, and the mean age of

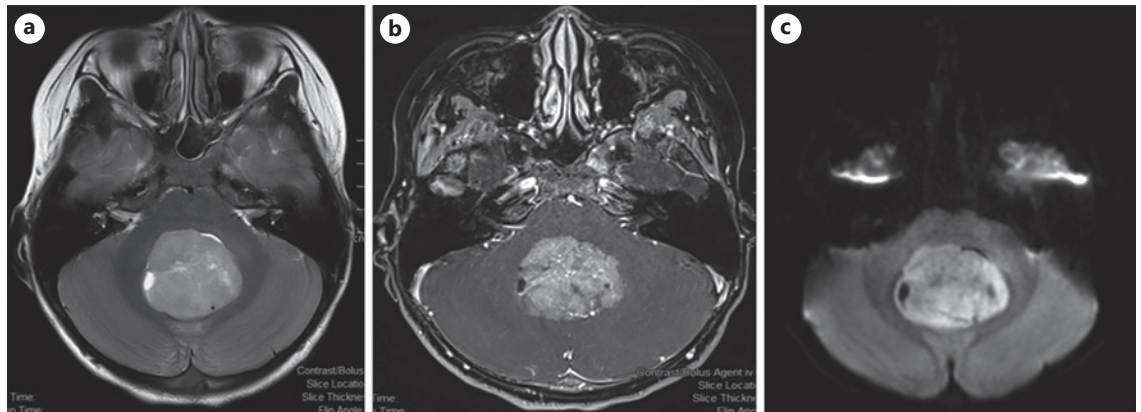


Fig. 1. T2-weighted image showing a hyperintense mass located in the midline of the posterior fossa (a); Gadolinium-enhanced axial T1-weighted image showing presence of a tumor with well-defined margins and solid enhancement originating from the vermis of the cerebellum and extending into the fourth ventricle (b); Medulloblastomas are characterized by high signal in DWI and low ADC values (c). DWI, diffusion-weighted; ADC, apparent diffusion coefficient.

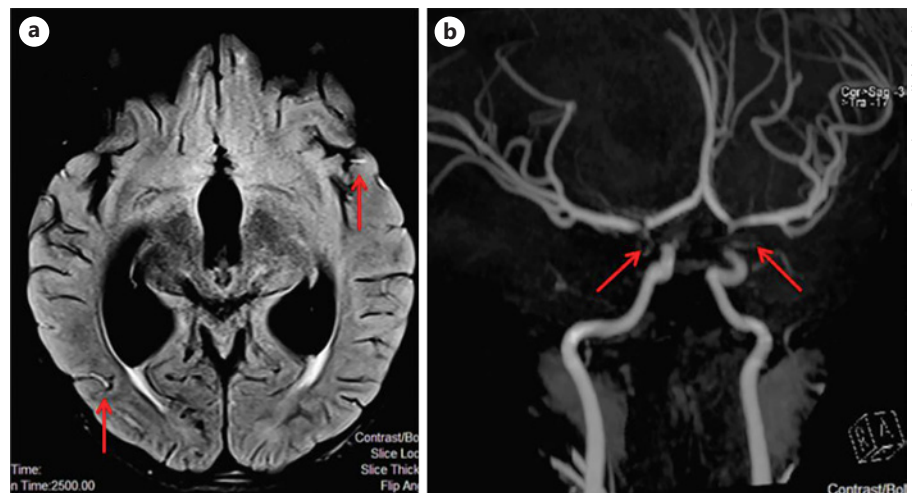


Fig. 2. FLAIR sequence showing bright intravascular signal intensity consistent with slow flow in both MCA branches (Red arrows) (a); 3D TOF MRA images showing bilateral narrowing of the ICA supraclinoid segments and proximal parts of A1 and M1 segments (Red arrows) (b). MCA, middle cerebral artery; TOF, time-of-flight; MRA, MR angiographic.

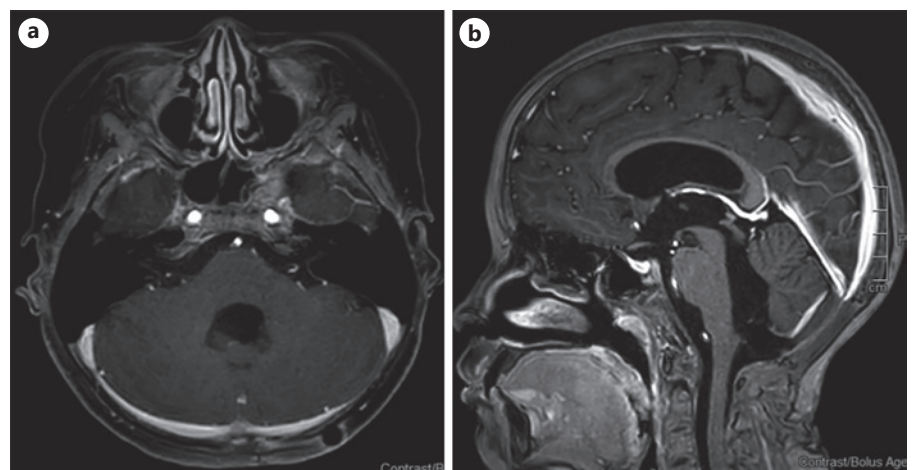


Fig. 3. Gadolinium-enhanced axial (a)/sagittal (b) T1-weighted images of the patient after completion of radiotherapy and chemotherapy showing stable condition 2 years after surgery.

Table 1. Summary of reported cases of symptomatic vasospasm following brain tumor resection in childhood

Authors	Age, years/sex	Pathology	Onset	Symptoms	Vessels involved	Treatment	Outcome
Bejjani et al. [7]	6/F	Third nerve schwannoma	7 days	Changed of mental status	Right ICA, MCA, PCA	3H therapy, angioplasty	Full recovery
Lee et al. [2]	1.3/F	Left CPA, neuroectodermal tm	16 days	Left hemiparesis and right partial ptosis	Bilateral ICA and vertebral arteries	3H therapy, nimodipine, anti-coagulation	Bihemispheric and brainstem infarcts, exitus
Rao et al. [3]	10/F	Right CPA, anaplastic medulloblastoma	10 days	Headache, N/V, ataxia, bilaterally legs weakness, dysphasia	Right PCA, M1, left PCA, A2, M1, carotid terminus	V/P shunt, 3H therapy, nimodipine (10 days)	Full recovery (mild facial paralysis due to surgery)
Afshari et al. [8]	9/F	Left hypoglossal schwannoma	8 days	Left hemiparesis, facial weakness	Bilateral ICA, MCA and ACA	EVD, 3H therapy, nimodipine (1 week)	Full recovery
Dalvi et al. [9]	17/M	Left cerebellar, medulloblastoma	14 days	Focal weakness, aphasia, lethargy, bradycardia, brainstem reflexes ↓	Left ICA, basilar artery, progress circle of Willis territories bilaterally	EVD steroids, 3H therapy, intratecal nicardipine	Full recovery (after 6 weeks prolonged course)
Qi et al. [4]	16/M	Left ventral medulla oblongata schwannoma	3 days	Changed of mental status	Bilateral ICA, basilar arteries	Nimodipine, 3H therapy, decompressive craniectomy after 7 days	Vegetative state
Gocmen et al. [current report]	9/F	Vermis of cerebellum and fourth ventricle medulloblastoma	13 days	Lethargy, cerebellar ataxia	Bilateral ICA, A1 and M1	3H therapy, nimodipine, steroids, piracetam	Full recovery

H therapy, hyperdynamic therapy; MCA, middle cerebral artery.

the patients was only 41 years (range: 1–69 years). Additionally, the morbidity and mortality (30%) rates were high, and the onset of vasospasm symptoms peaked on the 7th–8th days and primarily involved the anterior circulation [1]. Early diagnosis and treatment of cerebral vasospasm are critical as the clinical presentation is variable and often progressive.

Only 6 pediatric cases of vasospasms as a complication of brain tumor surgery have been reported so far (Table 1) [2–4, 7–9], making our patient the 7th. The mean age of these patients was 9.5 years (range 1.3–17 years), and the onset of symptoms typically occurred between days 3–16 (mean: 10 days) and peaked on the 7th–8th days.

Pituitary tumors and sellar meningiomas were most commonly associated with this complication [1], while posterior fossa tumors and skull base tumor resections were very rarely associated with symptomatic vasospasms (with only 9 cases being reported so far) [1]. Interestingly, posterior fossa tumors exhibited a greater tendency to cause diffuse vasospasms [1], which have also been observed after resection of schwannomas, astrocytoma, brain metastasis, and neuroectodermal tumor [3]. To the best of our knowledge, this is the first reported case of a diffuse cerebral vasospasm following resection of a medulloblastoma located in the vermis of the cerebellum and fourth ventricle.

Multiple physiopathological mechanisms, such as direct mechanical trauma, intraoperative bleeding, vascular factors (vessel encasement, displacement, and narrowing), release of vasoactive substances, hypothalamic dysfunction after resection of sellar or parasellar tumors, tumor location, tumor pathology, and compression may help explain vasospasms in the postoperative period [1, 2, 4, 8, 10]. Intraoperative bleeding facilitating spillage of blood into the subarachnoid space is also known to be correlated with this complication [1] and could likely explain the vasospasm observed in the current case where the occurrence of approximately 100 mL of intraoperative bleeding in the basal cistern during tumor resection could have led to SAH, even without direct contact of the supratentorial vessels. The patient exhibited complete recovery after appropriate vasospasm treatment.

The trigeminal system regulates the blood flow and metabolism of the brain and could represent another possible mechanism for occurrence of vasospasm [4]. Lee et al. [2] previously reported a case of vasospasm after resection of a primitive neuroectodermal tumor at the cerebellopontine angle, and attributed this to a systemic autoimmune or paraneoplastic postsurgical response. In the cur-

rent case, the patient underwent radiotherapy and chemotherapy after recovering from cerebral vasospasm and remained uneventful 2 years after surgery.

Cerebral vasospasm should be considered in the differential diagnoses for neurological deterioration following brain tumor resection should include cerebral vasospasms. Despite their ability to detect vasospasms within the intracranial vasculature, MRAs are not routinely used for control MRIs after brain surgery. Instead, FLAIR sequences based on fast spin-echo sequences are available in a majority of commercial clinical MR systems and are used to improve the detectability of small lesions closer to the CSF. They can also detect occlusion by increasing the signal within arteries in patients with hyperacute ischemic stroke [11], and these are sometimes described as “hyperintense vessel signals.” Such intra-arterial hyperintense signals in FLAIR images may indicate lack of flow void, total obstruction of the artery, or slow flow. FLAIR images play a crucial role in the decision to carry out MR angiography for postoperative control MRI investigation. 3D time-of-flight MRAs are noninvasive; do not require radiation and contrast; can show cranial arterial systems with high spatial resolution; and are also capable of multiplanar reconstruction. Previous literature suggests that MRAs have an overall specificity of 97% with regard to detection of cerebral arterial vasospasms [12]. Digital subtraction angiography is the gold standard for diagnosing cerebral vasospasm; however, it is invasive, difficult to repeat, and can induce complications. Therefore, Rao et al. [3] emphasized the utility of transcranial Doppler ultrasonographies in diagnosing pediatric vasospasms following brain tumor resection, and also highlighted the successful use of hemodynamic augmentation for treatment.

Early detection of arterial vasospasms is necessary for effective treatment and improvement of clinical outcomes, and the recommended treatment algorithm may be similar to that used in an SAH. In addition to triple H therapy and calcium channel blockers [13], endovascular options such as balloon angioplasty and vasodilator treatment can also be used for focal refractory vasospasms [2, 8]. Aggressive treatments may be necessary to prevent ischemia and further neurological deficits, and all cases of arterial vasospasms reported till date underwent triple H therapy. In the current case, intravenous steroids and piracetam were used in addition to hypervolemia and hypertension treatment and calcium channel blocker in order to target cerebral edema and regulate microvascular circulation. Although there is no evidence on the efficacy of piracetam in the treatment of pediatric delayed cere-

bral ischemia till date, previous studies have reported its uses in the regulation of cerebral microvascular circulation [14]. Our treatment protocol aimed to achieve normal hematocrit levels as hemodilution may affect oxygen delivery to the brain, as per the latest guidelines on treatment of cerebral vasospasms [15].

In conclusion, diffuse symptomatic vasospasms following posterior fossa tumor resection are extremely rare and challenging in pediatric patients and are associated with high morbidity and mortality rates. Therefore, they should be included in the differential diagnoses of delayed and unexpected neurological decline in the patient's status. Delayed diagnosis of cerebral vasospasms may lead to poor outcomes, and MRIs should be used for early detection if symptomatic cerebral vasospasms are suspected after posterior fossa tumor surgery, even in the late postoperative period. In this report, we summarized correct diagnosis of vasospasm in our pediatric patient and described the aggressive and timely treatment delivered, resulting in an uneventful postoperative period.

Statement of Ethics

This work complies with the guidelines for human studies, and the research was conducted ethically in accordance with the World Medical Association Declaration of Helsinki. The authors confirm that written informed consent was collected from the parent/legal guardian prior to treatments and for publication of data and images.

Conflict of Interest Statement

The authors have no conflicts of interest to declare.

Funding Sources

The authors did not receive any funding.

Author Contributions

Selcuk Gocmen: contributed to the design of the work, revised the manuscript critically for intellectual content, is accountable for all aspects of the work and for ensuring that all questions related to the accuracy or integrity of any part of the work are appropriately investigated and resolved, approved the final version of manuscript for publication. *Gokhan Acka*: contributed to the design and interpretation of data, revised the manuscript critically for crucial intellectual content, is accountable for all aspects of the work and for ensuring that questions related to the accuracy or integrity of any part of the work are appropriately investigated and

resolved, approved the final version of manuscript for publication. *Kutlay Karaman*: contributed to the design of the work and interpretation of images, revised the manuscript critically for intellectual content, is accountable for all aspects of the work and for ensuring that all questions related to the accuracy or integrity of any part of the work are appropriately investigated and resolved, approved the final version of manuscript for publication. *Serdar Kah-*

raman: contributed to the design of the work, revised the manuscript critically for intellectual content, is accountable for all aspects of the work and for ensuring that all questions related to the accuracy or integrity of any part of the work are appropriately investigated and resolved, approved the final version of manuscript, has revised for publication.

References

- 1 Alotaibi NM, Lanzino G. Cerebral vasospasm following tumor resection. *J Neurointerv Surg*. 2013;5(5):413–8.
- 2 Lee TT, Ragheb J, Bruce JC, Altman N, Morrison G. Diffuse cerebral vasospasm with ischemia after resection of a cerebellopontine angle primitive neuroectodermal tumor in a child. *Pediatr Neurosurg*. 1998;29(6):300–3.
- 3 Rao VK, Haridas A, Nguyen TT, Lulla R, Wainwright MS, Goldstein JL. Symptomatic cerebral vasospasm following resection of a medulloblastoma in a child. *Neurocrit Care*. 2013;18(1):84–8.
- 4 Qi J, Zhang L, Jia W, Zhang J, Wu Z. Diffuse cerebral vasospasm after resection of schwannoma: a case report. *Neuropsychiatr Dis Treat*. 2015;11:317–20.
- 5 Vergouwen MD, Vermeulen M, van Gijn J, Rinkel GJ, Wijdevicks EF, Muizelaar JP, et al. Definition of delayed cerebral ischemia after aneurysmal subarachnoid hemorrhage as an outcome event in clinical trials and observational studies: proposal of a multidisciplinary research group. *Stroke*. 2010;41(10):2391–5.
- 6 Bejjani GK, Sekhar LN, Yost AM, Bank WO, Wright DC. Vasospasm after cranial base tumor resection: pathogenesis, diagnosis, and therapy. *Surg Neurol*. 1999;52(6):577–4.
- 7 Bejjani GK, Duong DH, Kalamirides M, Ziyal I, Sullivan BJ. Cerebral vasospasm after tumor resection. A case report. *Neurochirurgie*. 1997;43(3):164–8.
- 8 Afshari FT, Fitzgerald JJ, Higgins JN, Garnett MR, Fernandes HM, Santarius T. Diffuse cerebral vasospasm following resection of a hypoglossal schwannoma in a child. *Br J Neurosurg*. 2014;28(4):541–3.
- 9 Dalvi N, Jacob C, Karkare S. Pt-03 prolonged vasospasm following posterior fossa tumor resection- a case report. *Neuro Oncol*. 2014;16(Suppl 5):v175.
- 10 Jacob JT, Hunt CH, Wijdevicks EF, Rabinstein AA, Cloft H, Link MJ. Diffuse cerebral vasospasm after resection of a posterior fossa ependymoma. *Neurocrit Care*. 2011;14(1):86–90.
- 11 Makkat S, Vandevenne JE, Verswijvel G, Ijsewijn T, Grieten M, Palmers Y, et al. Signs of acute stroke seen on fluid-attenuated inversion recovery MR imaging. *AJR Am J Roentgenol*. 2002;179(1):237–43.
- 12 Mills JN, Mehta V, Russin J, Amar AP, Rajamohan A, Mack WJ. Advanced imaging modalities in the detection of cerebral vasospasm. *Neurol Res Int*. 2013;2013:415960.
- 13 Connolly ES Jr, Rabinstein AA, Carhuapoma JR, Derdeyn CP, Dion J, Higashida RT, et al. Guidelines for the management of aneurysmal subarachnoid hemorrhage: a guideline for healthcare professionals from the American Heart Association/American Stroke Association. *Stroke*. 2012;43(6):1711–37.
- 14 Winblad B. Piracetam: a review of pharmacological properties and clinical uses. *CNS Drug Rev*. 2005;11(2):169–82.
- 15 Lee Y, Zuckerman SL, Mocco J. Current controversies in the prediction, diagnosis, and management of cerebral vasospasm: where do we stand? *Neurol Res Int*. 2013;2013:373458.