

## One case report of delayed severe intracerebral and intraventricular hemorrhage after cranioplasty

Zongyu Xiao

To cite this article: Zongyu Xiao (2020): One case report of delayed severe intracerebral and intraventricular hemorrhage after cranioplasty, British Journal of Neurosurgery, DOI: [10.1080/02688697.2020.1859093](https://doi.org/10.1080/02688697.2020.1859093)

To link to this article: <https://doi.org/10.1080/02688697.2020.1859093>



Published online: 11 Dec 2020.



Submit your article to this journal [↗](#)



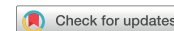Article views: 24



View related articles [↗](#)




View Crossmark data [↗](#)



NEUROSURGICAL IMAGE

## One case report of delayed severe intracerebral and intraventricular hemorrhage after cranioplasty

Zongyu Xiao 

Department of Neurosurgery, Affiliated Hospital of Qinghai University, Xining, China

### ABSTRACT

**Background:** Cranioplasty is a relatively simple neurosurgical procedure, and common complications of cranioplasty include dural tears, CSF leakage, infection, epilepsy, epidural hematoma and bone flap resorption. Intracerebral hemorrhage as a complication of cranioplasty is rare, and it is often fatal. The report describes one case of delayed severe intracerebral and intraventricular hemorrhage after an uneventful cranioplasty.

**Case presentation:** A previously healthy 29-year-old man was admitted to our hospital with a traumatic left frontotemporoparietal acute subdural hematoma, an emergency decompressive craniectomy with clot removal was performed. Four months after the surgery, cranioplasty was performed with a titanium mesh, the surgery was uneventful. Six hours after the operation, a CT scan demonstrated no bleeding or edema. In the following 2 days after cranioplasty, the patient did not have any neurological deficits, normal blood pressure was recorded every day, no trauma occurred, and routine laboratory test results were within normal limits. However, on the third day after cranioplasty, the patient suffered a sudden severe headache while playing games on his mobile phone, and then rapidly fell into deep coma; both pupils were fixed and dilated at 5 mm with no response to light. An immediate CT scan revealed a massive intracerebral hematoma and intraventricular hematoma on the left side, and the midline shifted to the right side. Therefore, an ipsilateral decompressive craniectomy was performed with evacuation of the hematoma; the obvious bleeding point was not identified, and no obvious vascular abnormalities were found during the operation. A CT scan on day 3 after reoperation revealed successful decompression, and CT angiography showed no vascular abnormalities. Despite all treatment measures, the patient did not regain consciousness, his neurological situation did not improve after the operation, and the patient lived in a vegetative state.

**Conclusion:** Although intracerebral and intraventricular hemorrhage after cranioplasty is extremely rare, it is often fatal. Aside from hyperperfusion and cerebral autoregulation dysfunction, traction injuries to the fragile vessels due to posttraumatic angiogenesis may also be one of the key factors of complications after cranioplasty.

### ARTICLE HISTORY

Received 22 July 2020  
Accepted 30 November 2020

### KEYWORDS

Cranioplasty; delayed intracerebral hemorrhage; intraventricular hemorrhage; hyperperfusion; sinking skin flap syndrome

### Background

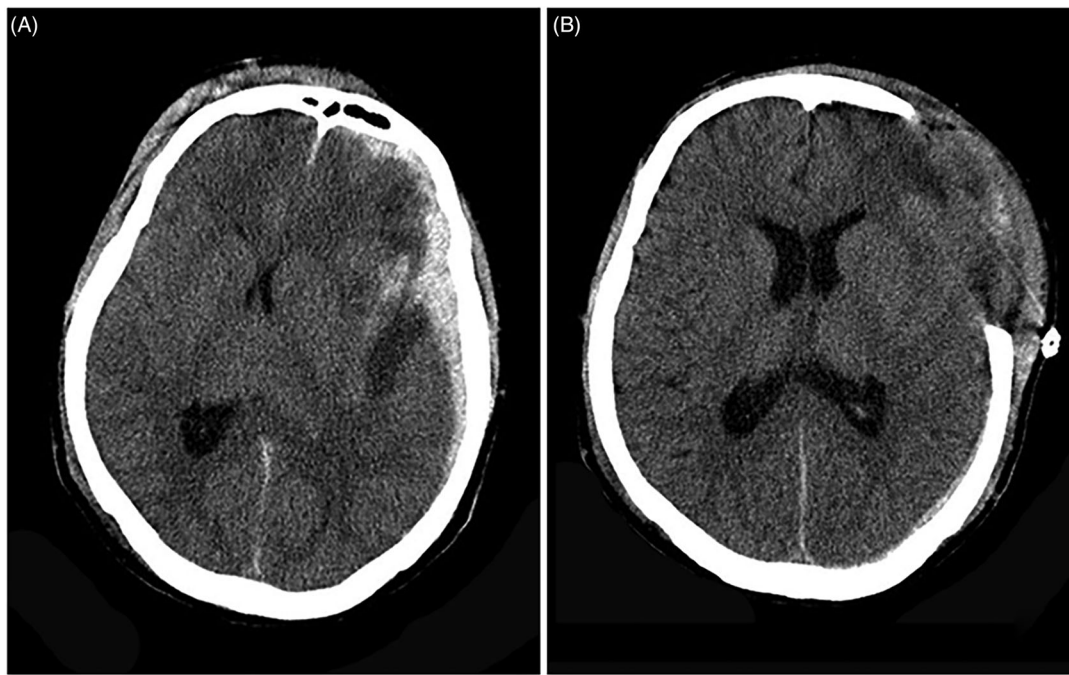
Cranioplasty is a relatively simple procedure, and common complications of cranioplasty include dural tears, cerebrospinal fluid (CSF) leakage, infection, epilepsy, epidural hematoma and bone flap resorption.<sup>1</sup> Intracerebral hemorrhage as a complication of cranioplasty is rare, and it is often fatal.<sup>2–4</sup> Here, we report the occurrence of delayed severe intracerebral and intraventricular hemorrhage following routine cranioplasty in a 29-year-old man.

### Case description

A previously healthy 29-year-old man was admitted to the Department of Neurosurgery of the Affiliated Hospital of Qinghai University after a vehicle accident on 22 July 2013. On admission, his Glasgow Coma Scale (GCS) score was 8 (E2V2M4), the pupil size of both eyes was not equal (left 5.0 mm, right 3 mm), and the pupillary reaction to light was absent. A computed tomography (CT) scan showed a left frontotemporoparietal acute subdural hematoma associated with a significant midline shift. The patient underwent an emergency

decompressive craniectomy with clot removal. The postoperative course was uneventful, and the patient regained full consciousness without any neurologic deficits one week after the surgery (Figure 1).

Four months after the surgery, the patient was admitted to our department for cranioplasty. A preoperative CT scan did not show any abnormalities except for the bony defect and some posttraumatic hypodensity area in the left frontotemporoparietal region (Figure 1A). The preoperative routine examination and laboratory tests were in the normal range. The surgery and anesthesia (90-minute duration) were uneventful, titanium mesh was used to repair the cranial defect, and a subgaleal drain was placed at the end of the surgery. The patient recovered from the surgery uneventfully; neither anticoagulation nor antiplatelet therapy was indicated during perioperative management. Six hours after the operation, a CT scan demonstrated no bleeding or edema (Figure 2B). In the following two days after cranioplasty, the patient did not have any neurological deficits, normal blood pressure was recorded every day, no trauma occurred, and routine laboratory test results were within normal limits. However, on the third day



**Figure 1.** Head CT scan, Preoperative CT scan of the head showed a left frontotemporoparietal acute subdural hematoma associated with a significant midline shift. (A), postoperative CT scan demonstrated the total removal of the subdural hematoma and the return of the midline (B).

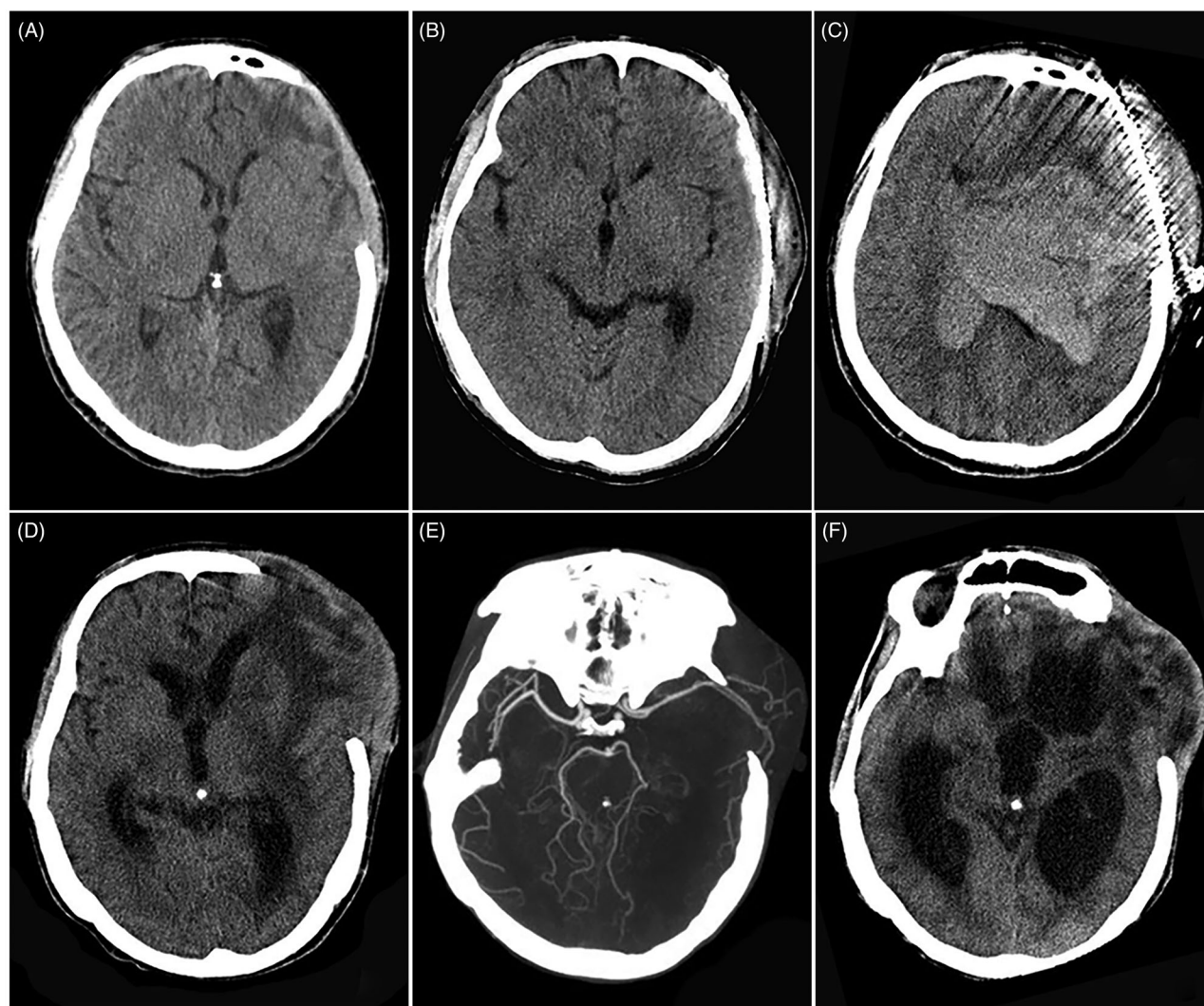
after cranioplasty, the patient suffered a sudden severe headache while playing games on his mobile phone, and then rapidly fell into a deep coma; both pupils were fixed and dilated at 5 mm with no response to light. An immediate CT scan revealed a massive intracerebral hematoma and intraventricular hematoma on the left side, and the midline shifted to the right side (Figure 2C). Therefore, an ipsilateral decompressive craniectomy was performed with evacuation of the hematoma; the obvious bleeding point was not identified, and no obvious vascular abnormalities were found during the operation. A CT scan on day 3 after reoperation revealed successful decompression (Figure 2D), and CT angiography (CTA) showed no vascular abnormalities (Figure 2E). The patient underwent tracheostomy and further intensive care unit (ICU) treatment for a few weeks. Despite all treatment measures, the patient did not regain consciousness, his neurological situation did not improve after the operation, and the patient lived in a vegetative state. Four years later, a follow-up CT scan revealed hydrocephalus and bulging of the left frontotemporal skin flap (Figure 2F), but the patient's family refused any further examination or treatment. The patient was lost to follow-up in July 2018.

## Discussion

Cranioplasty is a relatively simple procedure that is generally performed to repair a cranial defect resulting from trauma or surgery. The reported complications of cranioplasty include dural tears, CSF leakage, infection, epilepsy, epidural hematoma and bone flap resorption.<sup>1</sup> Intracerebral hemorrhage as a complication of cranioplasty is rare, and it is often fatal.<sup>2-4</sup> Causes of cerebral hemorrhage after cranioplasty include reperfusion, reduction in automatic adjustment function, sinking skin flap syndrome (SSFS), negative pressure due to subgaleal suction drainage, venous stasis, vascular damage following restoration of the midline, and allergic reaction.<sup>5</sup>

In some craniectomy patients, the atmospheric pressure and forces of gravity can be greater than the intracranial pressure, leading to a paradoxical herniation called SSFS.<sup>6</sup> Generally, the majority of these syndrome cases can be resolved via cranioplasty without any complications. However, in some rare cases after craniectomy, removal of the atmospheric pressure on the brain tissue results in reexpansion and hyperperfusion of the brain tissue inside the skull, which would lead to stretching or even rupturing of the cerebral vessels; thus, a hematoma could form. Perfusion CT or magnetic resonance imaging (MRI) after cranioplasty has demonstrated that increased cerebral blood flow and an increased blood volume could be observed not only in the ipsilateral hemisphere but also in the contralateral hemisphere. The increased cerebral perfusion could also increase the patient's risk of hemorrhage into the surrounding weak brain tissue. Therefore, postcranioplasty hemorrhage could occur not only on the surgical side but also on the contralateral side. Most instances of hemorrhage after cranioplasty have been reported on the ipsilateral side,<sup>2-4</sup> and Okumoto<sup>7</sup> reported that a small putaminal hemorrhage was found on the contralateral side on the day after cranioplasty. Moreover, the cerebellum and brain stem could also be influenced by these hemodynamic changes. Missori<sup>8</sup> reported cerebellar hemorrhage after cranioplasty. Chitale<sup>9</sup> reported both supratentorial and infratentorial hemorrhagic infarctions after cranioplasty.

Many studies have demonstrated that cerebral pressure autoregulation is impaired over a variable time course after traumatic brain injury and appears to remain impaired in a small group of severely injured patients. Impaired autoregulation may lead to decreased cerebral blood flow and metabolism when bone is deficient. After cranioplasty, the artificial bone protects the brain from atmospheric pressure, and these patients cannot respond in a timely manner to adapt to these hemodynamic changes, which may result in increased perfusion pressure; thus, brain edema or hemorrhage may occur.<sup>10</sup>



**Figure 2.** CT scans of the pre- and post-hemorrhage onset of the patient. CT scan showed the bony defect before cranioplasty (A). Six hours after cranioplasty, a CT scan demonstrated no bleeding or edema (B), but a massive intracerebral and intraventricular hemorrhage was found 3 days after cranioplasty (C). CT scan on day 3 after reoperation revealed successful decompression (D), and CTA demonstrated no vascular abnormalities (E). A follow-up CT scan revealed hydrocephalous and bulging of the left frontotemporal skin flap (F).

Placing an epidural drain with a vacuum suction system after cranioplasty may further decrease the intracranial pressure and cause subsequent rapid expansion of the brain and shifting of the midline, which may impair autoregulation and lead to reperfusion injury.<sup>11,12</sup> Sviri<sup>12</sup> reported on four patients who underwent cranioplasty after decompressive craniectomy, all of whom were treated with a closed vacuum suction system that was placed under the scalp and kept open at the end of the cranioplasty procedure. All of the patients suffered from massive brain edema and died. Hettige<sup>13</sup> thought that allergic reactions to titanium were another important cause of severe postoperative cerebral edema after cranioplasty. Shimizu<sup>14</sup> reported one case of cerebral swelling caused by deep venous thrombosis immediately after cranioplasty.

Almost all reported cases of intracerebral hemorrhage occurred on the day after cranioplasty.<sup>2-4</sup> The present case was different; the patient was healthy before the operation, no trauma occurred, and the results of the physical examination and all of the laboratory tests were in the normal range. Additionally, neither anticoagulation nor antiplatelet therapy was administered during perioperative management, so we ruled out the possibility of bleeding caused by trauma, hypertension and coagulation

dysfunction. We did place a subgaleal drain during the operation, but we did not connect it to a closed vacuum suction system; a normal subgaleal drain seems to not be the reason for the bleeding. Although the operative and postoperative CTA findings confirmed that there were no vascular abnormalities, we cannot be certain whether there was a potential aneurysm before the operation that may have been removed along with the hematoma. Furthermore, it is important to note that as the patient had a history of brain trauma and subsequent cranial surgery, there may have been some adhesions due to scar tissue, and posttraumatic angiogenesis around the damaged brain tissue may have created some fragile blood vessels.<sup>15</sup> During the cranioplasty procedure, elevating the scalp flap from the underlying dura may cause some mild damage to these fragile vessels. The patient's blood pressure may have increased while playing games on his mobile phone on the third day after cranioplasty. Combined with hyperperfusion and cerebral autoregulation dysfunction, these mildly damaged, fragile vessels would have been more likely to rupture, causing the delayed hematoma.

Therefore, based on the mechanism described above, we consider the most likely reason for the delayed intracerebral and intraventricular hemorrhage to be a combination of different



factors; aside from hyperperfusion and cerebral autoregulation dysfunction, the traction injuries to the fragile vessels due to posttraumatic angiogenesis may also be one of the key factors of complications after cranioplasty. Therefore, we suggest that surgeons should dissect the scalp flap as gently as possible to avoid any traction injuries to the brain tissue underlying the dura in the cranioplasty procedure.

## Conclusion

Although intracerebral and intraventricular hemorrhage after cranioplasty is extremely rare, it is often fatal. Aside from hyperperfusion and cerebral autoregulation dysfunction, traction injuries to the fragile vessels due to posttraumatic angiogenesis may also be one of the key factors of complications after cranioplasty.

## Ethics approval

The study was approved by the Research Ethics Committee of the Affiliated Hospital of Qinghai University.

## Informed consent

Written informed consent was obtained from the patient's family.

## Disclosure statement

No potential conflict of interest was reported by the author(s).

## ORCID

Zongyu Xiao  <http://orcid.org/0000-0002-3678-1086>

## References

1. Zhang X, Pan B, Ye Z, Li Z, Mo F, Wang X. Massive brain swelling after cranioplasty: a case report. *J Neurol Surg A Cent Eur Neurosurg* 2019;80:498–502.
2. Cecchi PC, Rizzo P, Campello M, *et al.* Haemorrhagic infarction after autologous cranioplasty in a patient with sinking flap syndrome. *Acta Neurochir (Wien)* 2008;150:409–10.
3. Han JH, Lee MS. Intracerebral hemorrhagic infarction after cranioplasty in a patient with sinking skin flap syndrome. *Korean J Neurotrauma* 2016;12:152–5.
4. Wen G, Zeng P, Zhou J, *et al.* Unexpected intracranial hemorrhage and death after cranioplasty in a patient with massive hemispheric infarction. *J Craniofac Surg* 2019;30:e378–80.
5. Kato A, Morishima H, Nagashima G. Unexpected complications immediately after cranioplasty. *Acute Med Surg* 2017;4:316–21.
6. Sarov M, Guichard J-P, Chibarro S, *et al.* Sinking skin flap syndrome and paradoxical herniation after hemicraniectomy for malignant hemispheric infarction. *Stroke* 2010;41:560–2.
7. Okumoto T, Oji T, Kishi K. Cranioplasty after decompressive craniectomy caused an intracerebral hemorrhage: a case report. *MPS* 2015;05:28–33.
8. Missori P, Currà A, Peschillo S, Fattapposta F, Toni D. Intracerebral hemorrhage after cranioplasty: an unpredictable treacherous complication due to reperfusion or possible systemic inflammatory response syndrome. *Neurol Sci* 2018;39:959–60.
9. Chitale R, Tjoumakaris S, Gonzalez F, *et al.* Infratentorial and supratentorial strokes after a cranioplasty. *Neurologist* 2013;19:17–21.
10. Kwon SM, Cheong JH, Kim JM, *et al.* Reperfusion injury after autologous cranioplasty in a patient with sinking skin flap syndrome. *J Korean Neurosurg Soc* 2012;51:117–9.
11. Lee GS, Park SQ, Kim R, *et al.* Unexpected severe cerebral edema after cranioplasty: case report and literature review. *J Korean Neurosurg Soc* 2015;58:76–8.
12. Sviri GE. Massive cerebral swelling immediately after cranioplasty, a fatal and unpredictable complication: report of 4 cases. *J Neurosurg* 2015;123:1188–93.
13. Hettige S, Norris JS. Mortality after local allergic response to titanium cranioplasty. *Acta Neurochir* 2012;154:1725–6.
14. Shimizu Y, Tsuchiya K, Fujisawa H. Cerebral swelling caused by deep venous thrombosis immediately after cranioplasty. *Br J Neurosurg* 2020; 1–4. [Epub ahead of print]. <https://doi.org/10.1080/02688697.2020.1716948>.
15. Ma L, Chen Y-L, Yang S-X, Wang Y-R. Delayed intracerebral hemorrhage secondary to ventriculoperitoneal shunt: a case report and literature review. *Medicine (Baltimore)* 2015;94:e2029.