

Neurocase

The Neural Basis of Cognition

ISSN: (Print) (Online) Journal homepage: <https://www.tandfonline.com/loi/nncs20>

A brain origin for factitious disorder (Munchausen's) with malingering? A single case with an old frontal lobe lesion

Jan Adriaan Coebergh , Aliza Amlani , Mark Edwards , Yee-Haur Mah & Niruj Agrawal

To cite this article: Jan Adriaan Coebergh , Aliza Amlani , Mark Edwards , Yee-Haur Mah & Niruj Agrawal (2020): A brain origin for factitious disorder (Munchausen's) with malingering? A single case with an old frontal lobe lesion, *Neurocase*, DOI: [10.1080/13554794.2020.1858110](https://doi.org/10.1080/13554794.2020.1858110)

To link to this article: <https://doi.org/10.1080/13554794.2020.1858110>



Published online: 11 Dec 2020.



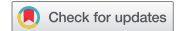Submit your article to this journal [↗](#)



View related articles [↗](#)



View Crossmark data [↗](#)



A brain origin for factitious disorder (Munchausen's) with malingering? A single case with an old frontal lobe lesion

Jan Adriaan Coebergh^{a,b}, Aliza Amlani^b, Mark Edwards^c, Yee-Haur Mah^{d,e} and Niruj Agrawal^f

^aDepartment of Neurology, Ashford St. Peter's Hospital NHS Foundation Trust, Chertsey, UK; ^bDepartment of Neurology, St. George's Hospital, London, UK; ^cNeuroscience Research Group, Institute of Molecular and Clinical Sciences, St George's University of London, London, UK; ^dKing's College Hospital NHS Foundation Trust, London, UK; ^eSchool of Biomedical Engineering & Imaging Sciences, KCL, London, UK; ^fDepartment of Neuropsychiatry, St George's Hospital NHS Foundation Trust, London, UK

ABSTRACT

We describe a patient who presented with gender identity dysphoria and stroke-like symptoms who was diagnosed with Munchausen's syndrome (factitious disorder). We discuss whether a brain lesion in the left frontal cortex is a possible risk factor, and support this hypothesis through neuropsychological investigation, EEG abnormalities, and a personality assessment. This case report supports previous suggestions that underlying brain disease/lesions might be risk factors for Munchausen's syndrome (factitious disorder).

ARTICLE HISTORY

Received 7 October 2020
Accepted 26 November 2020

KEYWORDS

Brain lesion; factitious disorder (Munchausen's); EEG; malingering

Case description

A 50 year old man presented with a headache followed by left-sided paralysis of arm and leg and was initially treated as a possible stroke. He reported that he recently arrived in the United Kingdom from another country intending to study for a PhD (doctorate degree). He said he had been prescribed hormonal medication as part of gender reassignment by a General Practitioner at the airport. He requested to wear a pink hospital gown and to be called by a female forename. Due to single-sex hospital bays in the hospital, he was given a private side room. His MRI head showed an old left frontal lesion with increased signal on gradient echo, consistent with his reported history of a previous head injury. His limb weakness was variable and Hoover's sign was positive. He reported he previously ran a head injury charity and had been active in politics. On day four a neurologist discussed the clinical suspicion of functional neurological symptoms and the need for more evidence before starting hormonal medication. There was no next of kin available for collateral history nor location Yushkevich of discharge. After looking up his (later deleted) profile on Wikipedia we asked him about previous convictions for fraud mentioned on the profile, and for more details about his PhD. There were numerous inconsistencies in the details provided by him, leading us to the conclusion that they were untrue. When made aware of the possibility of having to pay for health-care costs as a non-UK resident he self-discharged after 10 days having regained full neurological function. We became aware that in the next two months he visited at least four hospitals in the area with similar symptoms, and received thrombolysis for suspected stroke on multiple occasions and admissions often lasted about a week to 10 days. During one of the later admissions Electroencephalography (EEG) was carried out which showed frontal slow waves and a neuropsychological assessment was done. When he was seen by one of the authors (who had also met him in another

hospital) he refused to discuss his recent contacts with health services and turned down an in-depth explanation of the MRI, EEG, and neuropsychological findings and self-discharged. He has not re-attended since. In the seven years since he has remained active as a male on publicly available internet sites.

Investigation results

He completed a gender identity/dysphoria (GID) questionnaire for adolescents and adults (GIDYQ-AA). He scored an average of 2.41 on the 27 questions (Always-Often-Sometimes-Rarely-Never; 1–5); the lower the score the more gender identity dysphoria (For the GIDYQ-AA mean score a cut-point of 3.00 showed sensitivity of 90% for the GID adults, and specificity was 100% for the control adults) (Singh et al., 2010).

During detailed neuropsychological testing he was highly sociable and appeared very engaged and motivated to do well. He passed a test of effort. His verbal comprehension was on the 75th percentile, perceptual reasoning and organization 92nd percentile, working memory and concentration 42nd percentile, and speed of information processing 34th percentile. There was no memory or executive impairment. He self-reported moderate levels of anxiety and no symptoms of depression.

On a 320 item of personality structure (Morey & McCredie, 2019) which includes indices of response consistency, impression management, and a range of validity indicators, alongside numerous clinical scales he showed significant elevation on the paranoia index denoting increased vigilance for monitoring the environment for potential harm; a tendency to be resentful and hold grudges and a readiness to spot inequities in the way he has been treated. He also had markedly elevated scores on the dominance index on the interpersonal scale. The interpretative manual suggests the person may be driven to appear competent and authoritative but others might view them as

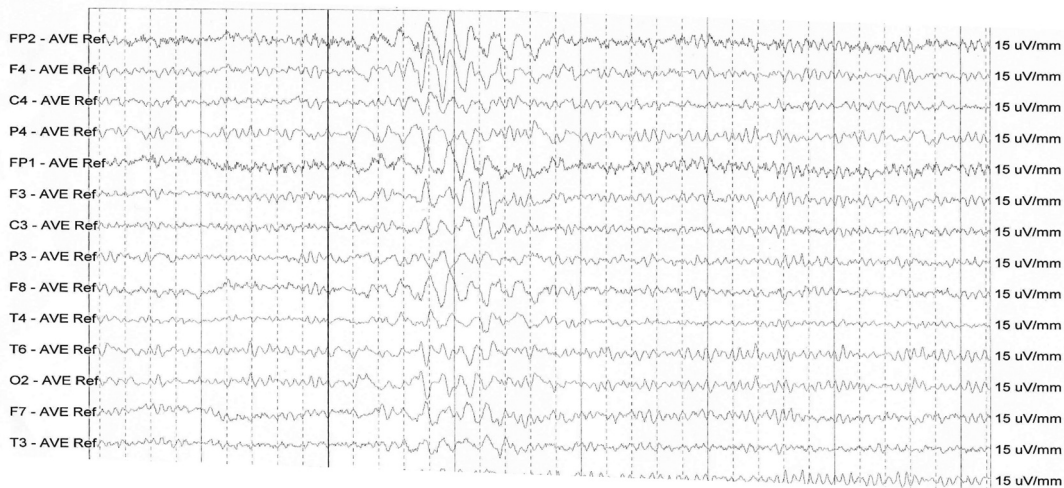


Figure 1. EEG at rest.

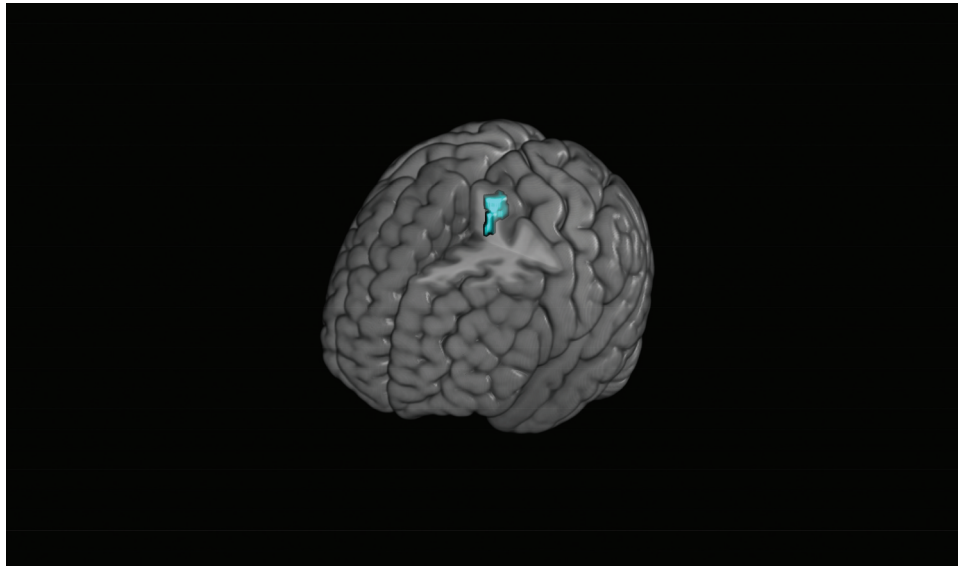


Figure 2. Lesion in blue.

overbearing and self-important. There was some elevation on a mania scale suggesting restlessness and impulsivity; otherwise, all indices were within normal ranges.

EEG at rest showed fairly frequent intermittent burst of high amplitude irregular slow waves sometimes intermixed with sharp components over the right fronto-temporal and fronto-parietal regions. It was occasionally bilateral but more prominent on the right.

The lesion was segmented using the original CT brain image and the program ITK (Insight Segmentation and Registration Toolkit)-snap (Yushkevich et al., 2006). The original CT scan was signal adjusted prior to spatial normalization using a reversible transformation (Rorden et al., 2012). The signal processed CT brain image was spatially normalized using the combined segmentation-normalization routine in Statistical Parametric Mapping (SPM)12, with the derived normalization parameters used to transform the original CT brain image and segmented lesion mask into MNI (Montreal Neurological Institute) space. The images provided were created using mricroGL.

The Talairach (Lancaster et al., 2000) location is z 55–69. The location of the lesion lies within the region of x-14; y-8; z61 which would place it in the left superior frontal gyrus/paracentral lobule. The lesion involves 1.03% of the total superior frontal gyrus and 2.26% of the total supplementary motor cortex in the left hemisphere. The volume of the lesion is 0.832 cm^3 (Du et al., 2006)

Discussion

Munchausen's syndrome (factitious disorder) was first defined by Richard Asher as a syndrome where a person repeatedly presents to hospital with a dramatic illness history made up of falsehoods, after which he or she discharges themselves against advice (Asher, 1951). According to DSM V; the latest diagnostic criteria, patients with Munchausen's (factitious disorder) intentionally produce physical or psychological symptoms with the sole motivation of assuming the sick role

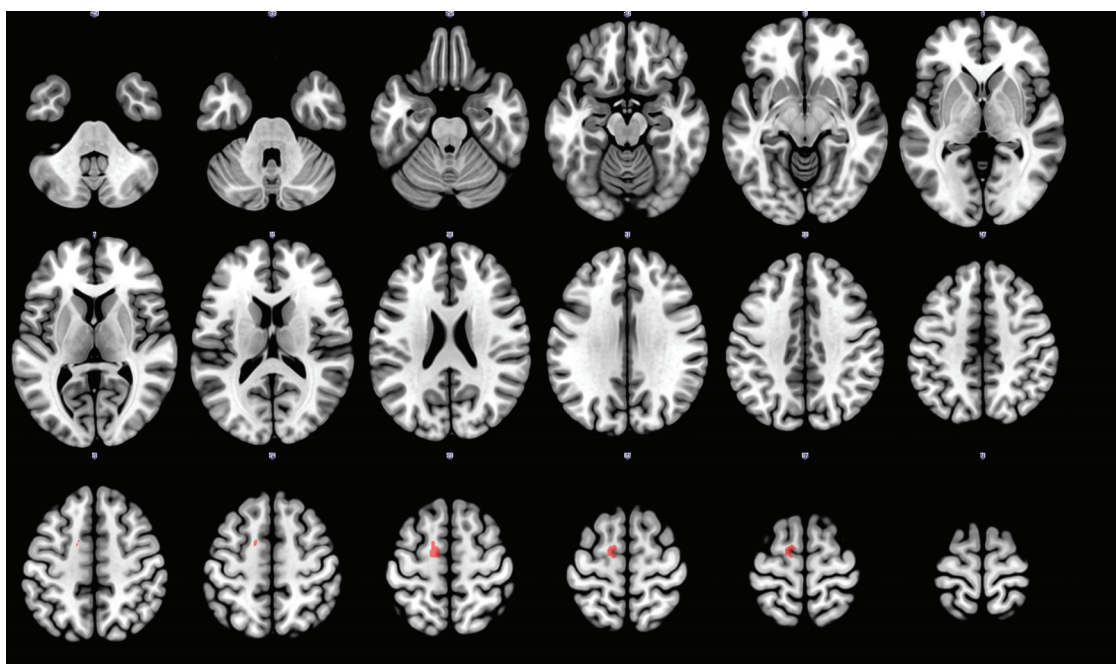


Figure 3. Lesion in red.

((C. C. Bass & Halligan, 2016; Christopher Christopher Bass & Halligan, 2014; Kanaan & Wessely, 2010)). It is difficult to be sure the diagnosis in this case was not malingering since a degree of gain in the form of free accommodation and food was present. It is therefore possible there is an overlap between the two diagnoses. To our knowledge feigning a desire to have gender reassignment has not previously been described as a presentation, but the obvious benefit of it was a private room.

Although there is little understanding of the pathogenesis of Munchausen's syndrome (factitious disorder) (Yates & Feldman, 2016) advances in imaging mean that identifying brain pathology is possible. Relevant to this, the neurological basis of lying has been studied using fMRI. The prefrontal cortex is strongly activated during lying (Yang et al., 2005). It has been shown that the right anterior prefrontal cortex (aPFC) is more involved in lies that are well rehearsed, whereas the anterior cingulate cortex (aCC) is more active during spontaneous generation of non-memorized lies (Lee et al., 2002). Langleben and others (Langleben et al., 2002) observed increased activity in the superior frontal gyrus and anterior cingulate cortex in deception.

Pathological liars without antisocial traits were found to have a 22% increase in prefrontal white matter and a 14% reduction in prefrontal gray matter compared to healthy controls (Yang et al., 2005). Further studies have shown an increase in white matter in the orbitofrontal, inferior frontal, middle frontal, and superior frontal cortices in pathological liars (Yang et al., 2007). The question of whether preexisting differences in the prefrontal structure cause increasingly deceptive behavior or whether the act of lying increases the white matter volume in this region of the brain remains unanswered (Bengtsson et al., 2005).

Literature relating to factitious disorder has alluded to the possibility of "organic" causes including by Asher in 1953

(Asher, 1951). In one case, bilateral fronto-temporal atrophy preceded the behavior (Babe et al., 1992). King and Ford described that 40% of patients with pseudologia fantastica had a history of brain abnormality; 15% had primary epilepsy and 7% had an abnormal EEG, previous brain infection, or head trauma (King & Ford, 1988).

Our patient presented with seemingly intentionally induced neurological and psychological symptoms which quickly improved when challenged, and subsequent similar presentation to other hospitals. His presentation is consistent with Munchausen's syndrome (factitious disorder). In our patient, we can suggest that the personality traits of high dominance and paranoia are possible contributors to this behavior (Baek et al., 2017). However, he also had evidence of mainly right fronto-parietal and fronto-temporal slowing on EEG and a lesion of the left superior frontal gyrus. These are areas highlighted in lying and (self-) deception studies. It must be noted that superior frontal gyrus/supplementary motor area function is altered in functional neurological disorder (FND) where there is impaired awareness of motor intention (Baek et al., 2017; Voon et al., 2011) and our patient had positive signs for this (Hoover's sign (McWhirter et al., 2011)). Two cases of supplementary motor area (SMA) strokes presenting with signs of contralateral functional neurological disorder have been published (inconsistent weakness and positive clinical signs) (Mathew et al., 2018; Mohebi et al., 2019). It must be noted that in our patient the weakness was ipsilateral. The SMA has also been associated with a loss of self-awareness during competing sensorimotor activity (Goldberg et al., 2006) One can wonder about self-awareness of the deception in our patient. This literature demonstrates that self-awareness of movement is a continuum and a simple involuntary versus voluntary dichotomy might not be sustainable. For example, FND/dissociative seizures as a rule are perceived as involuntary but we

have met patients that acknowledge inducing symptoms when, as so often, they are not taken seriously (willful exaggeration).

It is possible that the brain lesion described in this patient has the potential to disturb widespread cortical and sub-cortical networks. We note that although incidental EEG abnormalities in healthy people are relatively common, intermittent significant frontal slowing is an unusual incidental finding. It superficially supports the theory that the frontal lobe brain lesion may have led to an alteration in brain function in this person. Future exploration through functional studies and structural and functional connectivity analysis might help us understand the pathophysiology of Munchausen's syndrome (factitious disorder).

We have to be modest however in linking an area of brain damage to altered behavior decades later but the notion that brain pathology could be a risk factor for Munchausen's syndrome (factitious disorder) and malingering is potentially important with regards to the often complex management and societal/health care professional attitudes toward such patients.

Disclosure statement

No potential conflict of interest was reported by the authors.

References

- Asher, R. (1951). Munchausen's syndrome. *The Lancet*, 257(6650), 339–341. [https://doi.org/10.1016/S0140-6736\(51\)92313-6](https://doi.org/10.1016/S0140-6736(51)92313-6)
- Babe, K. S., Peterson, A. M., Loosen, P. T., & Geraciotti, T. D. (1992). The pathogenesis of Munchausen syndrome a review and case report. *General Hospital Psychiatry*, 14(4), 273–276. [https://doi.org/10.1016/0163-8343\(92\)90098-U](https://doi.org/10.1016/0163-8343(92)90098-U)
- Baek, K., Doñamayor, N., Morris, L. S., Strelchuk, D., Mitchell, S., Mikheenko, Y., Yeoh, S. Y., Phillips, W., Zandi, M., Jenaway, A., Walsh, C., & Voon, V. (2017). Impaired awareness of motor intention in functional neurological disorder: Implications for voluntary and functional movement. *Psychological Medicine*, 47(9), 1624–1636. <https://doi.org/10.1017/S0033291717000071>
- Bass, C., & Halligan, P. (2016). Factitious disorders and malingering in relation to functional neurologic disorders. In Mark Hallett, & Jon Stone (Eds.), *Handbook of clinical neurology* (pp. 509–520). Alan Carson Academic Press. <https://doi.org/10.1016/B978-0-12-801772-2.00042-4>
- Bass, C., & Halligan, P. (2014). Factitious disorders and malingering: Challenges for clinical assessment and management. *The Lancet*, 383(9926), 1422–1432. [https://doi.org/10.1016/S0140-6736\(13\)62186-8](https://doi.org/10.1016/S0140-6736(13)62186-8)
- Bengtsson, S. L., Nagy, Z., Skare, S., Forsman, L., Forssberg, H., & Ullén, F. (2005). Extensive piano practicing has regionally specific effects on white matter development. *Nature Neuroscience*, 8, 1148–1150. <https://doi.org/10.1038/nn1516>
- Du, B. F., Levy, R., Volle, E., Seassau, M., Duffau, H., Kinkingnehun, S., ... Dubois, B. (2006). Functions of the left superior frontal gyrus in humans: A lesion study. *Brain*, 129(Pt 12):3315–28. <https://doi.org/10.1093/brain/awl244>
- Goldberg, I. I., Harel, M., & Malach, R. (2006). When the brain loses its self: Prefrontal inactivation during sensorimotor processing. *Neuron*, 50(2), 329–339. <https://doi.org/10.1016/j.neuron.2006.03.015>
- Kanaan, R. A. A., & Wessely, S. C. (2010). Factitious disorders in neurology: An analysis of reported cases. *Psychosomatics*, 51(1), 47–54. [https://doi.org/10.1016/S0033-3182\(10\)70658-7](https://doi.org/10.1016/S0033-3182(10)70658-7)
- King, B. H., & Ford, C. V. (1988). Pseudologia fantastica. *Acta psychiatrica Scandinavica*, 77(1), 1–6. <https://doi.org/10.1111/j.1600-0447.1988.tb05068.x>
- Lancaster, J. L., Woldorff, M. G., Parsons, L. M., Liotti, M., Freitas, C. S., Rainey, L., Kochunov, P. V., Nickerson, D., Mikiten, S. A., & Fox, P. T. (2000). Automated Talairach Atlas labels for functional brain mapping. *Human Brain Mapping*, 10(3), 120–131. [https://doi.org/10.1002/1097-0193\(200007\)10:3<120::AID-HBM30><120::AID-HBM30>3.0.CO;2-8](https://doi.org/10.1002/1097-0193(200007)10:3<120::AID-HBM30><120::AID-HBM30>3.0.CO;2-8)
- Langleben, D. D., Schroeder, L., Maldjian, J. A., Gur, R. C., McDonald, S., Ragland, J. D., ... Childress, A. R. (2002). Brain activity during simulated deception: An event-related functional magnetic resonance study. *NeuroImage*, 15(3). <https://doi.org/10.1006/nimg.2001.1003>
- Lee, T. M. C., Liu, H. L., Tan, L. H., Chan, C. C. H., Mahankali, S., Feng, C. M., Hou, J., Fox, P. T., & Gao, J. H. (2002). Lie detection by functional magnetic resonance imaging. *Human Brain Mapping*, 15(3), 157–164. <https://doi.org/10.1002/hbm.10020>
- Mathew, P., Batchala, P. P., & Eluvathingal Muttikkal, T. J. (2018). Supplementary motor area stroke mimicking functional disorder. *Stroke*, 49, e28–e30. <https://doi.org/10.1161/STROKEAHA.117.019106>
- McWhirter, L., Stone, J., Sandercock, P., & Whiteley, W. (2011). Hoover's sign for the diagnosis of functional weakness: A prospective unblinded cohort study in patients with suspected stroke. *Journal of Psychosomatic Research*, 71(6), 384–386. <https://doi.org/10.1016/j.jpsychores.2011.09.003>
- Mohebi, N., Arab, M., Moghaddasi, M., Behnam Ghader, B., & Emamikhah, M. (2019). Stroke in supplementary motor area mimicking functional disorder: A case report. *Journal of Neurology*, 266(10), 2584–2586. <https://doi.org/10.1007/s00415-019-09479-7>
- Morey, L. C., & McCredie, M. N. (2019). Personality assessment inventory. In Martin Sellbom, & Julie A. Suhr (Eds.), *The Cambridge handbook of clinical assessment and diagnosis*. Cambridge University Press. <https://doi.org/10.1017/9781108235433.017>
- Rorden, C., Bonilha, L., Fridriksson, J., Bender, B., & Karnath, H. O. (2012). Age-specific CT and MRI templates for spatial normalization. *NeuroImage*, 61(4), 957–965. <https://doi.org/10.1016/j.neuroimage.2012.03.020>
- Singh, D., Deogracias, J. J., Johnson, L. L., Bradley, S. J., Kibblewhite, S. J., Owen-Anderson, A., Peterson-Badali, M., Meyer-Bahlburg, H. F. L., & Zucker, K. J. (2010). The gender identity/gender dysphoria questionnaire for adolescents and adults: Further validity evidence. *Journal of Sex Research*, 47(1), 49–58. <https://doi.org/10.1080/00224490902898728>
- Voon, V., Brezing, C., Gallea, C., & Hallett, M. (2011). Aberrant supplementary motor complex and limbic activity during motor preparation in motor conversion disorder. *Movement Disorders*, 26(13), 2396–2403. <https://doi.org/10.1002/mds.23890>
- Yang, Y., Raine, A., Lencz, T., Bihle, S., Lacasse, L., & Colletti, P. (2005). Prefrontal white matter in pathological liars. *British Journal of Psychiatry*, 187(4), 320–325. <https://doi.org/10.1192/bjp.187.4.320>
- Yang, Y., Raine, A., Narr, K. L., Lencz, T., LaCasse, L., Colletti, P., & Toga, A. W. (2007). Localisation of increased prefrontal white matter in pathological liars. *British Journal of Psychiatry*, 190(2), 174–175. <https://doi.org/10.1192/bjp.bp.106.025056>
- Yates, G. P., & Feldman, M. D. (2016). Factitious disorder: A systematic review of 455 cases in the professional literature. *General Hospital Psychiatry*, 41, 20–28. <https://doi.org/10.1016/j.genhosppsych.2016.05.002>
- Yushkevich, P. A., Piven, J., Hazlett, H. C., Smith, R. G., Ho, S., Gee, J. C., & Gerig, G. (2006). User-guided 3D active contour segmentation of anatomical structures: Significantly improved efficiency and reliability. *NeuroImage*, 31(3), 1116–1128. <https://doi.org/10.1016/j.neuroimage.2006.01.015>