



Wingspan Stenting for Symptomatic Severe In-Stent Stenosis of a Closed-Cell Stent after Stent-Assisted Coiling of a Ruptured Intracranial Aneurysm

Jang Hoon Kim and Joonho Chung

Department of Neurosurgery, Yonsei University College of Medicine, Seoul, Korea.

We report the 3-year follow-up result of Wingspan intracranial stenting for symptomatic severe in-stent stenosis after stent-assisted coiling (SAC) for a ruptured left distal internal carotid artery (ICA) aneurysm. A middle-aged male patient visited our hospital for in-stent stenosis of a stent that was placed to treat a ruptured ICA aneurysm. Routine follow-up cerebral angiography, 1 year after SAC, showed in-stent stenosis around the distal markers of the inserted stent at the left M1 proximal segment. Six months later, he developed right dysesthesia. We performed intracranial stenting with Wingspan stent for the in-stent stenosis. Follow-up digital subtraction angiography performed 1 year after the Wingspan stenting showed good patency of the ICA and middle cerebral artery flow without evidence of restenosis. At 3-year follow-up, magnetic resonance angiography showed sufficient middle cerebral artery flow although the stenting segment could not be visualized clearly. Wingspan stenting might be a feasible option in patients with iatrogenic intracranial stenosis resulting from in-stent stenosis who experience the progression of intracranial stenosis with manifestation of neurological symptoms despite dual anti-platelet therapy.

Key Words: Intracranial aneurysm, stenosis, stent

INTRODUCTION

Self-expanding Wingspan stents (Stryker Neurovascular) are approved by the Food and Drug Administration as an intracranial stent for use in patients with intracranial atherosclerotic stenosis (ICAS) under the Humanitarian Device Exemption. However, Stenting and Aggressive Medical Management for Preventing Recurrent Stroke in Intracranial Stenosis (SAMMPRIS) trials and long-term outcome data have reported inferior results for Wingspan stenting for ICAS compared to the best medical practice.¹ Recent studies on Wingspan stenting for

ICAS demonstrated low periprocedural complication rates and excellent safety profile when performed by experienced interventionalists with proper patient selection, following the recommended usage guidelines.^{1,2}

In-stent stenosis is a potential concern in stent-assisted coiling (SAC) for intracranial aneurysms. Intracranial stents may exhibit flow-remodeling effects through neoendothelialization, which could result in in-stent stenosis.^{3,4} It can be diagnosed with computed tomography angiography, magnetic resonance angiography (MRA), or digital subtraction angiography (DSA). Most patients with in-stent stenosis are asymptomatic.³⁻⁵ However, some symptomatic cases require additional treatment with anti-platelet agents, angioplasty, and bypass surgery.^{4,6} There is no single case report or analysis of the long-term follow-up results of in-stent stenosis treated by the Wingspan stent. Moreover, there is no existing guideline for the treatment of symptomatic in-stent stenosis cases.

Herein, we report the long-term follow-up result of a patient who was treated with the Wingspan stent for symptomatic in-stent stenosis of a closed-cell stent, which was implanted during SAC of a ruptured intracranial aneurysm. This use circumvented its on-label indication of symptomatic iatrogenic intracranial

Received: August 20, 2020 **Revised:** September 25, 2020

Accepted: October 8, 2020

Corresponding author: Joonho Chung, MD, PhD, Department of Neurosurgery, Severance Hospital, Yonsei University College of Medicine, 50-1 Yonsei-ro, Seodaemun-gu, Seoul 03722, Korea.

Tel: 82-2-2228-2150, Fax: 82-2-393-9979, E-mail: ns.joonho.chung@gmail.com

•The authors have no potential conflicts of interest to disclose.

© Copyright: Yonsei University College of Medicine 2021

This is an Open Access article distributed under the terms of the Creative Commons Attribution Non-Commercial License (<https://creativecommons.org/licenses/by-nc/4.0>) which permits unrestricted non-commercial use, distribution, and reproduction in any medium, provided the original work is properly cited.

al stenosis.

CASE REPORT

A middle-aged person presented to our institution with transient right-side weakness. The patient was a non-smoker and did not have any past medical history, such as hypertension, diabetes, or dyslipidemia. The patient had experienced subarachnoid hemorrhage caused by a ruptured aneurysm on the left internal carotid artery (ICA) a year earlier, which was treated with SAC using a self-expanding closed-cell Enterprise stent (Codman Neurovascular) at another hospital. Diffusion-weighted imaging (DWI) at admission showed no acute infarction; DSA showed severe stenosis (90%) of the left M1 distal to the distal end of the Enterprise stent (Fig. 1). The patient was on a regimen of anti-platelet monotherapy-aspirin (100 mg/day). Clopidogrel (75 mg/day) was initiated additionally.

However, the patient experienced repeated right-side numbness and mild weakness after 8 months on dual anti-platelet therapy. The symptoms were transient but occurred twice a week. DWI showed small lesions with high signal intensity on

the left temporal lobe (Fig. 2A). A follow-up DSA showed severe in-stent stenosis of the left M1 when compared to previous DSA results (Fig. 2B). Despite dual anti-platelet therapy, the patient's symptoms persisted, which warranted Wingspan stenting. Under general anesthesia, a 6-Fr guiding catheter was placed in the left ICA. A Gateway balloon (2.25×9 mm, Stryker Neurovascular) was mounted up to the left M1 using a 300-cm exchange microwire. After pre-ballooning with the Gateway balloon, a Wingspan stent (4.5×15 mm) was placed at the lesion (Fig. 2C). DSA performed immediately after stenting showed good expansion of the in-stent stenosis and sufficient distal middle cerebral artery flow (Fig. 2D). There was no procedure-related complication, and the patient was discharged without any neurological deficit.

Follow-up DSA performed 1 year after the Wingspan stenting showed good patency of the middle cerebral artery flow without evidence of restenosis (Fig. 2E). Clopidogrel was discontinued, and only aspirin monotherapy was maintained. After 2 more years of follow-up, MRA showed sufficient middle cerebral artery flow, although the stenting segment could not be visualized clearly.

Written informed consent was obtained from the patient.

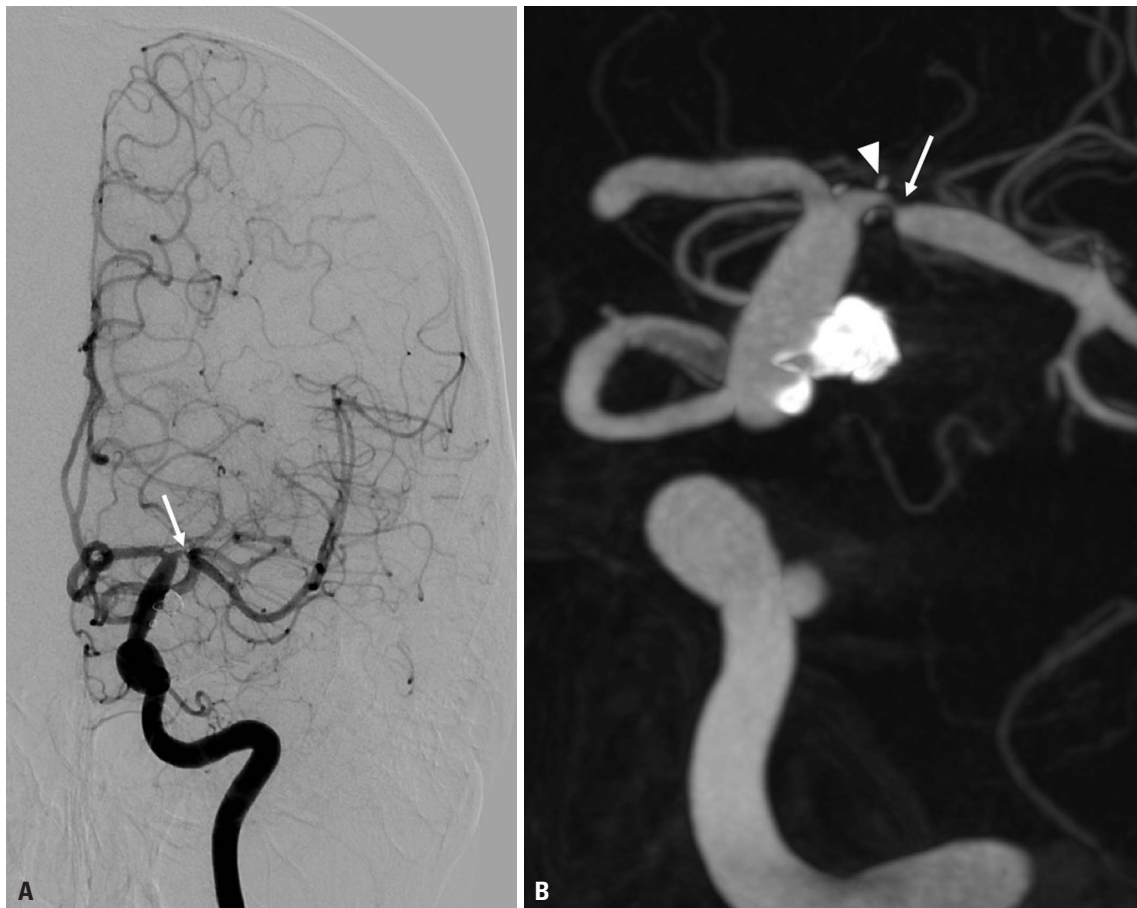


Fig. 1. Digital subtraction angiography. (A) It showed severe stenosis (90%) of the left M1 distal to the distal end of the Enterprise stent. (B) Dyna-computed tomography showed a precise relationship between the distal end of the stent and M1 stenosis. White arrow indicates the left M1 stenosis; white arrow head indicates the distal markers of the Enterprise stent.

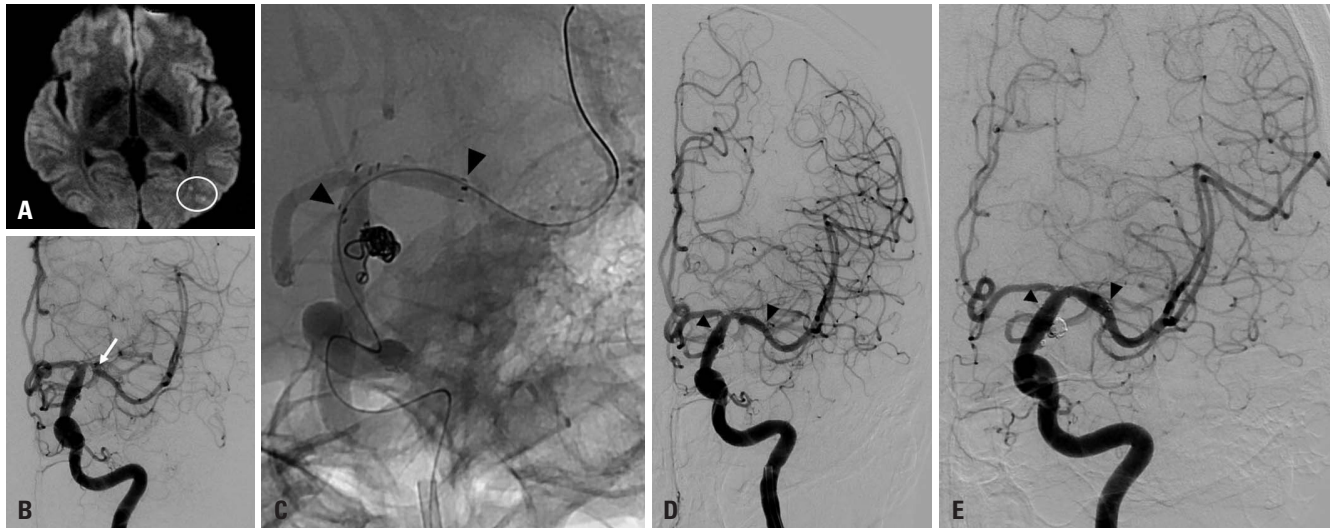


Fig. 2. Images after repeated symptoms. (A) Diffusion-weighted image shows small lesions with high signal intensity on the left temporal lobe. (B) Follow-up digital subtraction angiography (DSA) shows severe in-stent stenosis of the left M1. (C) After pre-ballooning using a Gateway balloon, a Wingspan stent (4.5×15 mm) was placed at the lesion. (D) DSA performed immediately after stenting showed good expansion of the in-stent stenosis and sufficient distal middle cerebral artery flow. (E) Follow-up DSA 1 year after Wingspan stenting showed good patency of the middle cerebral artery flow, without evidence of restenosis. White circle indicates multiple small high signal lesions; white arrow indicates the left M1 stenosis; black arrowheads indicate the proximal and distal markers of the Wingspan stent.

Table 1. List of the 6 Cases Treated for Symptomatic In-Stent Stenosis in Stents Used for Coiling of Intracranial Aneurysms

Authors	Location	Symptoms & signs	Stent used	Time of in-stent stenosis (months)	Medication before in-stent stenosis	Treatment
Fiorella et al. 2006 ⁴	Right ICA terminus	Cerebral infarction	Neuroform	3	Not mentioned	PTA & direct bypass
	Right ICA posterior wall	Transient ischemic attack	Neuroform	3	Not mentioned	PTA
Gao et al. 2010 ⁸	Right PcoA	Cerebral infarction	Neuroform	13	Not mentioned	PTA
Lee et al. 2012 ⁹	Left PcoA	Persistent headache	Neuroform	9	Dual anti-platelet therapy	PTA
Aguilar-Salinas et al. 2019 ⁷	AcoA	Transient ischemic attack	Not mentioned	6	Single anti-platelet therapy	PTA
Kim and Chung (the present case)	Left MCA (M1)	Cerebral infarction	Enterprise	12	Single anti-platelet therapy	Wingspan stent

AcoA, anterior communicating artery; ICA, internal carotid artery; MCA, middle cerebral artery; PcoA, posterior communicating artery; PTA, percutaneous transluminal balloon angioplasty.

DISCUSSION

In the present case, we reported a long-term follow-up result of Wingspan stenting for symptomatic severe in-stent stenosis of a closed-cell stent used for SAC, and Wingspan stenting showed good patency without evidence of restenosis. Since the patient did not have any risk factor for intracranial arterial stenosis, the cause of in-stent stenosis in the present case might be endothelial stimulation by the distal markers of the Enterprise in the very proximal part of M1 segment.

The incidence of in-stent stenosis is known to be approximately 2.3–7.8%, and it remains a valid concern in the case of SAC.³⁻⁶ To prevent this issue, dual anti-platelet therapy is used initially, and is subsequently changed to aspirin monotherapy,

which is maintained thereafter. If patients experienced symptoms and signs due to in-stent stenosis, there might be some treatment options, such as bypass surgery, balloon angioplasty, or intracranial stenting. However, there is no specific guideline available for treating cases of symptomatic severe in-stent stenosis. Therefore, sharing and reporting the treatment technique and result of prospective cases will be helpful to identify the appropriate treatment options in the future. In this regard, therefore, we believe the present case offers significant value.

There have been 37 reports mentioning in-stent stenosis in cases of SAC. Most were asymptomatic cases. Even in symptomatic in-stent stenosis, there were few reports on the treatment of in-stent stenosis. Since the first report in 2006, there have been 6 reported cases that were treated for symptomatic

in-stent stenosis in stents used for coiling of intracranial aneurysms (Table 1).^{4,7-9} No report has mentioned long-term follow-up result of in-stent stenosis treatment, except for the present case. Moreover, only in the present case, symptomatic in-stent stenosis by a closed-cell stent, the Enterprise stent, was treated. Furthermore, the treatment of in-stent stenosis using Wingspan stenting was reported for the first time in this report. However, further study with a longer term follow-up (of more than 3 years) DSA is needed, due to the possibility of asymptomatic restenosis of the Wingspan stent.

In the WEAVE trial,² a low periprocedural event rate of intracranial stenting was observed compared to the SAMMPRIS trial (2.6% vs. 14.7%). The trial showed the importance of experienced interventionalists and proper patient selection following the on-label usage guidelines. Compared with previous studies, the patients enrolled in the WEAVE trial had more severe stenosis (70–99%) and more than 2 qualifying strokes, were refractory to medical therapy, and were stented with Wingspan \geq 8 days after the last stroke (median time to stent, 22 days). Despite its off-label use in the present case, the treatment of symptomatic in-stent stenosis with a Wingspan stent showed good results in long-term follow-up. Therefore, we believe that the use of Wingspan stent could be a good treatment option for patients with symptomatic in-stent stenosis. The off-label use of Wingspan stent has not been studied yet; however, a detailed report of ongoing treatment results is warranted for objective assessment.

In conclusion, Wingspan stenting might be a feasible option in patients with symptomatic in-stent stenosis after SAC, despite dual anti-platelet therapy. Moreover, a good long-term patency can be expected from this treatment approach.

AUTHOR CONTRIBUTIONS

Conceptualization: Joonho Chung. **Data curation:** Jang Hoon Kim and Joonho Chung. **Investigation:** Jang Hoon Kim. **Methodology:** Jang Hoon Kim. **Project administration:** Joonho Chung. **Resources:** Joonho Chung. **Supervision:** Joonho Chung. **Validation:** Jang Hoon

Kim. Visualization: Jang Hoon Kim. **Writing—original draft:** Jang Hoon Kim. **Writing—review & editing:** Jang Hoon Kim and Joonho Chung. **Approval of final manuscript:** all authors.

ORCID iDs

Jang Hoon Kim <https://orcid.org/0000-0001-5284-7973>
 Joonho Chung <https://orcid.org/0000-0003-2745-446X>

REFERENCES

1. Chimowitz MI, Lynn MJ, Derdeyn CP, Turan TN, Fiorella D, Lane BF, et al. Stenting versus aggressive medical therapy for intracranial arterial stenosis. *N Engl J Med* 2011;365:993-1003.
2. Alexander MJ, Zauner A, Chaloupka JC, Baxter B, Callison RC, Gupta R, et al. WEAVE trial: final results in 152 on-label patients. *Stroke* 2019;50:889-94.
3. Chalouhi N, Drueding R, Starke RM, Jabbour P, Dumont AS, Gonzalez LF, et al. In-stent stenosis after stent-assisted coiling: incidence, predictors and clinical outcomes of 435 cases. *Neurosurgery* 2013;72:390-6.
4. Fiorella D, Albuquerque FC, Woo H, Rasmussen PA, Masaryk TJ, McDougall CG. Neuroform in-stent stenosis: incidence, natural history, and treatment strategies. *Neurosurgery* 2006;59:34-42.
5. Fargen KM, Hoh BL, Welch BG, Pride GL, Lanzino G, Boulos AS, et al. Long-term results of enterprise stent-assisted coiling of cerebral aneurysms. *Neurosurgery* 2012;71:239-44.
6. Kanaan H, Jankowitz B, Aleu A, Kostov D, Lin R, Lee K, et al. In-stent thrombosis and stenosis after neck-remodeling device-assisted coil embolization of intracranial aneurysms. *Neurosurgery* 2010;67:1523-32.
7. Aguilar-Salinas P, Brasiliense LB, Santos R, Cortez G, Gonsales D, Aghaebrahim A, et al. Safety and efficacy of stent-assisted coiling in the treatment of unruptured wide-necked intracranial aneurysms: a single-center experience. *Cureus* 2019;11:e4847.
8. Gao X, Liang G, Li Z, Qu H, Wei X. Stent-assisted coil embolization of wide-necked intracranial aneurysms using a semi-deployment technique: angiographic and clinical outcomes in 31 consecutive patients. *Interv Neuroradiol* 2010;16:385-93.
9. Lee JH, Yun JK, Kim DW, Kang SD. Clinical and angiographic outcomes of wingspan stent placement for treatment of symptomatic intracranial stenosis: single center experience with 19 cases. *J Cerebrovasc Endovasc Neurosurg* 2012;14:157-63.