

Received: 2020.06.02


Accepted: 2020.10.28

Available online: 2020.11.10

Published: 2021.01.05

# Endovascular Therapy for Childhood Ischemic Stroke

## Authors' Contribution:

Study Design A  
Data Collection B  
Statistical Analysis C  
Data Interpretation D  
Manuscript Preparation E  
Literature Search F  
Funds Collection GACDEF 1 **Malik Ghannam**  
BE 2 **Lara Zakarna**  
BE 3 **Issa Alawneh**  
BDE 4 **Mustafa Al-Chalabi**  
ACDF 5 **Daniel Kenney-Jung**1 Department of Neurology, University of Minnesota, Minneapolis, MN, U.S.A.  
2 Department of Neuroscience, An-Najah National University Teaching Hospital, Nablus, Palestine  
3 Department of Pediatric Neurology, The Hospital for Sick Children, University of Toronto, Toronto, ON, Canada  
4 Department of Neurology, University of Toledo, Toledo, OH, U.S.A.  
5 Department of Pediatric Neurology, University of Minnesota, Minneapolis, MN, U.S.A.**Corresponding Author:** Malik Ghannam, e-mail: [mghannam@umn.edu](mailto:mghannam@umn.edu)**Conflict of interest:** None declared**Patient:** Female, 7-year-old  
**Final Diagnosis:** Stroke  
**Symptoms:** Aphasia  
**Medication:** —  
**Clinical Procedure:** —  
**Specialty:** Neurology**Objective:** Rare disease**Background:** Ischemic stroke can have a tremendously negative impact on the fitness and well-being of a child. Because endovascular interventions may be of benefit in the adult stroke population, many investigators have recently evaluated the safety and benefits of pharmacological and non-pharmacological options in the pediatric stroke population and compared pediatric patients to their adult counterparts. Some of these trials have had promising results, showing the positive effects of endovascular treatment in children with arterial acute ischemic stroke due to large-vessel occlusion (LVO). The 2015 American Heart Association/American Stroke Association guidelines suggest that mechanical thrombectomy with stent retrievers may be a consideration in some patients who are younger than 18 years and have severe LVO, when treatment (groin puncture) is initiated within 6 h of symptom onset. However, the method remains under-studied in this age group.**Case Report:** A 7-year-old girl presented with migraine-like headache, right arm and facial weakness, and expressive aphasia 9.5 h after symptom onset. Her PEDS-NIH stroke scale score was 4. Upon further investigations, she was found to have a left middle cerebral artery cryptogenic stroke with a distal left M1 clot, which was successfully treated with mechanical thrombectomy. Huge improvement was noticed during her subsequent physical examination.**Conclusions:** Endovascular therapy offers an exciting treatment option for the management of pediatric stroke. The extent of safety of mechanical thrombectomy among children who present with large-vessel occlusion over an extended time window remains unknown and warrants further investigations.**MeSH Keywords:** Pediatrics • Stroke • Thrombectomy**Full-text PDF:** <https://www.amjcaserep.com/abstract/index/idArt/926529>


1325



—



3



18



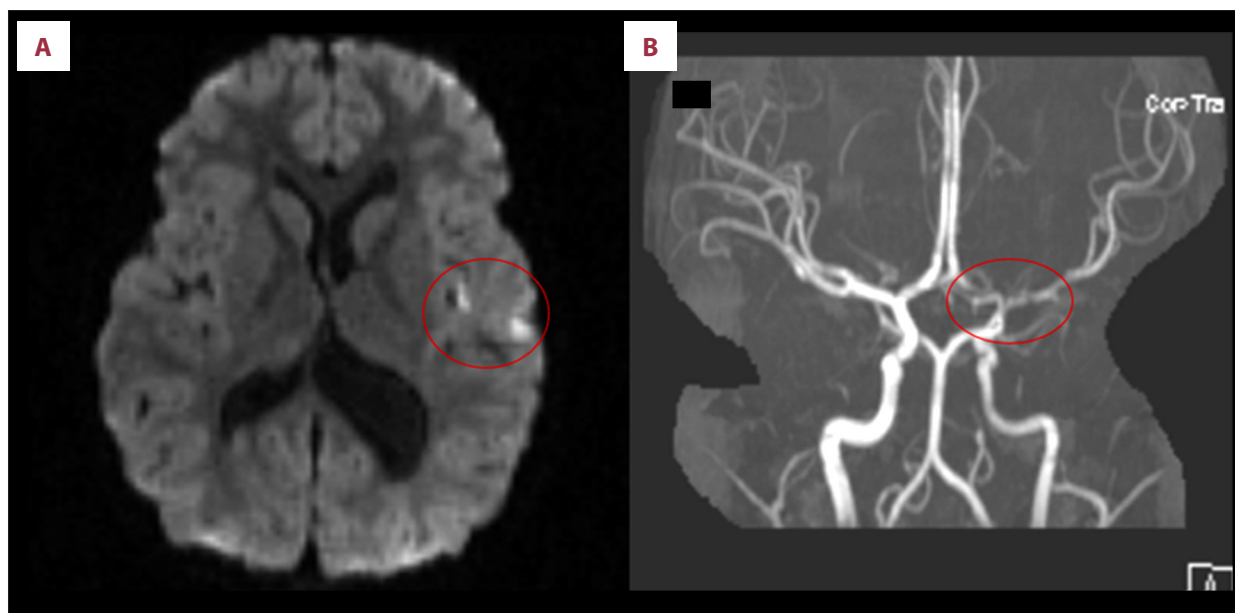
## Background

Acute ischemic stroke (AIS) in children is a rare medical condition. Its diagnosis and treatment can be challenging because of the diverse range of risk factors leading to it and the lack of clear treatment guidelines for this age group. The presentation of ischemic stroke in pediatric patients can vary greatly and differ according to the patient's age. For instance, children present with acute focal neurological deficits in up to 94% of cases [1]. However, they might also present with other manifestations such as altered mental status (28% of cases), headache (22%), fever (35–40%), or seizures (16%) [1]. Mackay et al. confirmed that there are often multiple risk factors of pediatric AIS, which appear to vary according to age and geography [2]. However, the most important risk factors associated with childhood AIS seem to be non-atherosclerotic arteriopathies and cardiac disease, which was identified in almost one-third of patients [2]. Other identified risk factors include previous varicella zoster infection, preceding trauma, recent infection, migraine, and anemia [3]. As in adults, computed tomography (CT) in pediatric patients has low diagnostic accuracy for posterior circulation ischemic stroke (PCIS) diagnosis. Magnetic resonance imaging (MRI) was often necessary to confirm the clinical suspicion of an acute cerebrovascular event, whereas CT could diagnose most anterior circulation ischemic stroke cases [4]. Management of pediatric AIS is still lacking supportive clinical evidence, making the safety and efficacy of acute pharmacological and non-pharmacological interventions of AIS a hot topic of research. The use of thrombolytic therapy in the pediatric population is still controversial, and randomized controlled trials have been unsuccessful in

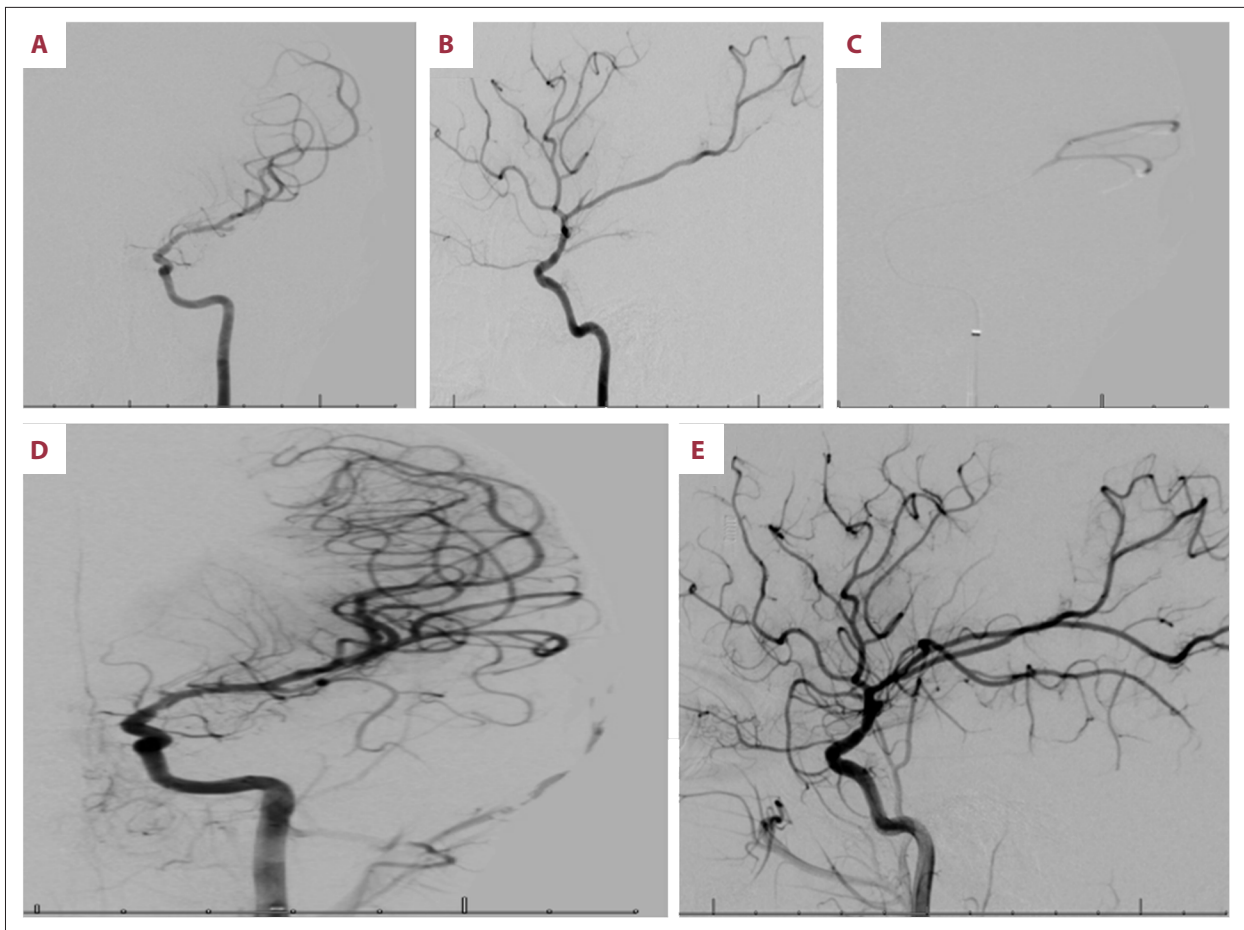
investigating this treatment modality. However, some studies investigating thrombectomy in treating AIS among children revealed promising results, which are comparable to those of studies in the adult population.

## Case Report

A 7-year-old left-handed girl presented with migraine-like headache, right arm weakness, right facial droop, and expressive aphasia that began 9.5 h prior to presentation. Her PEDS-NIH stroke scale score was 4 (1 for smile asymmetry, 1 for right upper extremity drift, 1 for right upper extremity sensory loss, and 1 for mild aphasia). An MRI of the head conducted 50 min after presentation revealed a diffusion-weighted imaging (DWI) hyperintensity in the left frontal operculum. Magnetic resonance angiography (MRA) revealed severe stenosis of the left middle M1 segment and occlusion of the left middle cerebral artery (MCA) inferior M2 branch (Figure 1). The ASPECTS-DWI score was 8. She immediately underwent mechanical thrombectomy with a stent retriever (Figure 2). The pretreatment and posttreatment thrombolysis in cerebral infarction scores were 0 and 2B, respectively, and door-to-groin puncture time was 90 min. The patient's 24-h and discharge PEDS-NIH stroke scale was 1, for mild aphasia only. The subsequent stroke workup was unremarkable and included an echocardiography with bubble study, lipid panel, hemoglobin A1c, lipoprotein A, hypercoagulable workup (cardiolipin antibody IgG and IgM, beta 2-glycoprotein 1 antibody IgG and IgM, lupus anticoagulant, protein S antigen, antithrombin III, factors 2 and 5 mutation analysis, and homocysteine), serum



**Figure 1.** (A) Foci of acute infarct in the left frontal operculum. (B) Poor signal in the M1 segment of the left middle cerebral artery indicating severe stenosis and an acute cutoff of left inferior M2 division indicating occlusion.



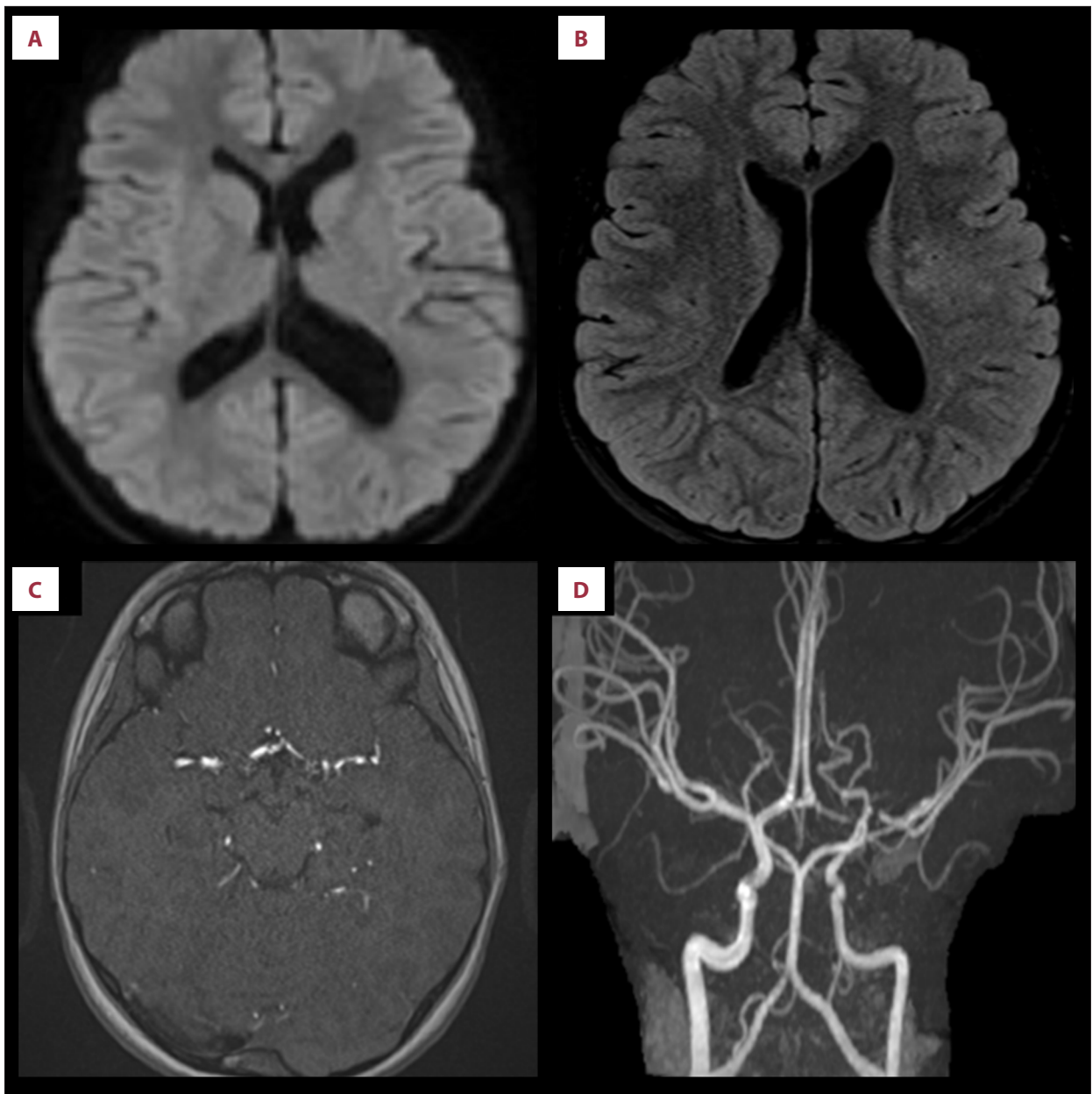
**Figure 2.** (A, B) Left internal carotid artery injection through the diagnostic catheter. There is an acute cutoff of inferior M2 division with corresponding oligemia. (C) The microcatheter injection confirms the position of the microcatheter beyond the occlusion of the vessel. (D, E) Post thrombectomy injection from Sophia intermediate catheter. The occluded inferior division M2 branch is now recanalized with antegrade flow and evidence of focal oligemia in the region of the angular gyrus, which is likely related to a small occluded branch.

inflammatory markers, infectious and metabolic studies (antinuclear antibody, myeloperoxidase antibody IgG, proteinase-3 antibody IgG, SSB, SSA, C-reactive protein, sedimentation rate, HIV antigen and antibody, TSH, vitamin B12, peripheral blood smear, complete metabolic panel and complete blood count), and CSF studies (protein level, cell count, glucose level, Gram stain, bacterial and fungal cultures, herpes simplex virus PCR, varicella zoster virus PCR, varicella zoster virus IgG, Lyme IgG antibody, angiotensin converting enzyme, oligoclonal bands, cytology, and flow cytometry). There was no hemorrhagic transformation apparent on MRI the day after the thrombectomy. The patient was discharged home on 81 mg of baby aspirin once daily. At the follow-up 3 months after discharge, she was back to her pre-morbid neurological baseline and the Pediatric Stroke Outcome Measure score was 0. The patient underwent an MRI of the brain 6 months after discharge, which revealed stable sequelae of prior left MCA distribution infarct with multifocal small old lacunar infarcts. There was no new or acute

intracranial abnormality. Also, the MRA of the head showed stable, short segment M1 stenosis (Figure 3).

## Discussion

Most of the clinical care guidelines for pediatric stroke cases have been extrapolated from adult cases. In adults, time to restoration of blood flow in ischemic stroke is essential for better functional neurological outcomes [5]. Therefore, administration of recombinant tissue-type plasminogen activator (r-tPA) to appropriate patients is currently the mainstay of acute medical aid in ischemic stroke patients within the adult population [6]. However, thrombolytic therapy in pediatric patients is still controversial, and although efforts to study the safety of tPA in patients < 18 years old in randomized controlled trials have been made, they have not identified the medical comorbidities associated with pediatric stroke. The current medical



**Figure 3.** (A) Diffusion-weighted imaging with no new or acute infarcts. (B) Fluid-attenuated inversion recovery showing stable sequelae of prior left middle cerebral artery distribution infarct with multifocal small old lacunar infarcts. (C, D) Stable severe stenosis of the left M1 segment.

views on the utilization of acute thrombolytic therapy depends on assessing the risk-benefit ratio of the treatment in each individual case, balancing between no thrombolysis or considering it if the only contraindication in the case is the patient's age [7,8]. For stroke in adults, thrombectomy is indicated for AIS with LVO in acceptable clinical settings. Many randomized controlled trials showed a high level of safety, improved functional outcomes, and extended time from symptom onset (in the DEFUSE 3 trial, 6–16 h and in the DAWN trial, 6–24 h) when thrombectomy was conducted in an appropriate clinical

context and done in patients with LVO in the anterior circulation within 6 h of symptom onset [9–15].

Many trials were conducted to study treatment options in pediatric stroke cases. Some showed the success of endovascular treatment in children with arterial AIS due to LVO. In the retrospective Save ChildS trial, conducted from 2000 to 2018, researchers found that 87% of the enrolled children (<18 years of age) who underwent endovascular thrombectomy had successful recanalization [16]. The median time from appearance

of first clinical to recanalization therapy was 4 h; however, some cases were treated outside the 6-h window. This results of this trial suggested that the neurologic outcomes of children with AIS were largely positive, promising, and comparable with those noted in adult thrombectomy trials. Bigi et al. studied a cohort of 150 patients with AIS, who all presented with PEDS-NIH score of at least 4 and were aged <16 years [17]. Sixteen patients received pharmacological management with thrombolytics and another 6 patients underwent mechanical thrombectomy. One patient was treated with thrombectomy only. All but 1 patient were diagnosed within a 12-h interval after symptom onset; however, 4 patients were treated more than 6 h after their symptoms appeared, which is similar to our patient. Treatment results at follow-up showed complete recanalization in 4 patients, partial recanalization in 6 patients, and no changes in 4 patients. The authors concluded that recanalization treatment is possible and seems to be safe in severely affected pediatric patients with AIS and complications did not happen more frequently in patients who received recanalization treatment [17].

In a comprehensive review of the literature, Satti et al. described 29 case reports of recanalization in pediatric AIS cases (2008–2015). Time to recanalization treatment ranged from 1.5 to 120 h. Excluding 3 patients with an unknown time to

recanalization treatment and another 3 patients who were treated beyond 24 h, the average time to recanalization treatment was 8.8 h. A total of 75.9% of the patients attained recanalization. Clinical outcomes were reported in 23 patients, with 86.7% of patients achieving a good clinical outcome [18]. The 2015 American Heart Association/American Stroke Association guidelines on this topic declared that endovascular thrombectomy might be clinically of great value in children <18 years of age using adult parameters [6].

## Conclusions

The safety of and clinical improvement from mechanical thrombectomy in children with large-vessel occlusion over an extended time period after symptom onset remains unknown. Although endovascular therapy offers an exciting and promising method in the management of pediatric stroke cases, further research is needed to determine the clinical and technical parameters for the successful use of this treatment in children with LVO.

## Conflict of interest

None.

## References:

1. Tsze D, Valente J: Pediatric stroke: A review. *Emerg Med Int*, 2011; 2011: 734506
2. Mackay M, Wiznitzer M, Benedict S et al: Arterial ischemic stroke risk factors: The International Pediatric Stroke Study. *Ann Neurol*, 2011; 69: 130–40
3. Ganesan V, Prengler M, McShane M et al: Investigation of risk factors in children with arterial ischemic stroke. *Ann Neurol*, 2003; 53(2): 167–73
4. Morotti A, Mazzacane F, Leuci E: Pediatric ischemic stroke. *J Neurol*, 2020; 267(4): 1221–22
5. Lynch JK, Hirtz DG, Deveber G et al: Report of the National Institute of Neurological Disorders and Stroke Workshop on Perinatal and Childhood Stroke. *Pediatrics*. January 2002;109(1): 116-123. doi: 10.1542/peds.109.1.116.
6. Powers W, Rubinstein A, Ackerson T, et al. 2018 Guidelines for the early management of patients with acute ischemic stroke: A guideline for health-care professionals from the American Heart Association/American Stroke Association. *Stroke*, 2018; 49(3): 46–110
7. Roach E, Golomb M, Adams R et al: Management of stroke in infants and children: A scientific statement from the American Heart Association Stroke Council and the Council on Cardiovascular Disease in the Young. *Stroke*, 2008; 39: 2644–91
8. Ferriero D, Fullerton H, Bernard T et al: Management of stroke in neonates and children: A scientific statement from the American Heart Association/American Stroke Association. *Stroke*, 2019; 50: 51–96
9. Berkhemer O, Fransen P, Beumer D et al: A randomized trial of intraarterial treatment for acute ischemic stroke. *N Engl J Med*, 2015; 372(1): 11–20
10. Goyal M, Demchuk A, Menon B et al: Randomized assessment of rapid endovascular treatment of ischemic stroke. *N Engl J Med*, 2015; 372(11): 1019–30
11. Saver J, Goyal M, Bonafe A et al: Stent-retriever thrombectomy after intravenous t-PA vs. t-PA alone in stroke. *N Engl J Med*, 2015; 372(24): 2285–95
12. Campbell B, Mitchell P, Kleinig T et al: Endovascular therapy for ischemic stroke with perfusion-imaging selection. *N Engl J Med*, 2015; 372(11): 1009–18
13. Jovin T, Chamorro A, Cobo E et al: Thrombectomy within 8 hours after symptom onset in ischemic stroke. *N Engl J Med*, 2015; 372: 2296–306
14. Albers G, Lansberg M, Kemp S et al: A multicenter randomized controlled trial of endovascular therapy following imaging evaluation for ischemic stroke (DEFUSE 3). *Int J Stroke*, 2017; 12(8): 896–905
15. Jovin T, Saver J, Ribo M et al: Diffusion-weighted imaging or computerized tomography perfusion assessment with clinical mismatch in the triage of wake up and late presenting strokes undergoing neurointervention with Trevo (DAWN) trial methods. *Int J Stroke*, 2017; 12(6): 614–52
16. Sporns P, Strater R, Minnerup J et al: Feasibility, safety, and outcome of endovascular recanalization in childhood stroke. *JAMA Neurology*, 2019; 77(1): 25
17. Bigi S, Dulcey A, Garalla J et al: Feasibility, safety, and outcome of recanalization treatment in childhood stroke. *Ann Neurol*, 2018; 83(6): 1125–32
18. Satti S, Chen J, Sivapatham T et al: Mechanical thrombectomy for pediatric acute ischemic stroke: review of the literature. *J Neurointerv Surg*, 2017; 9(8): 732–37