

Case Report

Ischemic stroke during the puerperium presenting as a bilateral anterior opercular (Foix-Chavany-Marie) syndrome

Miguel García-Grimshaw, Amado Jiménez-Ruiz, Eduardo Peña-Andrade, Fernando Flores-Silva, Carlos Cantú-Brito, Erwin Chiquete *

Department of Neurology and Psychiatry, Instituto Nacional de Ciencias Médicas y Nutrición Salvador Zubirán, Mexico City, Mexico

ARTICLE INFO

Keywords:

Bilateral anterior opercular syndrome
Embolitic stroke of undetermined source
Foix-Chavany-Marie syndrome
Ischemic stroke
Puerperium

1. Introduction

The bilateral anterior opercular syndrome or Foix-Chavany-Marie syndrome (FCMS) is a rare type of cortico-subcortical supranuclear palsy. Clinically, this disorder presents as bilateral central faciopharyngo-glossomasticatory paralysis with prominent automatic-voluntary dissociation characterized by preserved automatic reactions such as laughing, crying, yawning, smiling, and autonomic reflexes. Usually, it develops secondary to bilateral opercular lesions and, rarely, from unilateral lesions [1,2]. Here, we report the case of a patient who presented with FCMS secondary to bilateral acute ischemic strokes during the postpartum.

2. Case report

A previously healthy 34-year-old right-handed woman presented one month after an uneventful cesarean section with a five-day history of sudden onset dysarthria, dysphagia, sialorrhea, and bilateral hand weakness. There was no recent history of fever, vertigo, headache, visual or sensory disturbances. Her medical history negative for allergies, contraceptive drugs, smoking, substance abuse, or systemic diseases. Family history was also negative for neurological disorders.

At admission, her vital signs were within normal limits. During the physical examination, she was alert and oriented but unable to speak due to severe dysarthria. Both auditory and reading comprehension were intact, being able to communicate with signs and handwriting.

Cranial nerve examination revealed bilateral palsy of the V, VII, IX, X, and XII cranial nerves, with facial diplegia with limited mouth opening, she was unable to swallow despite having a normal gag reflex, unable to protrude or make lateral movements of the tongue, and prominent automatic-voluntary dissociation, characterized by preserved yawning and smiling (Fig. 1). Jaw jerk reflex and trigeminal nerve sensory examination were normal. Motor examination revealed mild symmetrical weakness (MRC 4/5) for the abduction and flexion of the arms with normal strength of the lower limbs and generalized brisk deep tendon reflexes (+++). Finger flexor response and plantar reflexes were normal, and the rest of the neurological examination was unremarkable. These findings were consistent with a clinical diagnosis of an anterior opercular syndrome.

Routine blood workup, including a full blood cell count, serum electrolytes, renal and liver function tests, lipid panel, and serum C-reactive protein, were within normal limits. Serum testing for syphilis, hepatitis C and HIV antibodies were negative. A magnetic resonance imaging (MRI) of the brain showed bilateral round and ill-defined lesions of the anterior white matter (corona radiata) consistent with subacute ischemic strokes without signs of cerebral venous thrombosis on an MRI venography. To determine the stroke mechanism, we performed an electrocardiogram, an agitated saline transthoracic contrast echocardiogram and transcranial Doppler ultrasound, 24 -hs Holter monitoring, and a Doppler ultrasound of the carotid and vertebral arteries, with unremarkable results. To rule-out infectious or inflammatory causes, we performed a lumbar puncture; cerebrospinal fluid (CSF)

* Corresponding author at: Instituto Nacional de Ciencias Médicas y Nutrición Salvador Zubirán, 15 Vasco de Quiroga Mexico City, CDMX, 14050, Mexico.
E-mail address: erwin.chiquetea@incmnsz.mx (E. Chiquete).

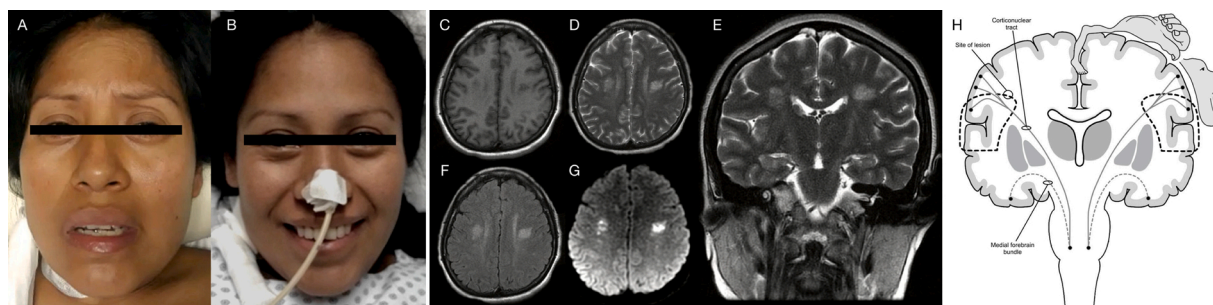


Fig. 1. (A) The photograph shows the patient voluntary facial diplegia and limited mouth opening with (B) preserved automatic smiling. (C) Axial T1-weighted and (D) Axial T2-weighted magnetic resonance imaging (MRI) of the brain shows bilateral opercular lesions of the frontal lobes. (E) Coronal T2-weighted MRI shows a lesion of the left superior temporal operculum and a lesion of the right corona radiata. The lesions were hyperintense on the (F) fluid-attenuated inversion recovery sequence with restricted diffusion on the (G) diffusion-weighted imaging sequence. (H) Illustration exemplifying the site of the lesions (black dash line) and anatomic basis for the Foix-Chavany-Marie syndrome, in which the cortico-nuclear tract (continuous grey line) provides the voluntary muscle control, and alternate pathways mainly the medial forebrain bundle (grey dash line) and dorsal longitudinal fasciculus (not shown) controls the automatic expression movements of the face.

analysis was normal, with no white cells detected, proteins in 25 mg/dL (reference value: 15–45), glucose in 56 mg/dL (reference value: 40–70), CSF/serum glucose ratio of 0.62, with negative Gram and acid-fast bacilli stains. Testing the CSF for herpes simplex viruses 1 and 2, varicella-zoster virus, Epstein-Barr virus, and *Mycobacterium tuberculosis* was also negative, as well as testing for oligoclonal bands in the CSF and serum anti-aquaporin-4 (anti-AQP4) IgG subclass antibodies.

To determine the etiology of an ischemic stroke in a previously healthy young adult, we performed a broad workup, including testing for antiphospholipid syndrome, anti-nuclear, and anti-neutrophil cytoplasmic antibodies; protein C, S, antithrombin III deficiencies, and Leiden Factor V mutation, which were all negative. With an extensive negative workup, we established the diagnosis of an embolic stroke of undetermined source (ESUS) and started her on secondary prevention with aspirin 100 mg/day. Six days after admission, the patient was already able to swallow and speak with mild dysarthria. The facial diplegia and weakness of the upper limbs also improved. We discharged her ten days after admission, and during a twelve-month follow-up, the patient remains asymptomatic without recurrent events.

3. Discussion

First described by Magnus in 1837 and later detailed in 1926 by the French neurologists Charles Foix, Jean Alfred Émile Chavany, and French pediatrician Julien Marie, the anterior opercular syndrome or FCMS is a rare type of cortico-subcortical supranuclear palsy presenting with acute-onset bilateral paresis of the facial, pharyngeal, lingual, and masticatory muscles (innervated by cranial nerves V, VII, IX, X, and XII). Clinically this disorder presents with bilateral central facio-pharyngo-glosso-masticatory paralysis. The hallmark of this syndrome is the prominent automatic-voluntary dissociation, with preserved automatic reactions such as laughing, crying, yawning, smiling, and autonomic reflexes. Some patients may present with speech production disturbances (hypophonia, dysarthria, or anarthria), dysphagia, facial diplegia, and in some cases, the mouth may be held half-open with an inability to protrude the tongue [1–3].

Clinical diagnosis of this syndrome requires an understanding of its complex neuroanatomical basis, in which the primary motor cortex provides control of the face, tongue, and pharynx's voluntary muscle control through the cortico-nuclear tracts and spontaneous and emotional movements of the facial muscles are controlled by neural pathways arising from the amygdala and lateral hypothalamus, projected to the brainstem via the medial forebrain bundle and dorsal longitudinal fasciculus [3,4].

This syndrome usually develops with bilateral white matter lesions

affecting the anterior opercular region; however, it can also occur secondary to unilateral lesions [1,5]. The most common cause is ischemic stroke, but other etiologies, such as infectious, demyelinating, neurodegenerative, traumatic, osmotic, and neoplastic, have been described, and the prognosis for these patients depends on the underlying etiology [5–8]. Differential diagnosis for such clinical presentation includes, catatonia, akinetic mutism, oro-buccal apraxia, Broca's aphasia, bulbar palsy secondary to myasthenia gravis, the pharyngeal-cervical-brachial variant of Guillain-Barré syndrome, amyotrophic lateral sclerosis, Brown-Vialetto-Van Laere syndrome, lacunar state of Pierre Marie, and multiple brainstem strokes [2].

After an extensive workup, we diagnosed an ESUS as the stroke mechanism in our patient. This construct represents a distinct phenotype among cryptogenic strokes with a high likelihood of embolic sources not found on the initial approach. To this day, there is no defined treatment for ESUS other than monotherapy with aspirin or clopidogrel.

4. Conclusion

FCMS is a rare diagnosis that clinicians should keep in mind in patients presenting with bilateral facio-pharyngo-glosso-masticatory paralysis and automatic-voluntary dissociation. The present case represented a unique challenge due to the co-occurrence of FCMS and ESUS in a young patient during the postpartum. Evidence-based treatment for these patients is lacking, and more studies are needed to guide appropriate workup and therapy in this population.

Informed consent

Informed consent for publication was obtained from the patient.

Source of funding

None.

Declaration of Competing Interest

The authors report no declarations of interest.

Acknowledgement

None.

References

- [1] M. Weller, Anterior opercular cortex lesions cause dissociated lower cranial nerve palsies and anarthria but no aphasia: Foix-Chavany-Marie syndrome and “automatic voluntary dissociation” revisited, *J. Neurol.* 240 (1993) 199–208, <https://doi.org/10.1007/BF00818705>.
- [2] J. López-Esparza, C.D. Castillo, P. Verduzco, M. Santos, F. Flores, E. Chiquete, et al., Síndrome Foix-Chavany-Marie vascular: abordaje del constructo de ESUS, *Neurol. Argent* 10 (2018) 35–39, <https://doi.org/10.1016/j.neuarg.2016.11.005>.
- [3] A.Ç Turgut, R.S. Tubbs, M. Turgut, French neurologists Charles Foix and Jean Alfred Émile Chavany and French pediatrician Julien Marie and the Foix-Chavany-Marie syndrome, *Childs Nerv. Syst.* 36 (2020) 2597–2598, <https://doi.org/10.1007/s00381-019-04290-1>.
- [4] T. Theys, S. Van Cauter, K.H. Kho, A.-C. Vijverman, R.R. Peeters, S. Sunaert, et al., Neural correlates of recovery from Foix–Chavany–Marie syndrome, *J. Neurol.* 260 (2013) 415–420, <https://doi.org/10.1007/s00415-012-6641-0>.
- [5] R. Demaerel, S. Klein, F. Van Calenbergh, Syndrome of the Trephined presenting as Foix-Chavany-Marie syndrome, *Clin. Neurol. Neurosurg.* 196 (2020), 106058, <https://doi.org/10.1016/j.clineuro.2020.106058>.
- [6] H. Onder, S. Evren Erdener, E. Saka, Progressive anterior operculum syndrome due to frontotemporal lobar degeneration, *Neurol. Sci.* 39 (2018) 385–387, <https://doi.org/10.1007/s10072-017-3128-x>.
- [7] N. Nitta, A. Shiino, Y. Sakaue, K. Nozaki, Foix-Chavany-Marie syndrome after unilateral anterior opercular contusion: a case report, *Clin. Neurol. Neurosurg.* 115 (2013) 1539–1541, <https://doi.org/10.1016/j.clineuro.2012.12.036>.
- [8] S. Pandey, V.V. Holla, I. Rizvi, R. Shukla, Reversible opercular syndrome secondary to osmotic demyelination, *Clin. Neurol. Neurosurg.* 155 (2017) 12–13, <https://doi.org/10.1016/j.clineuro.2017.02.001>.