

## Staphylococcus aureus meningitis complicated with intracranial hemorrhage and cerebral infarction: a case report

Yu Jia, Wei Wang, Xiangbo Wang, Lidong Jiao & Yuping Wang

To cite this article: Yu Jia, Wei Wang, Xiangbo Wang, Lidong Jiao & Yuping Wang (2021): Staphylococcus aureus meningitis complicated with intracranial hemorrhage and cerebral infarction: a case report, International Journal of Neuroscience, DOI: [10.1080/00207454.2021.1879064](https://doi.org/10.1080/00207454.2021.1879064)

To link to this article: <https://doi.org/10.1080/00207454.2021.1879064>



Published online: 31 Jan 2021.



Submit your article to this journal [↗](#)



Article views: 17

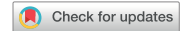

View related articles [↗](#)



View Crossmark data [↗](#)

CASE REPORT



# Staphylococcus aureus meningitis complicated with intracranial hemorrhage and cerebral infarction: a case report

Yu Jia<sup>a</sup>, Wei Wang<sup>b</sup>, Xiangbo Wang<sup>a</sup>, Lidong Jiao<sup>a</sup> and Yuping Wang<sup>a</sup>

<sup>a</sup>Department of Neurology, Xuanwu Hospital, Capital Medical University, Beijing, China; <sup>b</sup>Department of Neurology, Caoxian People's Hospital, Shandong, China

## ABSTRACT

**Purpose:** The case with staphylococcus aureus meningitis accompanied by intracranial hemorrhage and cerebral infarction is very rare and cerebrovascular complications are often associated with poor outcome.

**Materials and methods:** We describe the clinical characteristics and laboratory data of a patient with meningitis accompanied by cerebrovascular complications.

**Results:** The patient, a young male, was admitted to hospital with 3 weeks of fever, 10 days of slow reaction and 2 days of left limb strength decline. Neurological examination showed cognitive dysfunction, left central hemiplegia and meningeal irritation sign. Brain Imaging examination revealed intracranial hemorrhage and multiple cerebral infarction. The elevated leucocyte and protein, as well as low glucose of cerebrospinal fluid was observed. Cerebrospinal fluid and foot blister culture both suggested staphylococcus aureus infection. With the treatment of meropenem and glucocorticoid, the condition of our patient was improved.

**Conclusions:** Detection of pathogenic bacteria is the gold standard of diagnosis, and timely diagnosis and treatment for pathogens are the keys to a good prognosis for patients.

## ARTICLE HISTORY

Received 21 June 2020

Accepted 27 December 2020

## KEYWORDS

*Staphylococcus aureus*; meningitis; secondary vasculitis; intracranial hemorrhage; cerebral infarction

## 1. Introduction

Staphylococcus aureus meningitis accounts for approximately 2% to 10% of bacterial meningitis [1]. The cases with Staphylococcus aureus meningitis accompanied by stroke are very rare, and cerebrovascular complications are often associated with poor outcome. In this case, we describe a male who presented with intracranial hemorrhage and cerebral infarction due to staphylococcus aureus meningitis.

## 2. Case presentation

### 2.1. Patient

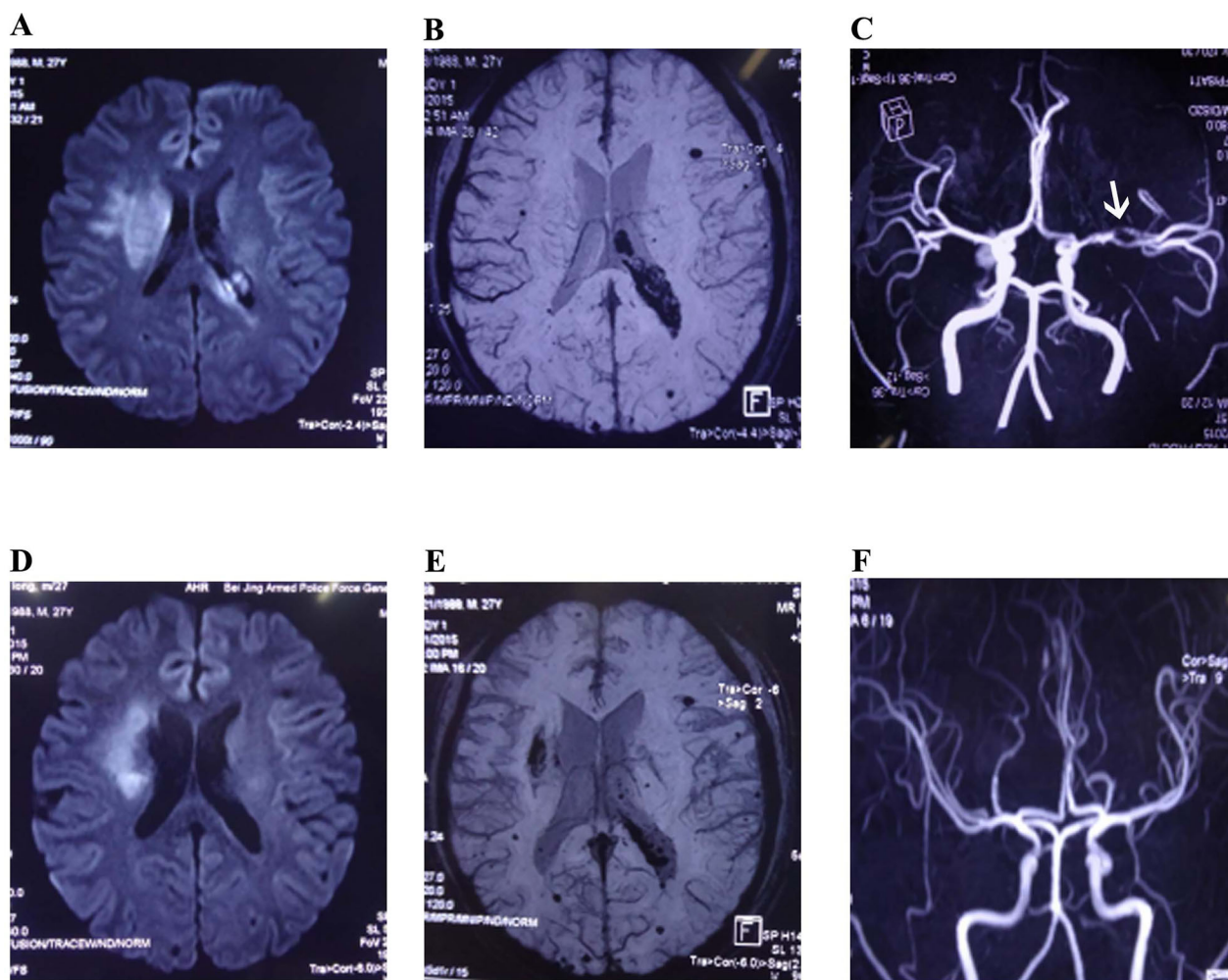
The patient, 27-year-old male, who was admitted to Xuanwu hospital, capital medical university. His chief complaint was slow reaction, psychological and behavioral impairment of 10 days duration, left limb strength decline for 2 days duration. He believed that he had fever and severe headache for the past 3 weeks. There had been blood spots in the extremities and blood blister on the ankle. In the early stage of the disease, serum white blood cell (WBC):  $12.66 \times 10^9/L$ , blood

platelets (PLT):  $43 \times 10^9/L$ , erythrocyte sedimentation rate (ESR): 53 mm/h. High dose moxifloxacin was used and the body temperature decreased to normal out of the hospital. He denied recent hospitalization or other known contact with the health-care system.

After admission, CNS examination showed cognitive dysfunction, gaze palsy to left, left central facial paralysis, left upper limb muscle strength level 0, left lower limb muscle strength level 3, distal muscle strength level 2, positive left Babinski reflex, neck stiffness and positive Kernig sign. Lumbar puncture performed and analysis of the Cerebrospinal fluid (CSF) revealed colorless and transparent fluid, pressure was 220 mmH<sub>2</sub>O, WBC count  $57 \times 10^6/L$  (90% polymorphs), protein level 5.4 g/L, glucose level 2.18 mmol/L.

### 2.2. Findings on imaging examination

Brain computed tomography (CT) scan showed hemorrhage at left posterior angle of lateral ventricle. Brain magnetic resonance imaging (MRI) revealed abnormal linear enhancement of meninges, hemorrhagic foci on left posterior angle of lateral ventricle, multiple



**Figure 1.** Brain MRI and MRA during hospitalization and on one month after discharge. (A) Diffusion weighted imaging (DWI) sequence: High signal image located on right basal ganglia and temporal lobe was observed. (B) Susceptibility weighted imaging (SWI) sequence: Low signal image was on left posterior angle of lateral ventricle. (C) Brain MRA: Moderate stenosis of the right middle cerebral artery (white arrow). (D) DWI sequence: the right basal ganglia infarction was in convalescence. (E) The hemorrhage nudi of left posterior angle of lateral ventricle were absorbed. (F) Brain MRA: The stenosis of right middle cerebral artery returned to normal.

microhemorrhagic lesions on bilateral cerebral hemispheres, left thalamus and cerebellum, and there were hyper-acute infarction foci located on right basal ganglia (Figure 1(A,B)). Moreover, severe stenosis of the right middle cerebral artery was observed in brain MRA (Figure 1(C)).

### 2.3. Pathogen detection and treatment

During the hospitalization, the patient developed high fever (up to 40.1 °C) and his consciousness decreased. The culture of blood, fluid in ankle blister as well as CSF were done. All of the cultures showed growth of *Staphylococcus aureus*, and then this was confirmed using standard tests like meropenem. Based on these findings, meropenem was used as an anti-infective treatment, mannitol was used to reduce intracranial

pressure and Dexamethasone was applied to reduce the inflammatory response of blood vessels. The patient's temperature gradually decreased to normal and his consciousness improved.

### 2.4. Outcome

On the 20th hospital day, the patient accepted examination of blood routine, blood culture and lumbar puncture. Blood routine was normal and blood culture yielded no growth. The CSF pressure was 100 mmH<sub>2</sub>O, WBC count  $5 \times 10^6$ /L, protein level 4.5 g/L, glucose level 2.77 mmol/L. When discharged, the patient had clear consciousness, no gaze in eyes, left upper limb proximal muscle strength level 4, distal muscle strength level 4- level, left lower limb proximal muscle strength level 5, distal muscle strength level 5- level,

and meningeal irritation sign was negative. On the 1 month after discharge, brain MRI examination showed that the hemorrhage nuclei were absorbed, and the right basal ganglia infarction was in convalescence (Figure 1(D,E)). MRA examination revealed that the stenosis of right middle cerebral artery returned to normal (Figure 1(F)).

### 3. Discussion

The patient was diagnosed with *Staphylococcus aureus* meningitis accompanied by intracranial hemorrhage and cerebral infarction. According to the pathogen detection, we chose the sensitive antibiotic drugs based on the drug sensitivity tests to increase the clinical curative effects. Moreover, glucocorticoid was used to lighten vascular inflammatory reaction. The patient symptoms were significantly relieved.

Stroke is one of the serious complications of bacterial meningitis. At present, the pathogenesis of cerebrovascular complications secondary to meningitis is still unclear. Previous studies have found severe inflammatory responses in intracranial blood vessels in patients with bacterial meningitis. After infection by pathogenic bacteria, inflammatory reactions are activated, and inflammatory cells invade the blood vessel wall, leading to thickening of the intima of the blood vessel, resulting in vessel stenosis, disturbed hemodynamic, and the occurrence of stroke [1]. However, some studies suggested that intracranial vessels of patient didn't show changes in inflammation cell infiltration, suggesting that vasospasm caused by inflammatory stimulation and diffuse intracerebral hypercoagulability may also be the important mechanism for bacterial meningitis with stroke [2].

Cerebrovascular complications usually occur within 2 weeks of the onset of bacterial meningitis. The occurrence of cerebrovascular complications will seriously affect the prognosis and even significantly increase the mortality of patients. Schut et al. summarized the risk factors for bacterial meningitis with acute stroke, they found the patient with poor consciousness, high ESR (mean 51 mm/h), as well as lower WBC count (mean  $< 1000 \times 10^6/L$ ) in first CSF were associated with development of cerebrovascular complications [3]. In this case, the application of a variety of antibiotics in the early stage had a great impact on white blood cell count of the first cerebrospinal fluid. In addition, the patient was in a poor state of consciousness after the onset of the disease, and ESR was 53 mm/h, which all belong to the high risk factor of cerebrovascular complications.

At present, there is no consensus on the treatment of cerebrovascular complications with bacterial meningitis, and some views suggested that the sensitive antibiotics should be applied to the patient and glucocorticoid should also be used in the early stage of the disease [4]. However, van de Beek et al. conducted a meta-analysis on the efficacy of glucocorticoid in patients with acute stroke secondary to meningitis, and found that the application of glucocorticoid had no significant effect on the improvement of mortality and the recovery of impaired nerve function in such patients [5]. In our case, glucocorticoids were effective in reducing vascular inflammation and improving the prognosis of patients. Henceforth, randomized controlled trials (RCT) should be performed to identify the definite effect of the application of glucocorticoids.

### 4. Conclusion

The clinical case with *Staphylococcus aureus* meningitis accompanied by intracranial hemorrhage and cerebral infarction are rare. Detection of pathogenic bacteria is the gold standard of diagnosis. Timely diagnosis and treatment for pathogens are the keys to a good prognosis. The efficacy of glucocorticoids still needs to be validated in the large number of clinical trials.

### Author contributions

Y. Jia and W. Wang were the major contributors in writing the manuscript. X. Wang and Y. Wang contributed to the diagnosis and treatment of the patient. L. Jiao contributed to the analysis of genetic examination. Y. Wang and L. Jiao contributed to checking the manuscript. All authors read and approved the final manuscript.

### Disclosure statement

No potential conflict of interest was reported by the author(s).

### Ethics statement

All procedures were approved by the ethics committee of Xuanwu Hospital. Written informed consent was obtained from the patient for publication of this Case report and any accompanying images.

### Funding

This work was supported by National Natural Science Foundation of China Grant [No. 81801283], National Natural Science Foundation of China Grant [No. 81771398], Beijing Key Clinical Speciality Excellence Project and National

Support Provincial Major Disease Medical Services and Social Capability Enhancement Project.

### Data availability statement

The data that support the findings of this study are available from the corresponding author, LD Jiao, upon reasonable request.

### References

- [1] Pfister HW, Feiden W, Einhäupl KM. Spectrum of complications during bacterial meningitis in adults. Results of a prospective clinical study. *Arch Neurol.* 1993;50(6):575–581.

- [2] Vergouwen MD, Schut ES, Troost D, et al. Diffuse cerebral intravascular coagulation and cerebral infarction in pneumococcal meningitis. *Neurocrit Care.* 2010;13(2):217–227.
- [3] Schut ES, Lucas MJ, Brouwer MC, et al. Cerebral infarction in adults with bacterial meningitis. *Neurocrit Care.* 2012;16(3):421–427.
- [4] De Gans J, Van DBD. Dexamethasone in adults with bacterial meningitis. *N Engl J Med.* 2002;347(20):1549–1556.
- [5] Van DBD, Farrar JJ, De GJ, et al. Adjunctive dexamethasone in bacterial meningitis: a meta-analysis of individual patient data. *Lancet Neurol.* 2010; 9(3):254–263.