

A Less Frequent Etiology of Limb Shaking Syndrome: A Severe Middle Cerebral Artery Stenosis

Mikel Vicente-Pascual, Gerard Mauri-Capdevila, and Francisco Purroy

Background: Limb Shaking Syndrome (LSS) is usually associated with internal carotid occlusion. There are few reported-cases in context of middle cerebral artery stenosis. **Methods:** We presented LSS in a patient with middle cerebral artery stenosis disease. **Results:** The patient was a 62-year-old man, smoker, with high blood pressure who suffered left hemifacial and limbs myoclonus. He was initially diagnosed with focal seizures and he started antiepileptic treatment. However, he repeated the episodes. The electroencephalogram showed no abnormalities, and a vascular study with ultrasounds and angio-MRI evidenced severe middle cerebral stenosis. Finally, a diagnosis of Limb Shaking Syndrome was established and he started antiplatelet and high dose lipid-lowering treatment. **Conclusion:** Not all abnormal movements are due to epileptic seizures. When we evaluate a patient with vascular risk factors it is important to perform a complete vascular study to discard not only critical carotid stenosis but also intracranial disease.

Key Words: Limb Shaking Syndrome—Focal seizures—Transient ischemic attack—Intracranial stenosis

© 2021 Elsevier Inc. All rights reserved.

Introduction

Patients who suffer transient ischemic attack (TIA) are characterized by presenting negative phenomena symptoms, such as loss of muscle power, reduced sensation, speech impairment or loss of vision. Positive phenomena symptoms, such as involuntary movements are more frequently related to non cerebrovascular disease, like motor seizures. The Limb Shaking Syndrome (LSS) is characterized by a focal myoclonic movements of the extremities. Due to their clinical presentation, they could be confused with focal epileptic seizures.¹ The clinical manifestations are produced by cerebral hypoperfusion in the context of an internal carotid artery occlusion.^{2–5} Recently, two cases of the syndrome have been reported in brachiocephalic arterial occlusive disease.^{6,7} There are few articles which describe the circle of Willis as the one of the causes of LSS.⁸

Case report

A 62-year-old man suffered a left hemifacial and limbs myoclonus event. These episodes occurred twice a day, without being associated with specific posture or activity, and lasted around 2–3 min. The brain CT performed in the emergency department showed no lesions. He was initially diagnosed with focal seizures and he started antiepileptic treatment. However, even he repeated episodes, the posterior electroencephalogram showed no epileptiform changes, but due to he had different vascular risk factors such as smoking and hypertension a LSS was suspected. Therefore, a sonography study was performed, in which a turbulent flow with symptomatic focal increase in velocity in the right middle cerebral artery, and asymptomatic focal increase velocity in the right posterior cerebral artery were objectified (Fig. 1). In addition, a brain MRI ruled out intraparenchymal lesions, and the MRI angiogram confirmed severe intracranial stenosis (Fig. 2). No recurrence was observed one week after starting antiplatelet and high dose lipid-lowering treatment although antiepileptic treatment was withdrawn.

From the Stroke Unit, Neurology Department. Hospital Universitari Arnau de Vilanova, Av. Alcalde Rovira Roure, 80, 25198 Lleida, Spain.

Received October 16, 2020; revision received January 15, 2021; accepted January 16, 2021.

Corresponding author. E-mail: mvpascual.1@gmail.com.

1052-3057/\$ - see front matter

© 2021 Elsevier Inc. All rights reserved.

<https://doi.org/10.1016/j.jstrokecerebrovasdis.2021.105629>

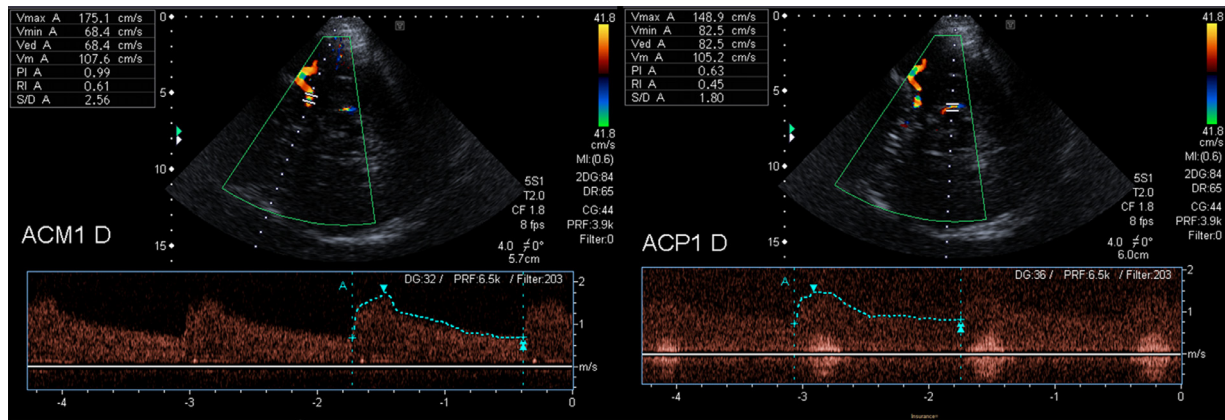


Fig. 1. Sonography study shows turbulent flow with focal increase in velocity in right middle cerebral artery (left image) and in posterior cerebral artery (right image).

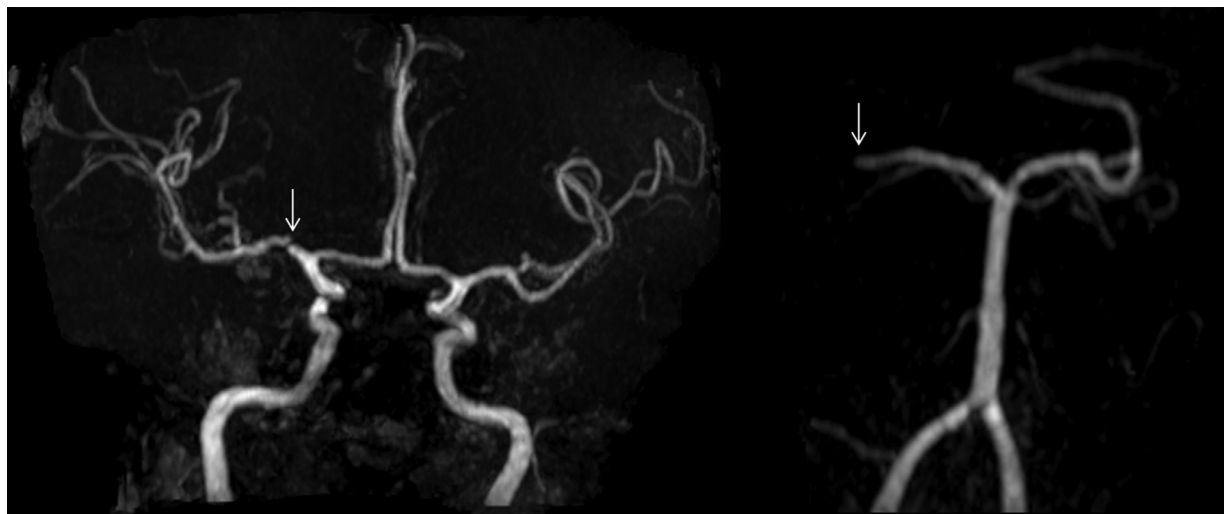


Fig. 2. MRI angiogram evidenced severe stenosis in right middle (arrow in left image) and posterior cerebral artery (arrow in right image).

Discussion

LSS is considered a transient ischemic attack. It is associated with a severe arterial stenosis or occlusion and it can be explained by a hypoperfusion theory, in which the orthostatism and the arterial stenosis lead to a decrease cerebral flow. The electroencephalographic studies show no epileptiform activity related to the movements and no response to antiepileptic drugs is observed. Recently two cases have been published in the context of brachiocephalic arterial occlusive disease.^{6,7} LSS is explained by a hypoperfusion mechanism, but we did not performed a perfusion study. However our case could be an example of LSS induced by circle of Willis artery stenosis. To date, just only one previous case had been published related to middle cerebral artery stenosis.⁸ In conclusion, not all abnormal movements are due to epileptic seizures. In patients with vascular risk factors it is important to perform vascular studies to guide the correct diagnosis and treatment.

Disclosure

The authors report no disclosures relevant to the manuscript.

Reference

1. Ali Saad, Alam Khan Muhib, Bhojo Khealani. Limb-shaking transient ischemic attacks: case report and review of literature. *BMC Neurology* 2006;6:5.
2. Niehaus L, Neuhauser H, Meyer BU. TIAs of hemodynamic origin mimicking simple partial motor seizures. *Nervenarzt* 1998;69:901-904.
3. Baquis GD, Pessin MS, Scott RM. Limb shaking—a carotid TIA. *Stroke* 1985;16:444-448.
4. Yanagihara T, Piepgras DG, Klass DW. Repetitive involuntary movement associated with episodic cerebral ischaemia. *Ann Neurol* 1985;18:244-250.
5. Baumgartner RW, Baumgartner I. Vasomotor reactivity is exhausted in transient ischaemic attacks with limb shaking. *J Neurol Neurosurg Psychiatry* 1998;65:561-564.
6. Goldstein ED, Cannistraro R, English S, Vazquez Do Campo R, Eidelman B. Brachiocephalic arterial

- occlusive disease presenting as limb-shaking transient ischemic attacks. *J Stroke Cerebrovasc Dis*. 2018;27:e34-e35.
7. Abbas A, Nader K, Tiwari A, Viruthagiri A, Littleton E. Image of the month: Brachiocephalic arterial occlusive limb-shaking transient ischaemic attacks. *Clin Med (Lond)*. 2018;18:435-436.
 8. Jiang WJ, Gao F, Du B, Srivastava T, Wang YJ. Limb-shaking transient ischemic attack induced by middle cerebral artery stenosis. *Cerebrovasc Dis* 2006;21:421-422.